

Ultrasound biomicroscopy and secondary epithelial downgrowth cysts of anterior chamber

Biomicroscopia ultra-sônica e cistos irianos secundários à epitelização da câmara anterior

Consuelo B. D. Adan ⁽¹⁾
Martha M. M. Chojniak ⁽²⁾
Norma Allemann ⁽³⁾

SUMMARY

Purpose: To determine clinical and ultrasound correlation of secondary implantation iris and anterior chamber cysts, reported after trauma or intraocular surgeries.

Patients and Methods: Retrospective study of ultrasonographic biomicroscopy examinations (UBM Model 840 - Humphrey Instruments, USA, equipped with a 50 MHz transducer, utilizing immersion technique), performed from August 1994 to July 1997 at the Ocular Ultrasound Section, UNIFESP-EPM.

Results: In a total of 1,669 UBM examinations, 8 cases of secondary epithelial implantation cysts were found, among them 3 after trauma (2 presenting as a white lesion, whose anatomopathological sections showed concentric lamellae of keratin; another with penetrating ocular trauma presenting a lesion with hypodense content) and 5 cases after intraocular surgery (post-extracapsular extraction, 3 cases; post-penetrating corneal graft, 2 cases). On UBM, secondary implantation cysts were identified as unilateral lesions, with hypodense content (with particles in suspension, or epithelial cells) or disposed in concentric hyperreflective lamellae (keratin). In all the cases of hypodense content (6), delamination of iris stroma was observed, an information unavailable by other methods. Utilizing UBM examination, postoperative evaluation was performed in 2 cases (1 submitted to surgical removal, another to laser cystotomy) or serial examination if clinical observation was decided.

Conclusion: UBM examination was able to differentiate the type of anterior chamber epithelialization (cystic, solid and sheet-like forms), to detect associated lesions indicating the most appropriate treatment, its results when performed, and its follow-up.

Keywords: Ultrasound biomicroscopy; Secondary iris cyst; Epithelial downgrowth of anterior chamber.

INTRODUCTION

Pathologic epithelialization of the anterior segment may occur weeks, months or years after perforating trauma or intraocular surgery, mainly cataract extraction. Epithelialization occurs in the form of cystic or sheet-like downgrowth ^{1,2}.

Cysts may stem from skin implantation, connective epithelium ³ or cells deriving from hair follicles, usually due to the presence of cilia after perforations ^{4,5}, or after ophthalmic surgeries. Usually they appear on the iris

Trabalho realizado no Setor de Ultra-som do Departamento de Oftalmologia da Universidade Federal de São Paulo-Escola Paulista de Medicina (UNIFESP-EPM) e apresentado no XXIX Congresso Brasileiro de Oftalmologia, 3-6 de setembro de 1997, Goiânia.

⁽¹⁾ Mestre em Oftalmologia, Colaboradora do Setor de Doenças Externas Oculares e Córnea e Estagiária do Setor de Ultra-sonografia Ocular do Departamento de Oftalmologia da UNIFESP-EPM.

⁽²⁾ Pós-Graduada e Colaboradora dos Setores de Ultra-sonografia Ocular e Tumores do Departamento de Oftalmologia da UNIFESP-EPM.

⁽³⁾ Chefe do Setor de Ultra-som, Colaboradora do Serviço de Cirurgia Refrativa e Pós-Graduada (doutorado) do Departamento de Oftalmologia da UNIFESP-EPM.

Endereço para correspondência: Dra. Consuelo B. D. Adan / Dra. Norma Allemann. Setor de Ultra-sonografia Ocular. Departamento de Oftalmologia, UNIFESP-EPM. Rua Botucatu, 822. São Paulo (SP) Brasil CEP04023-062. Fax: 55-11-573-4002. e-mail: norma.alleman@pobox.com

and do not require excision, unless they cause permanent inflammation, uncontrollable glaucoma, endothelial decompensation or vision decrease.

Incidence of all forms of anterior chamber epithelialization ranges from 0.11% (in 8,062 eyes submitted to extraction ⁶) to 16% (in enucleated eyes, previously submitted to cataract surgery ⁷). This incidence is decreasing because of advances in surgical techniques ². At present, anterior chamber epithelialization is considered a rare pathology but it still is of interest to researchers, mainly due to its controversial management.

Diagnosis is usually established by biomicroscopy, immersion ultrasound or anatomopathological examination - the latter after surgical resection which is not performed in all cases. Ultrasound biomicroscopy (UBM), a method utilizing high frequency ultrasound (50 MHz) and high resolution (approximately 20 µm), but little penetration (approximately 5 mm) emerged as a propedeutic method for the examination of the anterior segment of the eyeball and its use has been described in different pathologies ^{8,9}.

PURPOSE

The purpose is to present and describe the findings of ultrasound biomicroscopy (UBM) in eyes which showed epithelial invasion of the anterior chamber with presence of iris cysts.

PATIENTS AND METHODS

A retrospective study was performed through survey of data from the ultrasound biomicroscopy files of the Ultrasound Sector of the Department of Ophthalmology, encompassing the period from August 10, 1994 to July 31, 1997, that is, 35 months.

Examinations were performed using the Ultrasound Biomicroscope® (UBM Model 840, Humphrey Instruments, USA) with an approximately 50 MHz frequency transducer, under local anesthesia. After instillation of a drop of tetracycline plus phenylephrine eyedrops (Anesthetic Oculum®, Allergan-Frumtost São Paulo), a small cube made of transparent material was placed between the eyelids, with the patient in dorsal decubitus, and filled with a viscoelastic substance (2% methylcellulose solution®, Ophthalmo, São Paulo) according to the immersion technique described by Pavlin ⁹. The images were recorded and measurements and impressions could be performed afterwards with subsequent description.

RESULTS

In the studied period 1,669 UBM examinations were performed, with eight cases of anterior chamber cysts after its epithelial invasion. Four patients were males and four, females. Aged ranged from 8 to 77 years.

The cysts were unilateral. In four patients the right eye was

Table 1. Summary of the cases with clinical and ultrasound biomicroscopy (UBM) aspects of secondary epithelial downgrowth iris cysts of anterior chamber

Clinical case	Age (years)	Cause	Clinical aspect	Description of ultrasound biomicroscopy (UBM) of iris cystic lesions
1	8	Post-trauma	1. Epithelial <i>pearl</i> cyst RE; 2. Flat anterior chamber at 11 h;	<i>Multilamellar</i> content with arrangement of concentric fibers with variable reflectiveness, and measures of: B = 5.0 mm x A = 3.0 mm;
2	67	Post-PCT	1. <i>Translucent</i> epithelial cyst RE; 2. Flat anterior chamber at 6 h;	Thick wall and <i>hypodense content</i> , occupying region at 6 h in AC; > 5.5 mm;
3	16	Post-trauma	1. <i>Translucent</i> epithelial cyst LE;	Thick and hyperreflective wall, with <i>hypodense content</i> and particles; in suspension
4	23	Post-PCT	1. <i>Translucid</i> epithelial cyst LE;	Thick and hyperreflective wall, with <i>hypodense content</i> and particles; in suspension, connected to the interface of the donor-receptor button, present at 3 to 6 h; measure A = 2.55 mm.
5	54	post-trauma	1. <i>Translucent</i> epithelial cyst RE; 2. Ruptured lens; 3. Corneal edema;	Thin hyperreflective wall, with <i>homogenous content</i> , denser close to the anterior lens face (suspicion of cortical mass), present at 10 to 2 h;
6	68	Post- ECE	1. <i>Translucent</i> epithelial cyst RE;	Thick hyperreflective wall, with <i>hypodense content</i> , occupying region at 9 to 12 h;
7	19	Post-ECE	1. Epithelial <i>pearl</i> cyst LE;	<i>Multilamellar content</i> , and concentric fiber arrangement, of variable reflectiveness; measure A = 3.55 mm of meridians at 5 to 8 h; corneal leukoma at 6 h (previous perforating trauma)
8	77	Post-ECE	1. <i>Translucent</i> epithelial cyst	Thick hyperreflective wall, with <i>hypodense content</i> , occupying region at 11 to 3 h; measure A = 3.64 mm

RE = right eye; LE = left eye; PCT = penetrating corneal transplant; ECE = extracapsular extraction; A = measure of height of lesion; B = measure of lesion base; h = affected hour meridian; AC = anterior chamber.

affected and in four the left eye. All patients presented a history of previous surgical trauma, either alone or associated with previous penetrating trauma.

As shown in Table 1, the cases were classified according to cause of lesion, clinical aspect (slit lamp biomicroscopy) and characteristics of the lesions on UBM.

Clinical case 1 patient was submitted to surgical cyst excision associated with sectorial iridectomy. Anatomopathological examination of the specimen showed, on macroscopy, a whitish cystic structure corresponding to a pearl cyst. And,

on microscopy, the surface of the cystic lesion consisted of stratified squamous epithelium with little keratinization, containing in the lumen desquamative epithelial cells in several stages of degeneration, with keratin lamellae. Anatomopathological diagnosis was intraepithelial inclusion cyst.

Clinical case 4 patient, with a diagnosis of secondary iris cysts after penetrating corneal graft (Table 1), had a history of previous photoablation with YAG laser and relapse after 6 months. At the time of examination, the complaint was ocular hyperemia and foreign body sensation, indicating inflammatory activity. The performed procedure was laser cystotomy (Nd:YAG laser 20 pulses, 4 mJ, causing a 3 mm defect on the cyst wall through the central part of the cornea) with subsequent photocoagulation using an argon laser (200 mW strength, 100 μ m sight, 0.1 s duration, 10 pulses) in order to induce retraction of the cyst. Immediately after the treatment, a UBM examination was performed revealing reduction in the dimensions (height = 1.95 mm) with retraction of the wall and identification of the opening made at cystotomy (Fig. 2B). After 6 months, presenting the same complaints, relapse was observed on ophthalmological examination and a new laser treatment was indicated and carried out: cystotomy (Nd:Yag laser, 40 pulses, 4 mJ, causing a circular defect with a diameter of approximately 5 mm, on the cyst wall through the central area of the cornea), and subsequent application of argon laser (200 mW strength, 100 μ m sight, 0.1 s duration, 20 pulses). There was no relapse of the lesion up to date.

In all cases of translucent epithelial cyst (six cases), presence of delamination of iris stroma caused by the lesion was observed (Fig. 3).

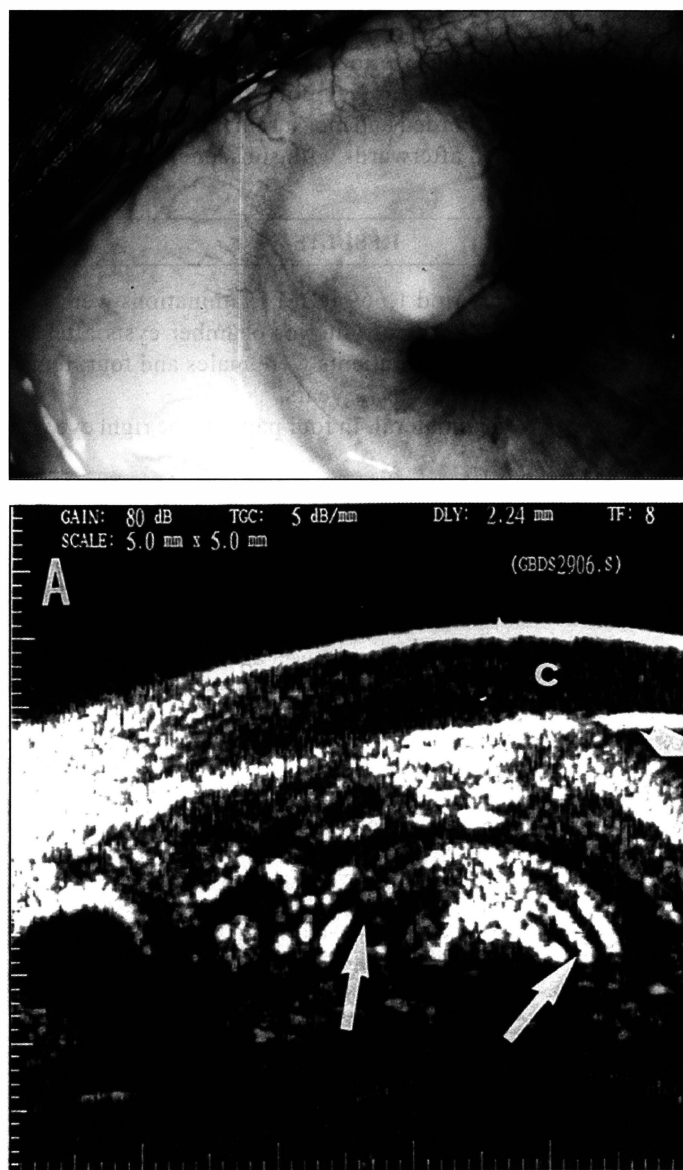


Fig. 1 - Photograph, using a slit lamp, showing a secondary implantation cyst in the iris, with whitish coloring, touching the posterior face of the cornea from 10 to 12 h, and associated with the presence of a cilium in the anterior chamber (resting on the iris at 9-10 h). 1A. Ultrasound biomicroscopy (UBM). Note the iris in contact with the cornea (c) (small arrow), and the cystic lesion with hyperreflective content, arranged in concentric multi-lamellae (large arrows), corresponding to keratin.

DISCUSSION

Iris and anterior chamber cysts may be primary or secondary. The former are congenital, a consequence of a defect in the neuroectodermal development of the iris or ciliary body leading to the separation between two epithelial layers and formation of a serous content between them¹⁰. They may be single or multiple, with a preferential topography at the pupil border or at the inferior temporal region of the iridociliary sulcus, with an anterior projection and therefore, in most cases, not being observed without midriasis^{11,12}. They tend to remain silent or grow slowly and rarely cause complications.

The secondary cysts stem from skin implantation, connective or corneal epithelium³ or from cells deriving from hair follicles (of cilia) in the anterior chamber^{4,5}, introduced by penetrating trauma or intraocular ophthalmological surgeries of the anterior segment.

It is considered a rare pathology. Our statistics of eight cases (0.48%) in 1,669 UBM examinations performed over a period of 35 months was due to this being a Reference Service. In addition it should be emphasized that this recent ultrasound modality is usually required for the assessment of cystic lesions affecting the anterior segment. According to the litera-

ture, the incidence of all forms of epithelialization of the anterior chamber ranges from 0.08-0.11% in 8,062 eyes submitted to extraction⁶ (on establishing the clinical diagnosis) to 16% (on anatomopathological examination of enucleated eyes), previously submitted to cataract surgery¹. The incidence is decreasing due to advances in surgical technique².

These lesions, on biomicroscopic examination, may appear as grayish pearly formations, called pearl cysts, deriving from the hair follicle, or may appear as cystic lesions with a translucent content (if their origin is the protective epithelium, cornea or conjunctiva). They may be isolated, implanted in the iris stroma or sometimes appearing free in the anterior cham-

ber or even connected to a badly coapted traumatic or surgical wound^{1-4, 11}. Downgrowth may be slow and, if clinically asymptomatic, they do not require treatment^{5, 11}. When causing decrease in visual acuity², intraocular inflammation with hypopyon³, isolated glaucoma or associated with corneal decompensation, they must be treated.

In the literature, a series of procedures are proposed, starting with cryotherapy¹, cauterization, injection of sclerosing substances, photocoagulation (argon laser) or photablation (Nd:YAG laser) alone or associated with previous puncture of the content, or even surgical excision of the whole lesion^{1-4, 11}. The treatment described as being the most definitive would be surgical excision with the previous use argon laser (500 μ m sight, 0.2 s duration and 700-1400 mW strength). Another cited modality is cystotomy or photablation by YAG laser², although relapses of these lesions in cystic or even flat form, due to dispersion of epithelial cells within the cyst are described². In order to decrease this risk, it is recommended to aspirate the cyst content with an insulin needle, under local anesthesia, prior to argon laser or photablation.

Ultrasound biomicroscopy (UBM) is a high resolution method used to determine anatomical relationships and abnormalities of the in the cornea, iris, anterior chamber, posterior chamber, ciliary body, angle structures, zonules and in the postoperative period of intraocular surgeries affecting the

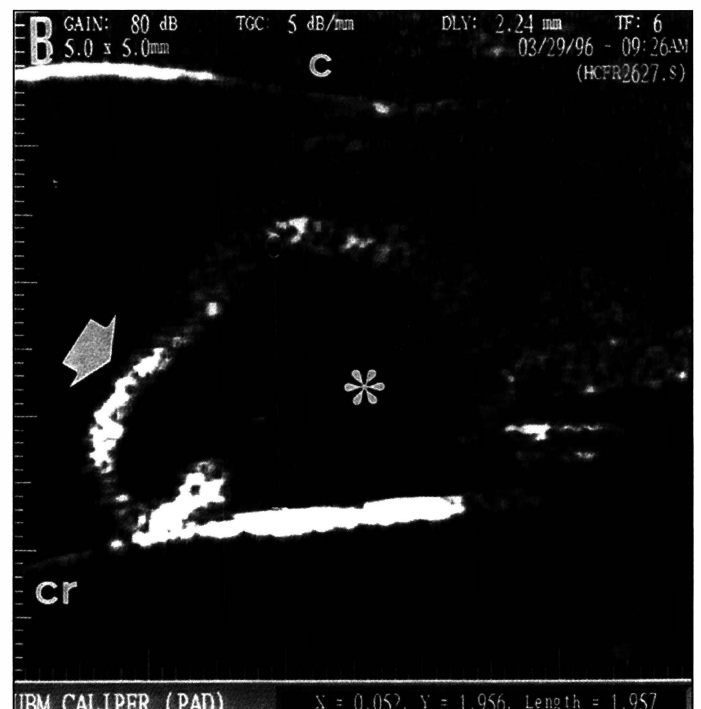
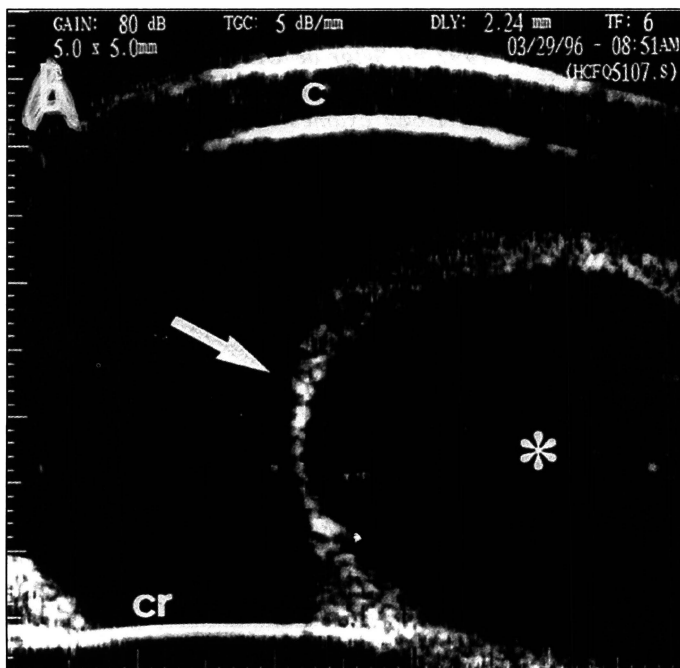
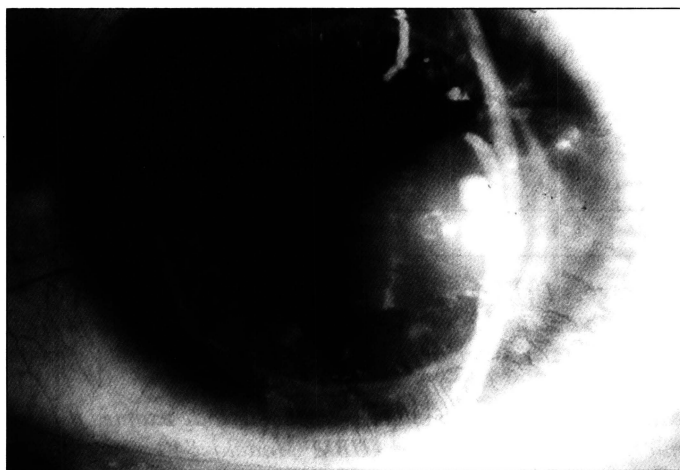

Fig. 2 - Photograph, using a slit lamp, showing a secondary implantation cyst in the iris, post-corneal graft, brown coloring, translucent, whose wall makes contact with the posterior face of the cornea at 3 to 6 h. 2A. UBM where the echos referring to the cornea (c), a thin-walled, hyperreflective cystic lesion (arrow) with hypodense content (*) can be seen in contact with the anterior face of the lens (cr) and passing the midline of the pupil area (visual axis), with a height = 3.57 mm. 2B. After treatment (with YAG laser and subsequently argon laser), there was a retraction of the cyst wall and decrease in height = 1.95 mm.

anterior segment⁸⁻¹⁰. This method has also been important for the differentiation between cystic lesions and solid iris and ciliary body tumors⁹.

In this series it was observed that secondary implantation cysts were unilateral, single and appeared in eyes with previous traumas (surgical or not). Through UBM examination it was observed that these cysts have relatively thick walls and that their content may be hypodense (translucent) with several particles in suspension (probably desquamating epithelial cells) or arranged in hyperreflective concentric layers corresponding to keratin lamellae (cilium in the anterior chamber, causing implantation of keratin producing stratified squamous epithelium, according to the anatomopathological examination). In addition, another UBM finding, related only to cysts with hypodense content, was iris stroma delamination, an information not available by other diagnostic means.

Using UBM examination, it was possible to differentiate these secondary lesions from primary cystic lesions, which, in turn, are characterized by presenting a thin, highly reflective wall, with hypodense content, besides having the character of being multiple and bilateral.

Differentiation between secondary cystic lesions is important to establish prognosis and management. If the content of the secondary cyst is hypodense, management is possibly expectant (if no associated complication indicates the need for surgery) or laser cystotomy, preferentially associated with previous puncture of the content. In the case the

content presents keratin lamellae, denoting origin in the hair follicle, management will be to indicate lesion excision.

UBM is also useful in the assessment of the dimensions and surgical planning of lesion excision. Serial study may be useful in the follow-up of the cases in which observation was the option.

We conclude that ultrasound biomicroscopy (UBM), a noninvasive method, is of great value for the diagnosis of anterior chamber cystic lesions, differentiating their content (if hypodense or hyperreflective) and also differentiating them from solid lesions, such as malign iris or ciliary body tumors extending to the iris. Since secondary iris and anterior chamber implantation cysts are rare pathologies and have a controversial treatment^{1,2}, it has been shown that the additional information provided by UBM examination allows more precisely to determine management in each particular case. And the usefulness of UBM in the postoperative follow-up, assessing effectiveness and possible sequelae, was also proven.

RESUMO

Objetivos: *Determinação de correlação clínica e ultra-sonográfica de lesões císticas de implantação secundária em íris e câmara anterior, referidas após trauma ou cirurgia intra-ocular.*

Material e Métodos: *Estudo retrospectivo de exames de biomicroscopia ultra-sônica (UBM Modelo 840 - Humphrey Instruments, EUA, equipado com transdutor de 50 MHz, utilizando-se a técnica de imersão), atendidos de agosto de 1994 a julho de 1997 no Setor de Ultra-sonografia Ocular da UNIFESP-EPM.*

Resultados: *Dentre 1.669 exames de UBM, foram encontrados 8 casos de cistos epiteliais de implantação secundária, sendo 3 após trauma (2 sob forma de lesão amarelado-esbranquiçada que ao exame anátomo-patológico demonstrou conteúdo de lamelas concêntricas de queratina; outro com suspeita de trauma penetrante auto-selante com lesão de conteúdo hipodenso) e 5 após cirurgia intra-ocular (pós-facectomia isolada, 3 casos; pós-transplante penetrante de córnea, 2 casos). Um dos casos pós-facectomia extracapsular referia trauma penetrante pregresso. À UBM, identificaram-se os cistos de implantação secundária como lesões unilaterais, únicas, de conteúdo hipodenso (com partículas em suspensão) ou dispostas em camadas hiper-refletivas (lamelas de queratina, no caso dos cistos de aspecto perláceos, cuja origem está nas células de folículo piloso implantado). Em todos os casos de conteúdo hipodenso (6) observou-se a delaminação do estroma iriano, informação não disponível por meio de outros métodos. Pelo do exame de UBM realizou-se o acompanhamento pós-operatório em 2 casos (1 submetido a exérese cirúrgica, outro à cistotomia com laser) ou então o exame seriado se decidido pela observação clínica.*

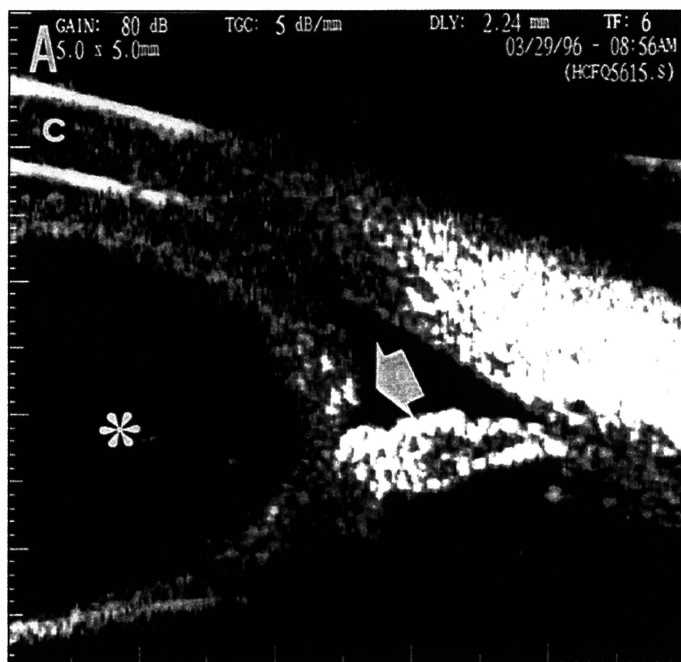


Fig. 3 - Ultrasound biomicroscopy (UBM) of a peripheral section of the anterior chamber at the lesion area, where iris stroma delamination close to the iris root (arrow) constituting the walls of the cyst with hypodense content (*) can be observed, defining the anterior and posterior corneal echos.

Conclusão: O exame de UBM pôde diferenciar os tipos de epiteliação de câmara anterior (forma cística ou plana), detectar lesões associadas indicando tratamento mais adequado, e o acompanhamento destas lesões após tratamento ou não.

Palavras-chave: Biomicroscopia ultra-sônica; Cisto iriano secundário; Epitelização da câmara anterior.

REFERENCES

1. Maumenee AE, Paton D, Morse PH, Butner R. Review of 40 histologically proven cases of epithelial downgrowth following cataract extraction and suggested surgical management. *Am J Ophthalmol* 1970;69:598-603.
2. Orlin SE, Raber IM, Laibson PR, Shields CL, Brucker AJ. Epithelial downgrowth following the removal of iris inclusion cysts. *Ophthalm Surg* 1991;22:330-5.
3. Finger PT, McCormick SA, Lombardo J, Tello C, Ritch R. Epithelial inclusion cyst of the iris. *Arch Ophthalmol* 1995;113:777-80.
4. Ibechukwu BI, Ikerionwu SE, Al-Faran MF. Intraocular implantation dermoid cyst of the iris: case report. *East Afr Med J* 1996;73:210-1.
5. Mattos WB. Um cílio vinte anos na câmara anterior. *Arq Bras Oftalmol* 1943;6:38-9.
6. Theobald GD, Haas JS. Epithelial invasion of the anterior chamber following cataract extraction. *Trans Am Acad Ophthalmol Oto* 1948;52:470.
7. Maumenee AE. Treatment of epithelial downgrowth and intraocular fistula following cataract extraction. *Trans Am Acad Ophthalmol Oto* 1964;62:153.
8. Allemann N. Biomicroscopia ultra-sônica. *Arq Bras Oftalmol* 1995;58:283-5.
9. Pavlin CJ. Practical application of ultrasound biomicroscopy. *Can J Ophthalmol* 1995;30:225-9.
10. Azuara-Blanco A, Spaeth GL, Araújo SV, Augsburger JJ, Terebuch AK. Plateau iris syndrome associated with multiple ciliary body cysts. *Arch Ophthalmol* 1996;114:666-8.
11. Almeida HG, Almeida GV, Calixto N, Carvalho CA. Galucomas Secundários, 1ª ed. São Paulo: Livraria Roca 1989;249-53.
12. Sidoti PA, Valencia M, Chen N, Baerveldt G, Green RL. Ecographic evaluation of primary cysts of the iris pigment epithelium. *Am J Ophthalmol* 1995;120:161-7.

VIII Simpósio Internacional de Córnea e Lentes de Contato

VII Simpósio Internacional de Catarata e Lentes Intra-oculares

19 e 20 de março de 1999
Hotel Gran Meliá - São Paulo - SP

PROMOÇÃO

Seminário Oftalmológica da UNICAMP

Comissão Organizadora:

Carlos Eduardo Leite Arieta
Milton Ruiz Alves
Newton Kara José
Nilo Holzchuh

Palestrantes Internacionais confirmados:

Alejandro Berra	- Argentina
Jeffrey Gilbard	- EUA
Juan Morube	- Espanha
Mauricio Rolando	- Itália
Peter C. Donshik	- EUA
Pfluge Felder	- EUA
Rafael Fuster	- Chile
Ramon Naranjo	- México
Tomy Starck	- EUA

INFORMAÇÕES: JDE Comunicação e Eventos

Tels: (011) 289-4301 e 251-5273 - Fax: (011) 288-8157 - E-mail: <jdecomeve@uol.com.br>