

Lumbar mass as the presentation form of a tuberculous spondylodiscitis

Marcílio Diogo de Oliveira Barbosa¹, Rodrigo Sodré Calheiros da Silva¹,
Flávio Assad Garcia¹, Marcus André Acioly^{1,2,3}

A 32-year-old man presented with an increasing lumbar mass which was initially noted 5 months before admission. He reported a 4-month history of minor low back pain radiating to his right leg and night sweats. Physical examination revealed only a left painful lower lumbar tender mass. Lumbar MRI demonstrated spondylodiscitis over L3-L4 complicated by epidural abscess, as well as bilateral psoas abscesses spreading through the posterior abdominal wall on the left side (Figure). The patient was then submitted to a L3 hemilaminectomy with biopsy and surgical debridement of the L3-L4 intervertebral disc space. Histopathological examination showed tuberculous granuloma and the patient was properly treated.

After break out of the purulent material from the vertebral body, a psoas abscess may develop and expand through the path of least resistance^{1,2}. The presentation thus depends on the anatomical path of abscess' dissemination¹. In this regard, a lower lumbar mass may occur when the purulent material leaves the psoas above the iliac crest extending posteriorly through the inferior lumbar triangle or Petit's triangle.

REFERENCES

1. Millar TM, McGrath P, McConnachie CC. Tuberculosis of the spine presenting with a cold abscess through the lumbar triangle of Petit. *Clin Anat* 2007;20:329-331.
2. Sanal HT, Kocaoglu M, Sehirlioglu A, Bulakbasi N. A rare cause of flank mass: psoas abscess due to extensive primary thoracolumbar tuberculous spondylodiskitis. *AJNR Am J Neuroradiol* 2006;27:1735-1737.

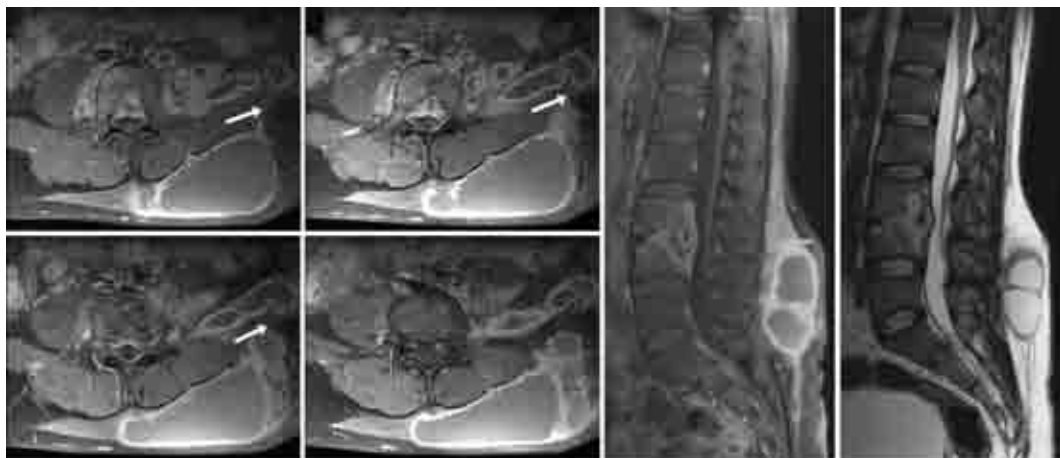


Figure. Sequential axial and sagittal gadolinium-enhanced T1-weighted (left) and sagittal T2-weighted (right) MR images showing the continuous spectrum of the disease from the intervertebral disc to the subcutaneous space through the posterior abdominal wall (white arrows).

MASSA LOMBAR COMO FORMA DE APRESENTAÇÃO DE ESPONDILODISCITE TUBERCULOSA

¹Division of Neurosurgery, Andaraí Federal Hospital, Rio de Janeiro RJ, Brazil; ²Department of Surgical Specialties, Division of Neurosurgery, Pedro Ernesto University Hospital, State University of Rio de Janeiro, Rio de Janeiro RJ, Brazil; ³Department of Neurology, University of São Paulo, São Paulo SP, Brazil.

Correspondence: Marcus André Acioly - Rua Leopoldo 280 - 20541-170 Rio de Janeiro RJ - Brasil. E-mail: marcusacioly@yahoo.com.br

Received 23 March 2011, received in final form 16 April 2011. Accepted 26 April 2011.