

Incision and Drainage with Daily Irrigation for the Treatment of Auricular Pseudocyst

Hazem M. Abdel Tawab^{1,2} Salim M. Sloma Tabook¹

¹Department of Otorhinolaryngology, Sultan Qaboos Hospital, Salalah, Oman

²Department of Otorhinolaryngology, Faculty of Medicine, Cairo University, Cairo, Egypt

Address for correspondence Hazem M. Abdel Tawab, MD, Department of Otorhinolaryngology, Faculty of Medicine, Cairo University, Cairo 12111, Egypt (e-mail: hazemabdeltawwab77@yahoo.com).

Int Arch Otorhinolaryngol 2019;23:178–183.

Abstract

Introduction Pseudocyst of the pinna is a rare condition that occurs when fluid accumulates in the intercartilagenous space of the auricle. The main goal when treating this condition is to keep acceptable cosmetic results with no recurrence rate.

Objective To demonstrate the superior impact of incision and drainage of auricular pseudocysts with the insertion of a catheter drain and daily irrigation as the treatment of this condition.

Methods A total of 42 patients with auricular pseudocysts were enrolled in the present study in the period between May 2011 and May 2017. All of the patients were treated with incision and drainage with compression. The average follow-up time reached ~ 6 months in all of the cases.

Results All of the patients had satisfactory cosmetic results with no recurrence and no complications.

Conclusion Among the different methods of surgical treatment of pseudocyst of the pinna, incision and drainage with daily irrigation is a significantly efficient method both for the eradication of auricular pseudocysts and for good cosmetic results.

Keywords

- pseudocyst
- pinna
- incision

Introduction

Auricular pseudocyst of the pinna is a benign painless condition characterized by the accumulation of fluid in the intercartilagenous space of the auricle. It was described as auricular pseudocyst by Engel, in 1966, due to the fact that it lacks an epithelial lining.¹ The most common sites of affection encountered are the cymba concha, the scaphoid fossa, and the triangular fossa.² Other synonyms for this condition are endochondral auricular pseudocyst, cystic chondromalacia, and benign idiopathic cystic chondromalacia.³ In most of the cases, pseudocyst of the pinna is asymptomatic; however, sometimes it can produce some sense of discomfort. Its size ranges from 1 to 5 cm in diameter, and its content is usually a viscous straw-yellow fluid, although, sometimes, a clear pale yellow fluid might be seen.³ The aim of the treatment of this condition is the preservation of the normal shape and characters of the pinna and the prevention of recurrence, while keeping a good cos-

metic appearance. Many treatment options have been mentioned in the literature, such as simple aspiration and pressure, intralesional steroid injection, derofreeing, compression buttons, sclerosing agents, and excision of the anterior cartilage, but with a recurrence rate or some complications, encountered especially in the simple aspiration of the cyst.⁴ In the present work, we present 42 patients with pseudocyst of the pinna who were treated with incision, drainage, and insertion of a catheter drain with compression for 10 days, with no recurrence over an average period of 6 months, and with no complications or deformities. The objective of the present study is to demonstrate the superior results of incision, drainage and daily irrigation in the treatment of auricular pseudocysts.

Methods

The present retrospective study included 42 patients with pseudocyst of the pinna who presented to the outpatient

received
December 31, 2017
accepted
October 12, 2018
published online
February 6, 2019

DOI <https://doi.org/10.1055/s-0038-1676124>.
ISSN 1809-9777.

Copyright © 2019 by Thieme Revinter Publicações Ltda, Rio de Janeiro, Brazil

License terms



clinic of our department of otorhinolaryngology from May 2011 to May 2017.

Before the start of data collection, ethical approval was obtained from the local ethics committee.

All of the files of the patients were retrieved from our computer system and from the paper medical reports. Full history details were obtained, especially the onset and duration of the swelling, any possible relation with a traumatic episode, as well as the presence of discomfort or pain related to the condition.

Cases with a previous attempt of aspiration, injection or incision of the cyst were excluded from the study. Since 1999, various methods of treatment had been implemented in our department for this condition, such as simple aspiration and pressure, as well as the derroofing technique, but due to cosmetically unsatisfactory results or to recurrence of the swelling, these methods had been replaced with incision, drainage, insertion of a catheter drain, and pressure, with daily irrigation for a minimum period of 10 days.

Age and gender of the patients, history of trauma, laterality of the lesion, duration, site, size and content of the swelling have been documented for any possible or surprising importance.

Informed consent was obtained from all patients after they received an explanation of the procedure, of the post-operative care, and of the follow-up.

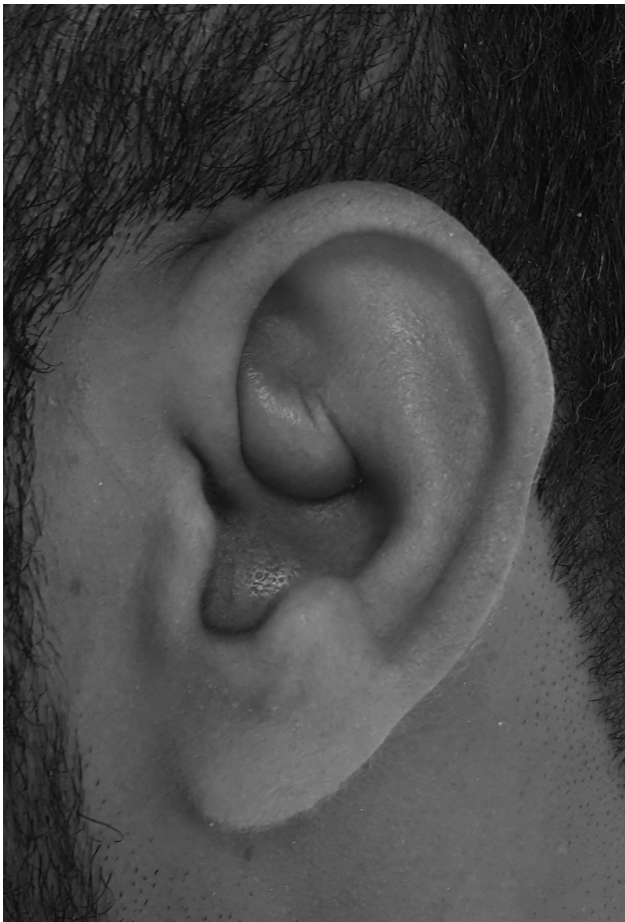

Fig. 1 The pseudocyst as seen before the procedure.

Surgical Technique

The swelling was assessed for size and site (→**Fig. 1**). The pinna was disinfected with Betadine, and then draped.

Between 0.1 and 0.2 ml of fluid was aspirated from the swelling for the inspection of the character of the fluid. Local anesthesia infiltration with 2% xylocaine and 1:200,000 adrenaline was performed at the proposed sites of incision. The swelling was then incised from its upper and lower ends, with squeezing of the content of the cyst and dissection inside the cavity with an artery forceps. The insertion of a drain catheter from the upper to the lower incision keeping its upper free and lower free ends seen from the incision sites. The drain catheter was provided with two to three pores along its lumen to facilitate daily irrigation with sodium chloride 0.9% and Betadine later on. The drain was held in place with one nylon 3-0 stitch in its upper part (→**Fig. 2**). In some cases with large pseudocysts we added another stitch to the lower part of the drain catheter.

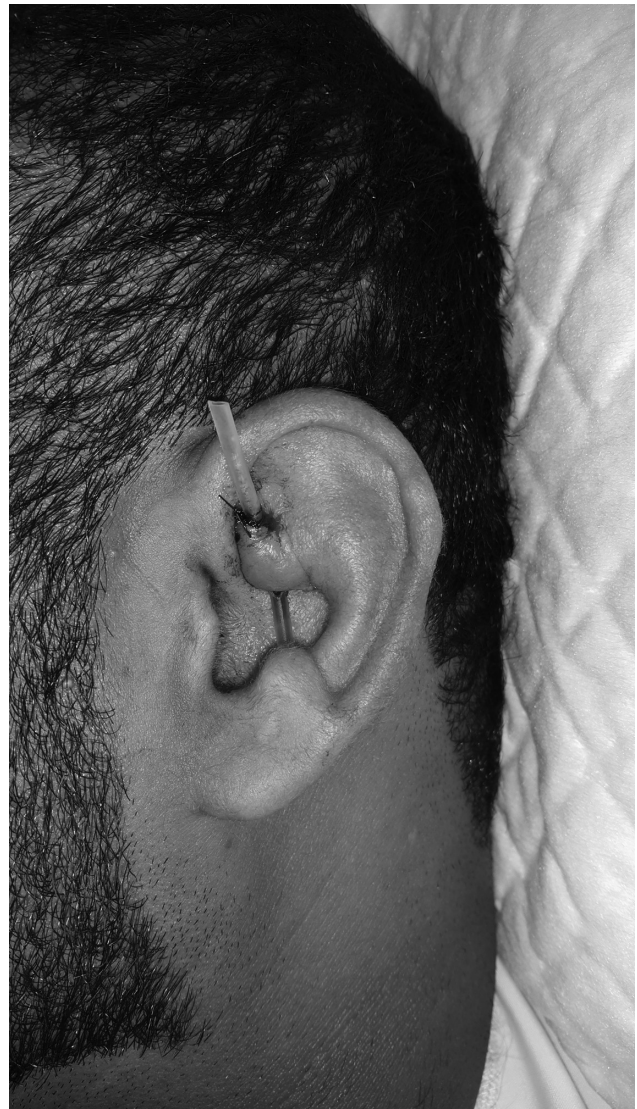


Fig. 2 Drain catheter stitched to the upper incision site.

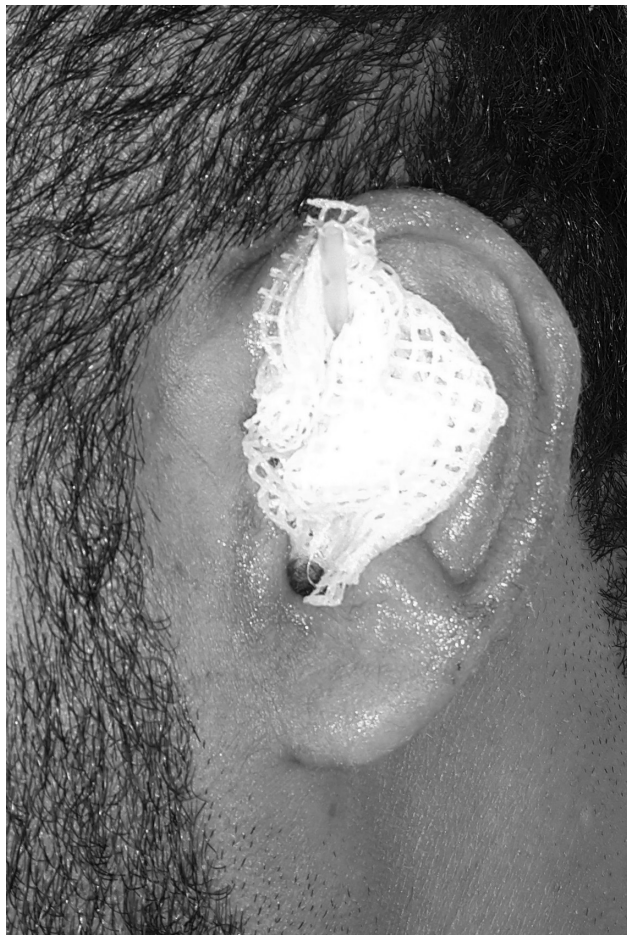

Fig. 3 Vaseline gauze to protect the pinna from the edges of the drain catheter.

Vaseline gauze to protect the ear pinna from any possible injury by the drain free upper and lower edges (**►Fig. 3**).

After cleaning and evacuating the cyst, a mastoid dressing was applied. It was changed daily, along with irrigation with sodium chloride 0.9% and Betadine for 10 days using a 3 mm syringe through the drain, followed by squeezing of any accumulated secretions. The mastoid dressing was reapplied each time after dressing gauze (**►Fig. 4**).

Some cases and their results are presented in **►Figs. 5–8**.

The patients were followed-up for residual or recurrent swelling or other complications for an average period of 6 months.

Statistical Data

Demographic data are expressed in numbers and percentages as needed.

Results

The present retrospective study was conducted on all of the patients who presented with painless auricular swelling of long duration. It involved 42 patients, of which 40 were male (95.2%), and two were female (4.8%).

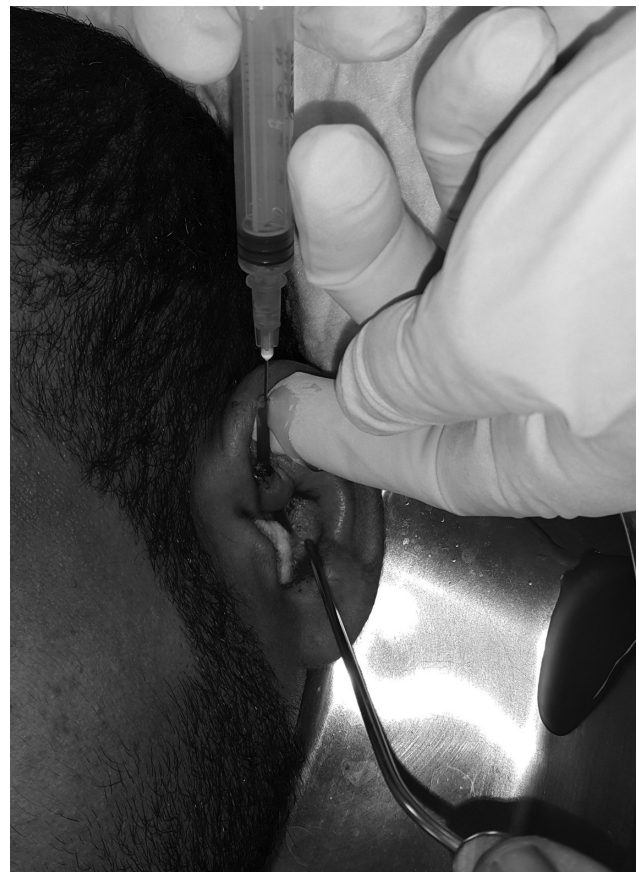

Fig. 4 Daily irrigation with sodium chloride 0.9% and betadine.

The average age of the patients included in the present study was 34.9 years old. The age groups of the patients are demonstrated in **►Table 1**.

The most common site of occurrence of pseudocysts of the auricle in the present study was the scaphoid fossa (22 cases, 52.38%). The sites of occurrence of pseudocysts of the pinna in the present study are demonstrated in **►Table 2**.

The incidence of pseudocysts was higher in the right ear (33 cases), with only 9 cases in the left ear.

The sizes of the pseudocysts encountered in the present study ranged from 1 to 4.5 cm, with an average size of 2.96 cm.

The content of the pseudocysts was straw fluid in 34 cases and dark yellowish fluid in 8 cases.

The average duration of the swelling in the patients was of 3.5 months.

All of the patients had undergone incision and drainage with the insertion of a catheter drain in the wound as described above. The patients had been followed-up for between 6 and 30 months, with an average of 6 months.

We did not encounter any complications during the whole follow-up period, and all of the patients had a satisfactory cosmetic appearance with no recurrence of the swelling.

Discussion

Pseudocyst of the pinna is a rare asymptomatic condition in which an accumulation of intercartilagenous fluid occurs with no surrounding epithelium. The etiology of this condition is

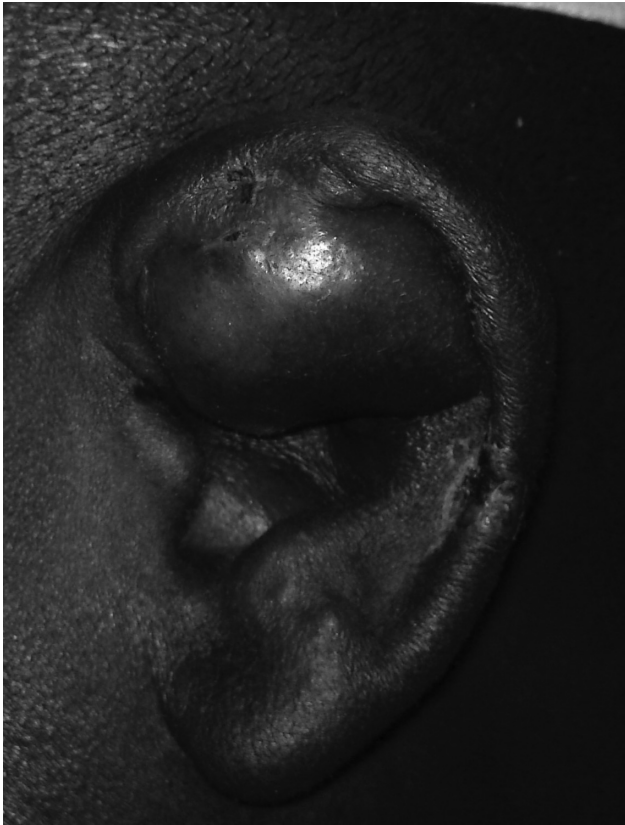

Fig. 5 Pseudocyst of one patient.

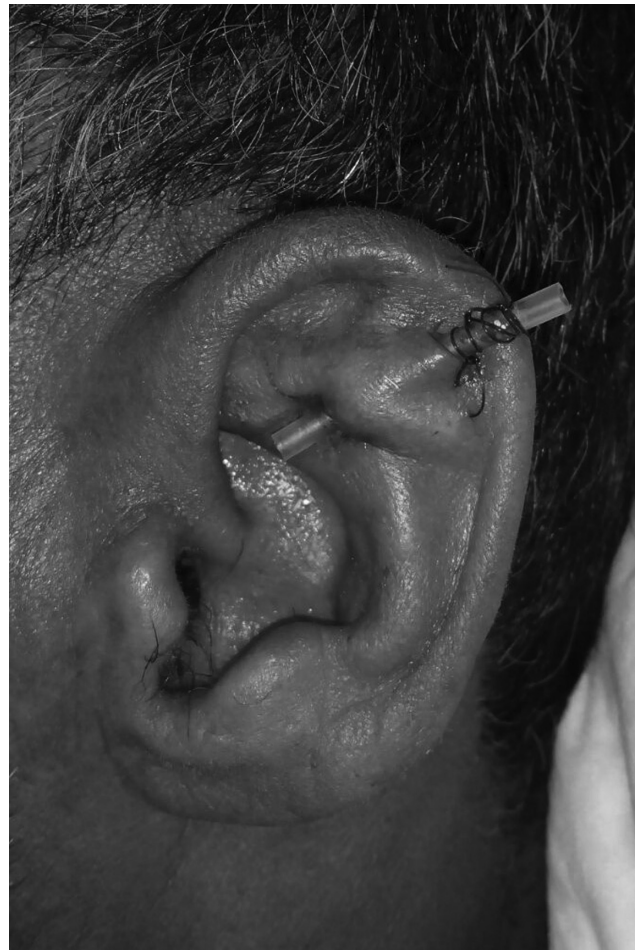

Fig. 7 Pseudocyst in one patient after the insertion of the drain.

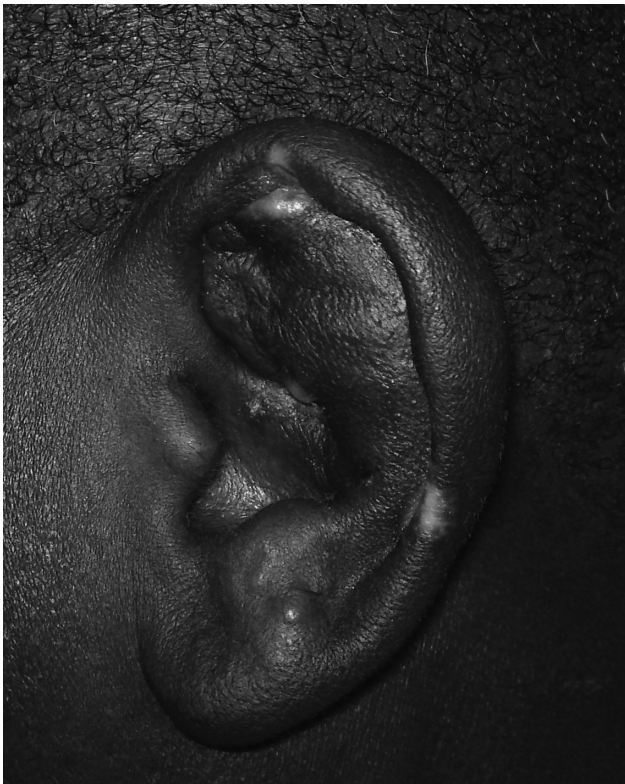


Fig. 6 Same patient after 1 month of treatment.

not well known; however, many theories have been postulated. The first is congenital embryonic dysplasia of the auricular cartilage leading to the formation of potential spaces in the auricle.⁵ Another accepted theory is the occurrence of minor repeated traumas, which can result in the fragmentation of the cartilage and in the formation of cavities.⁶ In the literature, auricular pseudocyst has been correlated with repeated minor traumas, such as rubbing, ear pulling, sleeping on hard pillows, or wearing a motorcycle helmet or earphones. This finding has supported the theory of traumatic pseudocyst formation. In one study, 22 out of 28 cases had a clear history of trauma preceding the formation of the pseudocyst.⁷ In the present study, all of the patients denied any history of trauma, and there was no similar condition in the family.

Most of the studies showed a higher prevalence in males, such as the study by Kantora et al, for example.⁸ However, another study documented a higher prevalence in females, corresponding to 57% out of 14 cases included in the study.⁹ In the present study, males represented 95.2% of the 42 patients included.

Choi et al presented an average age of ~ 42.8 years old for the occurrence of pseudocysts of the pinna.² This was similar to the findings of the study by Wang et al, in which the average age was 43.8 years old.⁹ In the present study, the average age was ~ 34.9 years old.

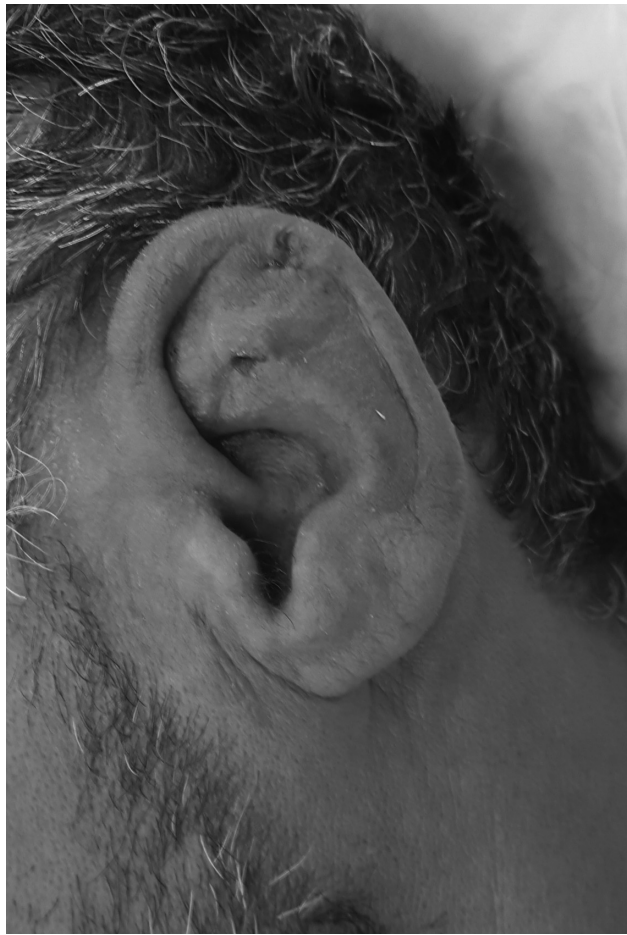

Fig. 8 Same patient after the removal of the drain catheter, in which the pseudocyst disappeared.

Table 1 Age groups of the patients

Age group	Number of patients
≤20	5
21–30	4
31–40	23
41–50	9
> 50	1

Table 2 Sites of occurrence of auricular pseudocyst

Site	<i>n</i>
Scaphoid fossa	22
Scaphoid and triangular fossae	9
Triangular fossa	7
Concha	4

Tan et al documented a higher incidence of pseudocysts in the right ear than in the left ear, with a ratio of 1.8:1.¹⁰ However, in another study, the incidence of pseudocysts in the right ear and in the left ear were equal (1:1).⁹

In the present study, the ratio of occurrence of pseudocysts between the pinna of the right ear and the pinna of the left ear was of 3.66:1. The higher incidence in the right ear might be correlated with the habit of sleeping on the right side, which was mentioned by most of the patients in the study.

Kantora et al documented a higher incidence of auricular pseudocysts in the concha fossa (72.1%),⁸ while Choi et al found a higher incidence in the scaphoid fossa (80.6%).² In the present study, the incidence of pseudocysts in the scaphoid fossa alone reached ~ 52.38%.

Several methods of treatment for pseudocysts of the auricle have been discussed in the literature. The main aim of all these modalities is to preserve the healthy cartilage and to prevent recurrence of the swelling.¹¹

All methods of compression dressings, such as traditional contour dressing, compression suture therapy,⁴ clip compression dressing,¹² bolstered pressure suture,¹³ and clothing button bolster⁸ after aspiration can decrease the chances of recurrence. However, the prevention of recurrence of the lesions cannot be guaranteed.

The introduction of systemic or intralesional steroids for the treatment of pseudocysts of the auricle is still controversial.

While Juan¹⁴ reported good results in treating pseudocysts with a maximum of three intralesional steroid injections, Glamb et al¹⁵ reported permanent deformity of the ear despite the use of local or systemic steroids.

Surgical deroofting of the pseudocysts of the pinna has also been discussed in the literature, with some reports stressing its benefits for good cosmetic appearance and no recurrence rate.^{8,9} However, there are also reports documenting some complications of this technique, such as perichondrial reactions, and thickness of the pinna.⁷

Singh et al, in their study in 2014, documented the benefits of incision and drainage with glove drain insertion. They described this minimally invasive technique in 20 cases enrolled in their study, with no recurrences over the 3-month period of follow-up.¹⁶ They mentioned the drawback of the requirement of good compliance on the part the patient for multiple visits to the hospital in order to change the dressing and to clean the wound. One thing to be added here is the requirement of a longer period of follow-up after the procedure.

In the present study, incision and drainage with the insertion of a catheter drain under local anesthesia proved to be effective in all of the 42 patients, without complications, with good cosmetic results, and with no recurrence rate over an average follow-up period of 6 months. Daily irrigation helped to prevent infection and to clean any reaccumulating fluid, and this, in particular, contributed to the efficacy of the incision and drainage as a trusted method for the treatment of auricular pseudocysts. This method required good compliance on the part of the patients, since they needed to attend to the hospital for daily dressing and cleaning.

Conclusion

Incision and drainage of auricular pseudocysts with the insertion of a catheter drain and daily dressing and cleaning

of the wound for 10 days proved to be a minimally invasive technique with no recurrence rate over a long follow-up period, and this method presented good cosmetic results with no complications.

Ethics Committee Approval

The present study was approved by the local ethics committee.

Informed Consent

A signed informed consent was obtained from all the participants of the present study.

Conflicts of Interest

The authors have no conflicts of interest to declare.

Financial Disclosure

The authors declare that the present study received no financial support.

References

- Engel D. Pseudocysts of the auricle in Chinese. *Arch Otolaryngol* 1966;83(03):197–202
- Choi S, Lam KH, Chan KW, Ghadially FN, Ng AS. Endochondral pseudocyst of the auricle in Chinese. *Arch Otolaryngol* 1984;110(12):792–796
- Ramadass T, Ayyaswamy G. Pseudocyst of auricle - etiopathogenesis, treatment update and literature review. *Indian J Otolaryngol Head Neck Surg* 2006;58(02):156–159
- Karabulut H, Acar B, Seluck K. Treatment of the non-traumatic auricular pseudocyst with aspiration and intralesional steroid injection. *N J Med* 2009;26:117–119
- Ichioaka S, Yamada A, Ueda K, Harii K. Pseudocyst of the auricle: case reports and its biochemical characteristics. *Ann Plast Surg* 1993;31(05):471–474
- Hoffmann TJ, Richardson TF, Jacobs RJ, Torres A. Pseudocyst of the auricle. *J Dermatol Surg Oncol* 1993;19(03):259–262
- Patigaroo SA, Mehfooz N, Patigaroo FA, Kirmani MH, Waheed A, Bhat S. Clinical characteristics and comparative study of different modalities of treatment of pseudocyst pinna. *Eur Arch Otorhinolaryngol* 2012;269(07):1747–1754
- Kanotra SP, Lateef M. Pseudocyst of pinna: a recurrence-free approach. *Am J Otolaryngol* 2009;30(02):73–79
- Wang H-L, Kuen-Yao Ho. Sheau-Fang Yang, Yu-Jen Wu, Hsun-Mo Wang. The Experience of Reliable Surgical Management for Intractable Auricular Pseudocysts. *Int Adv Otol* 2013;9(03):313–318
- Tan BY, Hsu PP. Auricular pseudocyst in the tropics: a multi-racial Singapore experience. *J Laryngol Otol* 2004;118(03):185–188
- Schulte KW, Neumann NJ, Ruzicka T. Surgical pearl: The close-fitting ear cover cast—a noninvasive treatment for pseudocyst of the ear. *J Am Acad Dermatol* 2001;44(02):285–286
- Kim TY, Kim DH, Yoon MS. Treatment of a recurrent auricular pseudocyst with intralesional steroid injection and clip compression dressing. *Dermatol Surg* 2009;35(02):245–247
- Zhang XT, Sun B, Ling Y, et al. [Investigation of clinical pathology and treatments on the auricle pseudocyst]. *Zhonghua Er Bi Yan Hou Tou Jing Wai Ke Za Zhi* 2010;45(08):640–644
- Juan KH. Pseudocyst of the auricle: steroid therapy. *Auris Nasus Larynx* 1994;21(01):8–12
- Glamb R, Kim R. Pseudocyst of the auricle. *J Am Acad Dermatol* 1984;11(01):58–63
- Singh D, Goswami R, Dudeja V. Management of Auricular Pseudocyst: A Comparative Study. *Int J Med Res Rev* 2014;2(05):457–462