

Perforation of pyometra presenting as obstructive acute abdomen and peritonitis: a case report

Perfuração de piometra apresentando-se como abdômen agudo obstrutivo e peritonite: relato de caso

Paulo Melo; Luis Jesuino Andrade; Fernando Elias Cruz; Emmanuel Conrado

Universidade Estadual de Santa Cruz (UESC), Bahia, Brazil.

ABSTRACT

We report a rare case of a 67-year-old postmenopausal woman presenting diffuse peritonitis secondary to spontaneous perforation of pyometra with obstructive acute abdomen. During laparotomy was performed subtotal abdominal hysterectomy with bilateral salpingo-oophorectomy. The histopathology found the presence of moderately differentiated uterine squamous cell carcinoma. Despite intensive care, the patient died due to multiple organ failure resulting from sepsis on postoperative day 1. This case shows the importance of clinical suspicion on the acute gynecological diseases presenting as a systemic disease in the emergency room.

Key words: uterine perforation; acute abdomen; pyometra.

INTRODUCTION

Accumulation of pus in the uterine cavity has a very rare incidence contributing to less than 1% in outpatients abdomen acute younger than 50 years of age, reaching about 12% in woman older than 60 years^(1, 2). Therefore, spontaneous rupture of pyometra in cervical cancer presenting as generalized peritonitis is very uncommon; there is a lack of data on the incidence in our country, as well in many parts of the world, with few cases described. Pyometra develops slowly leading to enlarge of the uterus, causing histological changes that may rarely lead to desquamation of the uterine wall with drainage of contents into the abdominal cavity^(3, 4). There are not many manuscripts reporting Pyometra as the cause of acute abdomen neither worldwide nor in Brazil. This paper reports an additional case of spontaneous uterine perforation due to pyometra probably caused by a malignance presenting as obstructive acute abdomen.

CASE PRESENTATION

A 67-year-old multiparous postmenopausal woman was admitted presenting a diffuse abdominal pain and vomiting during

the previous 24 hours. Her past medical or gynecological history was unremarkable, and there was no history of postmenopausal bleeding or vaginal discharge. During physical examination, she appeared to be ill, dehydrated, with vital signs as follows: body temperature 37.2°C, blood pressure 100/60 mmHg, pulse rate 112 beats/min. Her abdomen was distended, with pain in the lower portion. Bowel sounds were hypoactive, there were no palpable masses. Vaginal examination showed no cervical and vaginal anomalies, vaginal discharge, nor detectable pelvic mass. Results of laboratory investigations on admission were as follows: white blood cell (WBC) count $4.6 \times 10^3/\mu\text{l}$, hemoglobin 9.2 g/dl, platelets $359 \times 10^3/\mu\text{l}$, creatinine 1.2 mg%, urea 53 mg%. A computed tomography (CT) scan – without contrast – showed the presence of fluid within the abdominal cavity and a significantly distended fluid-filled uterus (**Figure 1**). Nasogastric tube was placed to remove gastric contents, including air, decompressing the stomach (about 1000 ml of faecaloid content was obtained). Then, laparotomy subtotal hysterectomy with salpingo-oophorectomy was performed (**Figure 2**). About 1500 ml of pus was found in the peritoneal cavity (culture of the pus did not grow any organism). Histologic examination revealed pyometra with evidence of malignancy. The histopathology showed uterine cancer (**Figure 3**). Despite exhaustive clinical efforts, the patient died on postoperative day 1 (POD 1), from sepsis that progressively increased.

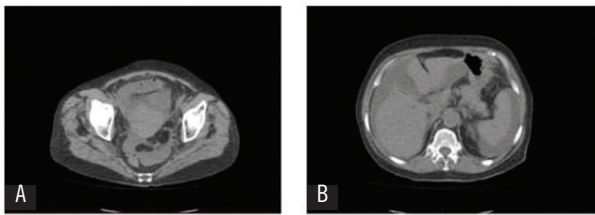


FIGURE 1 – Transverse plane of CT scan

A) showing the uterus distended with significantly fluid-filled uterus; B) presence of fluid within the abdominal cavity.

CT: computed tomography.

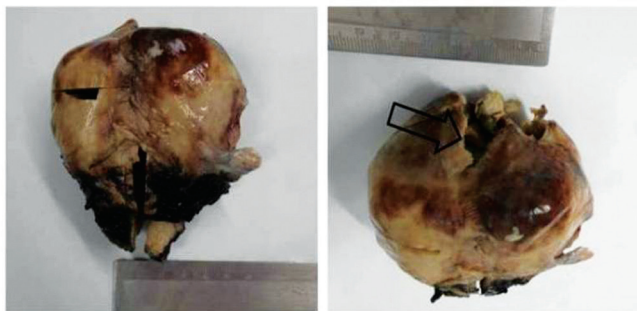

FIGURE 2 – The resected uterus. The arrow points the possible perforation site

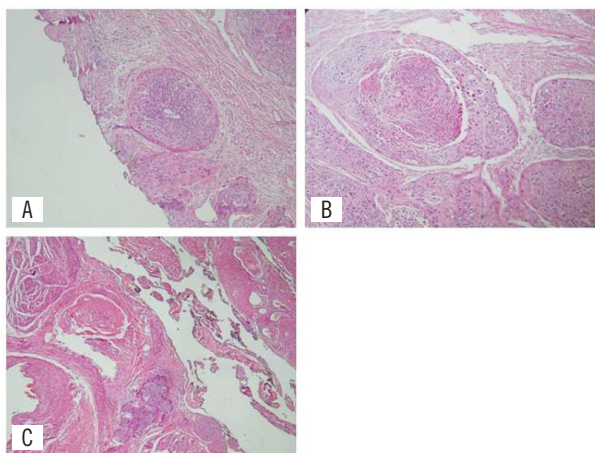


FIGURE 3 – Histopathology showing keratinizing squamous cell carcinoma mildly-differentiated

A) compromised limit; B) keratinization; C) parametrial invasion.

DISCUSSION

Despite rare in the general population, pyometra have to be kept in mind during clinical approach in elderly woman presenting acute abdomen. In this regard, the past history is important to show red flags such as uterus manipulation,

gynecological malignancy or consecutive infections⁽⁵⁻⁷⁾. Therefore, physical examination, laboratory and imaging tests (as CT) are the cornerstone to the diagnostic that could be though. CT has a crucial role in the diagnosis of pyometra considering some degree of suspicious⁽⁸⁾. The outcome is extremely variable, and in many cases the patients do not survive the surgery. Sometimes the period between diagnosis and surgery is too long. The symptoms alone do not help to organize the differential diagnosis; they should be added to the previous history and other tests such as laboratory, ultrasonography (USG) and CT.

In this case the preoperative diagnosis was acute abdomen agreeing with reports previously published⁽³⁾, confirming that is a difficult task. As well as the previous studies, we were not able to detect bacteria from the culture⁽⁹⁾. The patient had a previous diagnosis of hypertension in treatment, and no information on immunosuppression status. Few reports found malignancy associated with pyometra⁽¹⁰⁾. During macroscopic studies we found the potential perforation site at uterine fundus; and histopathology showed a mildly-differentiated keratinizing squamous cell carcinoma. Likely this malignancy was involved as a risk factor or the cause of pyometra development.

CONCLUSION

It is necessary a high index of suspicion (medical history, physical examination and laboratory tests) to make a correct preoperative diagnosis, early intervention, and adequate treatment to reduce morbidity and mortality. Otherwise, in case of severe infection, this disease can become life-threatening for many patients.

CONFLICT OF INTERESTS

The authors declare that there is no conflict of interests regarding the publication of this paper.

SUPPORT

Medical School at Universidade Estadual de Santa Cruz, Hospital Calixto Midlej Filho, Santa Casa de Misericórdia de Itabuna.

RESUMO

Relatamos um caso raro de uma mulher pós-menopausa com 67 anos de idade, a qual apresentou como peritonite difusa secundária a perfuração espontânea de piometra com abdômen agudo obstrutivo. Durante a laparotomia foi realizada bisterectomia abdominal subtotal com salpingo-ooforectomia bilateral. A histopatologia determinou a existência de carcinoma de células escamosas moderadamente diferenciado do útero. Apesar dos cuidados intensivos, a paciente veio a óbito por falência múltipla de órgãos decorrente de sepse no primeiro dia do pós-operatório. Este caso mostra a importância da suspeita clínica sobre as doenças ginecológicas agudas que se apresentam como doenças sistêmicas na sala de emergência.

Unitermos: perfuração uterina; abdômen agudo; piometra.

REFERENCES

1. Vyas AS, Kumar M, Prakash M, Kapoor R, Kumar P, Khandelwal N. Spontaneous perforation of pyometra in a cervical cancer patient: a case report and literature review. *Cancer Imaging*. 2009; 9: 12-4. PubMed PMID: 19419914.
2. Saha PK, Gupta P, Mehra R, Goel P, Huria A. Spontaneous perforation of pyometra presented as an acute abdomen: a case report. *Medscape J Med*. 2008; 10(1): 15. PubMed PMID: 18324325.
3. Geranpayeh L, Fadaei-Araghi M, Shakiba B. Spontaneous uterine perforation due to pyometra presenting as acute abdomen. *Infect Dis Obstet Gynecol*. 2006; 2006: 60276. PubMed PMID: 17485806.
4. Kitai T, Okuno K, Ugaki H, Komoto Y, Fujimi S, Takemura M. Spontaneous uterine perforation of pyometra presenting as acute abdomen. *Case Rep Obstet Gynecol*. 2014; 2014: 738568. PubMed PMID: 25057420.
5. Chan LY, Lau TK, Wong SF, Yuen PM. Pyometra. What is its clinical significance? *J Reprod Med*. 2001; 46(11): 952-6. PubMed PMID: 11762150.
6. Gu Y, Ohmagari N. Pyometra as a cause of fever; report on two cases. *Kansenshogaku Zasshi*. 2007; 81(3): 302-4. PubMed PMID: 17564120.
7. Ikeda M, Takahashi T, Kurachi H. Spontaneous perforation of pyometra: a report of seven cases and review of the literature. *Gynecol Obstet Invest*. 2013; 75(4): 243-9. PubMed PMID: 23548841.
8. Chan KS, Tan CK, Mak CW, Chia CC, Kuo CY, Yu WL. Computed tomography features of spontaneously perforated pyometra: a case report. *Acta Radiol*. 2006; 47(2): 226-7. PubMed PMID: 16604973.
9. Yamada T, Ando N, Shibata N, et al. Spontaneous perforation of pyometra presenting as acute abdomen and pneumoperitoneum mimicking those of gastrointestinal origin. *Case Rep Surg*. 2015; 2015: 548481. PubMed PMID: 25628913.
10. Lee SL, Huang LW, Seow KM, Hwang JL. Spontaneous perforation of a pyometra in a postmenopausal woman with untreated cervical cancer and "forgotten" intrauterine device. *Taiwan J Obstet Gynecol*. 2007; 46(4): 439-41. PubMed PMID: 18182356.

CORRESPONDING AUTHOR

Paulo Roberto Santana de Melo
Rua Artur Lavine, 123; Conquista; CEP: 45650-110; Ilhéus-BA, Brasil; e-mail: pmelo11@gmail.com.