

# Acroangiokeratitis (pseudo-Kaposi's sarcoma) in an HIV seropositive patient with syphilis and hepatitis C virus coinfection: clinical and dermatopathological features\*

Fred Bernardes Filho<sup>1</sup>  
José Augusto da Costa Nery<sup>1,3</sup>  
Bernard Kawa Kac<sup>1,5</sup>

Gustavo Martins<sup>2</sup>  
Cecília Vianna de Andrade<sup>3,4</sup>

DOI: <http://dx.doi.org/10.1590/abd1806-4841.20143036>

**Abstract:** Acroangiokeratitis is an angioproliferative disease usually related to chronic venous insufficiency, and it is considered a clinical and histological simulator of Kaposi's sarcoma (KS). Immunohistochemistry is the suitable method to differentiate between these two entities. It reveals the following immunostaining profile: immunopositivity with anti-CD34 antibody is restricted to the vascular endothelium in acroangiokeratitis, and diffuse in the KS (endothelial cells and perivascular spindle cells); immunopositivity with anti-HHV-8 only in KS cases. We report the case of an HIV seropositive patient without apparent vascular disease, who presented violaceous and brownish erythematous lesions on the feet, and whose histopathology and immunohistochemistry indicated the diagnosis of acroangiokeratitis.

**Keywords:** AIDS Serodiagnosis; Herpesvirus 8, human; Immunohistochemistry; Sarcoma, Kaposi; Syphilis, cutaneous

## INTRODUCTION

Acroangiokeratitis is an unusual angioproliferative disease related to chronic venous insufficiency, arteriovenous malformations or fistulas, paralyzed limbs, amputation stumps and thrombotic conditions.<sup>1,2</sup> It is generally characterized by purpuric macules, papules or plaques on the dorsum of the feet and the malleolus. It is considered a clinical and histological simulator of Kaposi's sarcoma (KS) and may present proliferation of endothelial cells, neof ormation of thick-walled vessels, frequently in lobular arrangement and surrounded by pericytes in the dermis, extravasation of red blood cells, deposition of hemosiderin pigment, dermal fibrosis, small thrombi in the lumen of blood vessels and a superficial perivascular infiltrate with lymphocytes, histiocytes and occasional plasma cells.<sup>1,2,3</sup>

Epidemic KS is the malignancy most commonly associated with acquired immunodeficiency syndrome (AIDS). It is usually aggressive and causes lesions in the skin and viscera, with variable progression.<sup>4</sup> It may occur as the first manifestation of AIDS, concomi-

tantly with other manifestations or late in the course of disease. The clinical presentation of KS is highly variable, generally beginning with purplish or brownish, erythematous, asymptomatic macules that later evolve into papules, plaques, nodules or tumor lesions.<sup>4,5</sup>

Histopathologic distinction between acroangiokeratitis and Kaposi's sarcoma is often difficult due to the overlapping of histological changes depending on the clinical stage of lesions.<sup>1</sup> Immunohistochemistry is a valuable method to differentiate between these two entities: in acroangiokeratitis CD34 expression is noted only in endothelial cells, whereas in Kaposi's sarcoma it is identified both in endothelial cells and perivascular spindle cells (Figure 1).<sup>1,2</sup> By using the antibody against the latent nuclear antigen 1 (LNA-1) of human herpes virus 8 (HHV-8) it is possible to detect the presence of the virus in the tumor cells - especially in the initial lesion -, and differentiate KS from its histological simulators.<sup>6</sup>

The early diagnosis of clinical lesions that simulate KS can be a challenge to dermatologists who treat

Received on 05.08.2013.

Approved by the Advisory Board and accepted for publication on 02.09.2013.

\* Study conducted at the Laboratório Anatómico lab - Rio de Janeiro (RJ), Brazil.

Conflict of interest: None

Financial funding: None

<sup>1</sup> Instituto de Dermatologia Professor Rubem David Azuly - Santa Casa da Misericórdia do Rio de Janeiro (IDPRDA - SCMRJ) - Rio de Janeiro (RJ), Brazil.

<sup>2</sup> Private clinic - Ituiutaba (MG), Brazil.

<sup>3</sup> Fundação Oswaldo Cruz (Fiocruz) - Rio de Janeiro (RJ), Brazil.

<sup>4</sup> Laboratório Fonte MD - Niterói (RJ), Brazil.

<sup>5</sup> Laboratório Anatómico lab - Rio de Janeiro (RJ), Brazil.

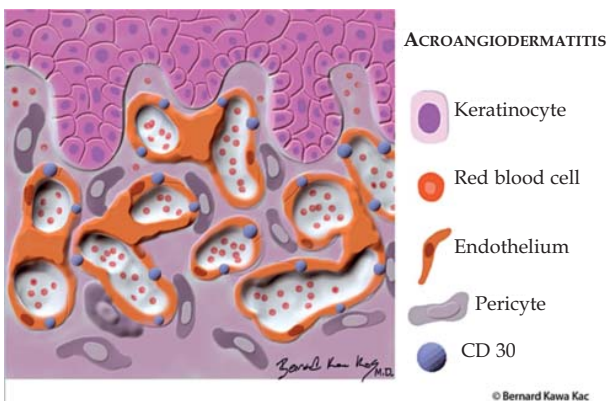
HIV seropositive patients. In this study, we present the case of a HIV seropositive patient with suspected early-stage KS. Immunohistochemistry of two of his lesions revealed immunonegativity for HHV-8 and CD34 immunopositivity restricted to endothelial cells.

**CASE REPORT**

A 41-year-old male patient newly diagnosed with coinfection of HIV-1, HIV-2 and hepatitis C virus and syphilis infection (VDRL 1:64 and reagent FTA-ABs) presented violaceous and brownish erythematous macules on the feet with 6 months of evolution. He denied comorbidities, as well as the use of medications and reported multiple sexual partners. The patient started antiretroviral therapy with tenofovir, lamivudine and efavirenz indicated by immunodeficiency (CD4 cell count: 152; viral load: 68,800).

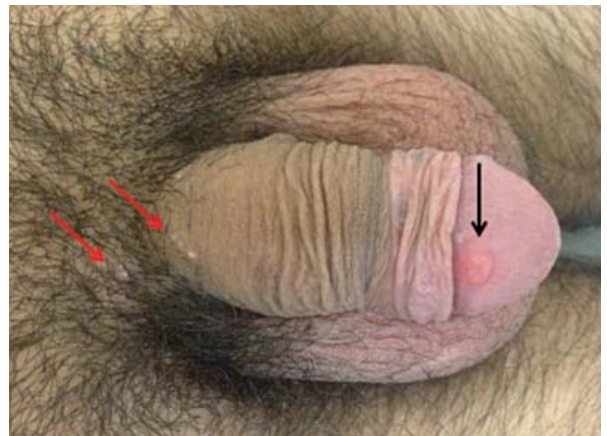Dermatological examination revealed diffuse erythematous rash, herpes zoster scar in the left T10-T12 dermatomes, bilateral cracks in the labial commissure, condylomatous vegetation at the base of the tongue, cervical, axillary and inguinal micropolyadenomegaly, presence of a single, painless ulcer with elevated borders and clean base in the glans penis and molluscum contagiosum lesions at the base of the penis, as well as bilateral palmar erythema and violaceous macules on the right foot and brownish macules on the left foot (Figures 2, 3 and 4).

Lumbar puncture was performed, and the result was: non-reactive VDRL; 100% mononuclear; 50mg% protein; 40 mg% glucose. The patient underwent upper digestive endoscopy and colonoscopy to determine the stage of disease. Both tests did not evidenced visceral KS.

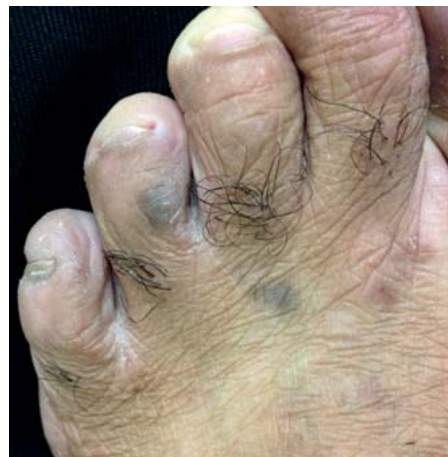

**FIGURE 1:** In acroangiokeratosis, initial histological changes such as proliferation of pericytes and endothelial cells, with formation of lymphatic vessels and capillaries, cracks in the papillary dermis and extravasation of erythrocytes are similar to Kaposi's sarcoma. The positivity for CD-30 is found only in the endothelium, unlike Kaposi's sarcoma, in which positivity is found both in the endothelium and the pericytes

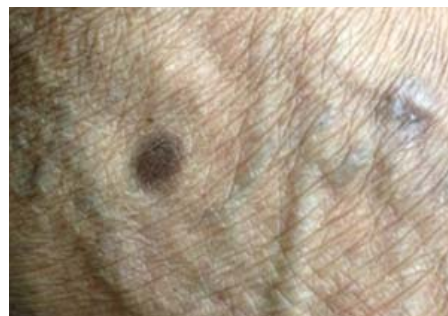The patient was treated with 3 doses of benzathine penicillin (total dose of 7,200,000 U IM) with an interval of 7 days between each dose. The chancre completely disappeared after the three doses of the medication. Biopsies of the lesions on both feet were obtained. Histopathological examination of the lesion on the left foot showed: presence of focal proliferation of rounded vessels, small caliber, real lumen, small-



**FIGURE 2:** Single, painless ulcer with elevated borders and clean base in the glans penis (black arrow); molluscum contagiosum lesions at the base of the penis: hypochromic umbilicated papules (red arrows)



**FIGURE 3:** Violaceous macules on the left foot



**FIGURE 4:** Brownish macule on the right foot

caliber, rounded vessels, covered by flattened endothelium in the papillary dermis (Figure 5). Histopathological examination of the lesion on the right foot revealed: preserved epidermis showing proliferation of capillaries and “glomeruloid” venules with light ectasia (Figure 6). Immunohistochemistry revealed cells with the following immunostaining profile: immunopositivity for anti-CD34 antibody only in endothelial cells and immunonegativity for anti-HHV-8 antibody (Figures 7 and 8). Histopathological findings of the two lesions indicate angiodermite de Favre et Chaix. Therefore, the association of the clinical data with the histological picture and negativity for HHV-8 favor the diagnosis of acroangiodermatitis.

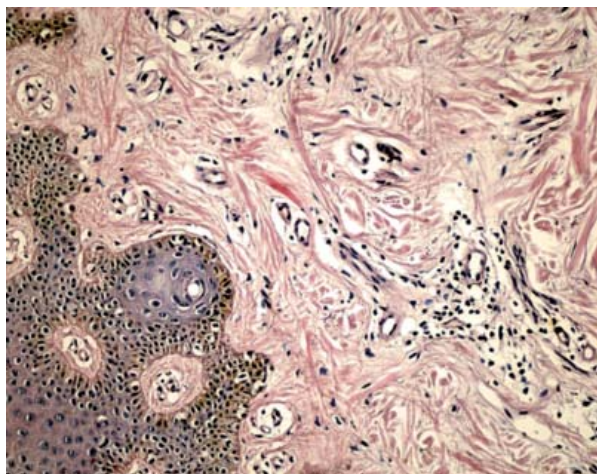


FIGURE 5: Focal proliferation of rounded vessels, small caliber, real lumen, small-caliber, rounded vessels, covered by flattened endothelium in the papillary dermis

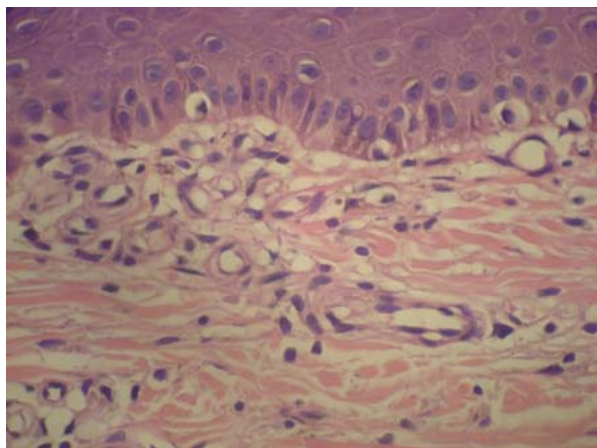


FIGURE 6: Glomeruloid proliferation of capillaries and venules with light ectasia

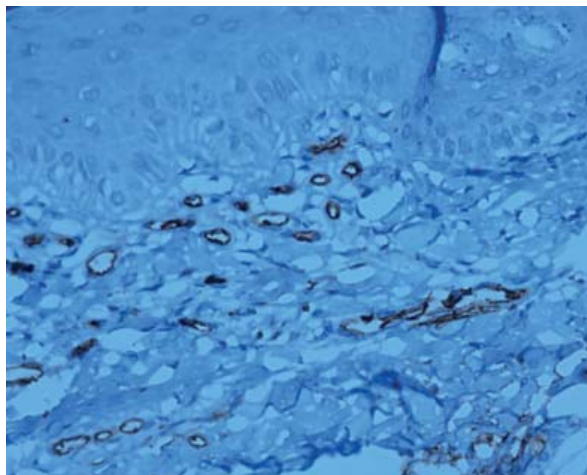


FIGURE 7: Immunopositivity with anti-CD34 antibody restricted to the vascular endothelium (40 x)

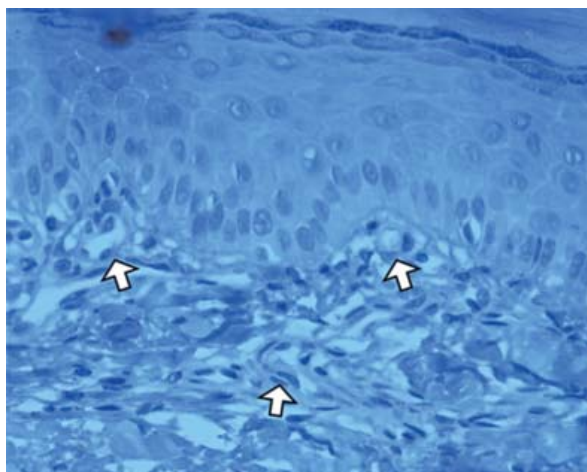


FIGURE 8: Vessel proliferation with mild vascular ectasia (arrows) and negative for HHV-8. (immunohistochemical reaction for HHV-8, 40x)

## DISCUSSION

The skin is the organ most frequently affected in patients with human immunodeficiency virus (HIV) infection. The spectrum of mucocutaneous manifestations of HIV infection includes: infectious processes (viruses, fungi, bacteria, parasites), proliferative disorders related to the disturbance of the immune system, neoplastic lesions, adverse reactions to antiretroviral therapy drugs (HAART) or other medications.<sup>7</sup> Some changes arise early in the onset of immunodeficiency or during immune reconstitution by HAART. Prevalence of skin problems during the course of infection may reach 95% and knowledge of these mucocutaneous manifestations is imperative to all dermatologists.<sup>7,8</sup>

With the advent of AIDS, there was a resurgence in the number of cases of syphilis. Risky sexual beha-

vivors continue to be the main responsible for this increase.<sup>9</sup> Many of the dermatological lesions in HIV seropositive patients only are found after careful examination and, in some cases, investigation of immunodeficiency should be mandatory. In our clinical practice, the overlapping of syphilis stages and molluscum contagiosum lesions in the genital region has been more frequently observed in HIV seropositive patients.

Because it makes possible to differentiate neoplastic lesions from their clinical and histological simulators at an early stage in HIV seropositive patients, immunohistochemistry has become a great

ally to routine techniques. The distinction between Kaposi's sarcoma and acroangiokeratitis is particularly important, because the first is an AIDS-defining neoplasia that requires treatment in order to avoid its dissemination, whereas the latter (acroangiokeratitis) is a non-tumoral, angioproliferative disorder whose treatment goal is to relieve its symptoms.

The fact that no evident vascular disorder was found questions the diagnosis of acroangiokeratitis. However, negativity for HHV-8, acral location, histological picture of the lesion are features that indicate this diagnosis. □

## REFERENCES

1. Cox NH, Piette WW. Acroangiokeratitis (of Mali). In: Burns T, Breathnach S, Cox N, Griffiths C, editors. *Rook's Textbook of Dermatology*. 8th. Oxford: Wiley Blackwell; 2010. p. 49.17-8.
2. Pimentel MI, Cuzzi T, Azeredo-Coutinho RB, Vasconcellos Éde C, Benzi TS, Carvalho LM. Acroangiokeratitis (Pseudo-Kaposi sarcoma): a rarely-recognized condition. A case on the plantar aspect of the foot associated with chronic venous insufficiency. *An Bras Dermatol*. 2011;86:S13-6.
3. Azulay RD, Kac BK, Cotta-Pereira G, Cunha AFL. Acroangiokeratitis (pseudo-Kaposi's sarcoma). *An Bras Dermatol*. 2004;79:193-7.
4. Aveleira JCR. Infecção pelo Herpesvirus 8. In: Lupi O, Lamy F, Semenovitch I editors. *Infecções por Herpesvirus*. Rio de Janeiro: AC Farmacêutica; 2010. p. 207-27.
5. Leão JC, Hinrichsen SI, Freitas BL, Porter SR. Herpes virus humano-8 e Sarcoma de Kaposi. *Rev Ass Med Brasil*. 1999;45:55-62.
6. Pereira PF, Cuzzi T, Galhardo MC. Immunohistochemical detection of the latent nuclear antigen-1 of the human herpesvirus type 8 to differentiate cutaneous epidemic Kaposi sarcoma and its histological simulators. *An Bras Dermatol*. 2013;88:243-6.
7. Porro AM, Yoshioka MCN. Dermatologic manifestations of HIV infection. *An Bras Dermatol*. 2000;75:665-91.
8. Zalla MJ, Su WP, Fransway AF. Dermatologic manifestations of human immunodeficiency virus infection. *Mayo Clin Proc*. 1992;67:1089-108.
9. Czelusta A, Yen-Moore A, Van der Straten M, Carrasco D, Tyring SK. An overview of sexually transmitted diseases. Part III. Sexually transmitted diseases in HIV-infected patients. *J Am Acad Dermatol*. 2000;43:409-32.

---

## MAILING ADDRESS:

*Fred Bernardes Filho*  
*Rua Marquês de Caxias, 9, Sobrado, Centro.*  
*24030-050. Niterói - RJ*  
*Brazil*  
*E-mail: f9filho@gmail.com*

How to cite this article: Bernardes Filho F, Martins G, Nery JAC, Andrade CV, Kac BK. Acroangiokeratitis (pseudo-Kaposi's sarcoma) in an HIV seropositive patient with syphilis and hepatitis C virus coinfection: clinical and dermatopathological features. *An Bras Dermatol*. 2014;89(5):792-5.