

## Unusual size, topography, and surgical resolution of an acquired fibrokeratoma\*

Leandro Fonseca Noriega<sup>1</sup>  
Nilton Di Chiacchio<sup>1</sup>

Nilton Gioia Di Chiacchio<sup>1</sup>  
Andreza Ventura<sup>1</sup>

DOI: <http://dx.doi.org/10.1590/abd1806-4841.20186828>

**Abstract:** Acquired fibrokeratoma is a rare benign skin tumor that usually manifests as a slow-growing solitary nodular lesion of the digits. We report a case of plantar acquired fibrokeratoma evidencing its atypical size and topography, in addition to the treatment with simple surgical excision followed by healing by second intention. Nondigital fibrokeratomas may occur in 18% of cases and rarely affect the palmoplantar region. These lesions are usually asymptomatic and show  $\geq 3$ cm in size at the time of diagnosis due to delayed diagnosis. Complete surgical excision is the treatment of choice, which is usually curative. In general, primary closure is chosen; however healing by second intention becomes an option in regions of difficult approach.

**Keywords:** Dermatologic surgical procedures; Neoplasms, fibroepithelial; Skin neoplasms

### INTRODUCTION

Acquired fibrokeratoma was initially described by Bart *et al.*<sup>1</sup> in 1968 under the term acquired digital fibrokeratoma, since the reported cases presented with digital lesions and resembled rudimentary supernumerary digits. This is a rare benign cutaneous tumor that affects mainly middle-aged adults, with a higher incidence in males, affecting the digits (finger or toe), especially in areas adjacent to the interphalangeal joints.<sup>2,5</sup>

Although it is postulated that repetitive trauma is the main triggering factor, its etiology remains unknown.<sup>3,5</sup> Qiao *et al.*<sup>6</sup> described a case with a probable association with cyclosporine use.

Although rare, topographies other than the digits can be affected.<sup>3,5</sup> These variants, according to Verallo *et al.*<sup>7</sup>, occur in approximately 18% of cases. Thus, many authors suggest the term acquired fibrokeratoma as an adequate nomenclature.<sup>3,5</sup>

The therapeutic approach includes complete excision, which can be performed using shaving or conventional surgery.

We report an unusual case of acquired fibrokeratoma in the plantar region, with a description of its clinical and histopathological findings. The therapeutic approach adopted was surgical excision followed by healing by second intention.

### CASE REPORT

We report the case of a 54-year-old male patient with a 10-year history lesion in the left plantar region. Initially, he presented with a slow-growing normochromic papule associated with local pain. The patient reported that, although he underwent excision of the lesion 5 years before in a different service, he experienced recurrence.

The patient denied previous perceptible traumas, comorbidities, and similar cases in the family. Dermatological examination revealed a slightly erythematous 4cm plaque in its largest diameter with hyperkeratotic and grooved surface in the medial plantar region (Figure 1). Palpation showed firm consistency. Physical examination revealed no other lesions.

Since incisional biopsy revealed findings suggestive of acquired fibrokeratoma, we performed complete excision of the lesion. The analysis of the surgical specimen corroborated the diagnosis for evidencing epidermis irregularly thickened by acanthosis and compact hyperkeratosis, proliferation of fibroblasts and thickened collagen fibers forming vertically oriented bundles in the papillary and reticular dermis, and blood vessels also proliferating and oriented in the same direction. We observed no cellular atypia (Figure 2).

Received on 15.12.2016.

Approved by the Advisory Board and accepted for publication on 23.03.2017.

\* Work performed at the Dermatology Department at Hospital do Servidor Público Municipal de São Paulo – São Paulo (SP), Brazil.

Financial support: None.

Conflict of interest: None.

<sup>1</sup> Dermatology Department at Hospital do Servidor Público Municipal de São Paulo – São Paulo (SP), Brazil.

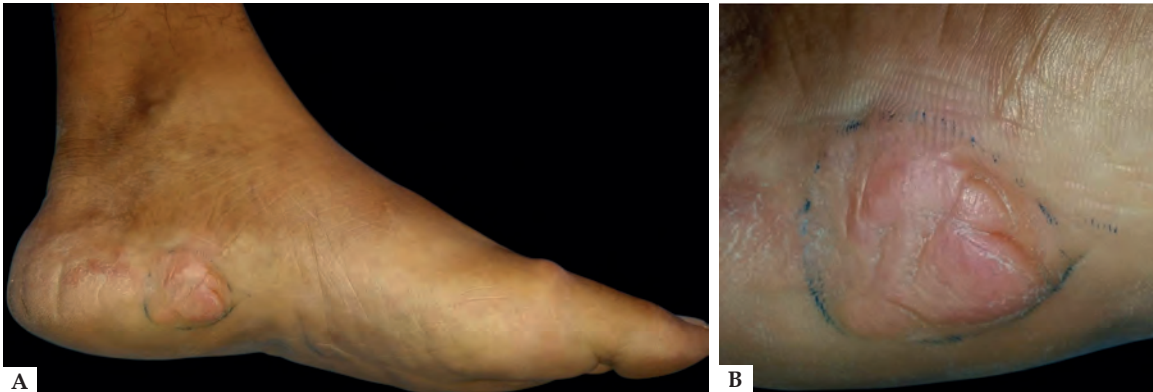
MAILING ADDRESS:

Leandro Fonseca Noriega

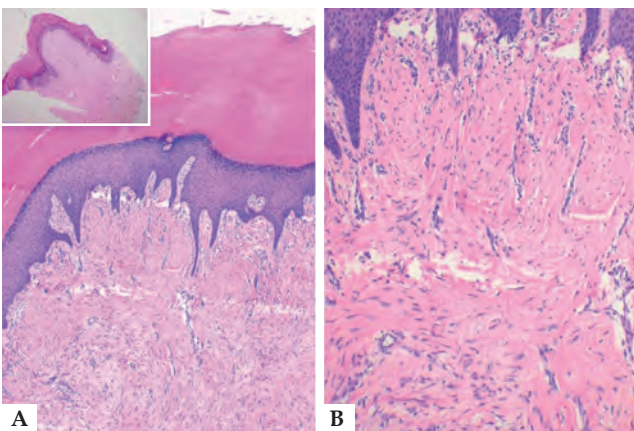
E-mail: leandronoriega@gmail.com

©2018 by Anais Brasileiros de Dermatologia

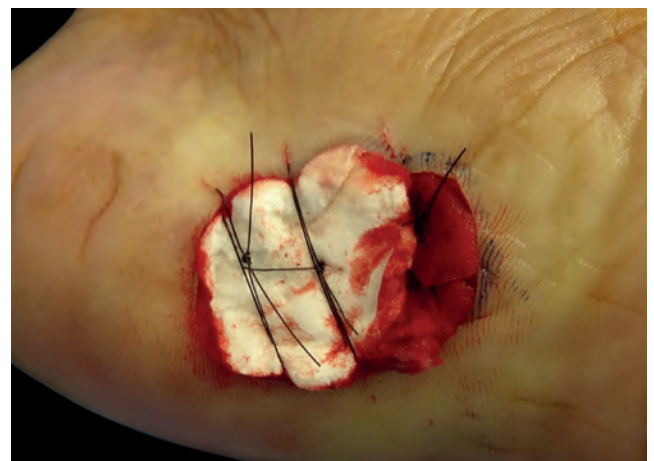




**FIGURE 1:**  
**A:** Slightly erythematous 4-cm plaque in its largest diameter with hyperkeratotic and grooved surface in the medial plantar region of the left lower limb.  
**B:** Detail of the lesion



**FIGURE 2:** **A:** Compact hyperkeratosis, irregular acanthosis and papillomatosis (Hematoxylin & eosin, X100). **B:** Proliferation of fibroblasts and thick collagen fibers forming vertically oriented bundles in the papillary dermis and in part of the reticular dermis. Note the presence of vertically oriented proliferated blood vessels (Hematoxylin & eosin, X200)



**FIGURE 3:** Immediate post-operative period, dressing with sterile absorbable gelatin sponge. Suture performed only to fix the sponge during the first two days

Due to the location of the lesion, we opted not to perform primary closure, keeping only a compressive dressing with a sterile absorbable gelatin sponge in the immediate and medium postoperative period (Figure 3). The patient received instructions about local care and was monitored periodically during second intention healing, showing good evolution. After 10 months, we observed only a scar tissue, with no signs of relapse.

**DISCUSSION**

Acquired fibrokeratoma usually manifests as a solitary, normochromic or slightly erythematous, sessile or pedunculated, cone- or nodule shaped lesion, with a smooth or hyperkeratotic surface.<sup>4,5,8</sup> Usually, it is a slow-growing, asymptomatic lesion, which shows the elevation of the skin surrounding the lesion as a characteristic sign, forming a collarette.<sup>4,8</sup>

Although the interphalangeal regions of the digits correspond to the most affected sites, the palmoplantar region can also be affected, as well as wrist, elbow, knee, ankle, and calcaneal re-

gion.<sup>4,5,8,9</sup> Our case was manifested with a slightly erythematous 4-cm plaque, with a hyperkeratotic and grooved surface, in the medial plantar region. Like most of the cases described in the literature, fibrokeratoma lesions originating in the plantar region tend to have a diameter greater than or equal to 3cm at the time of diagnosis.<sup>3,4,6,8</sup>

When the plantar region is affected, eccrine poroma, pyogenic granuloma, viral wart, callosity, and neurofibroma should be included as differential diagnoses.<sup>4,5</sup> The diagnosis is confirmed by histopathology demonstrating connective tissue cell proliferation, with predominance of thick, compact and oriented collagen fibers along the longitudinal axis of the lesion (that is, vertically).<sup>4,8,10</sup> The overlying epidermis reveals acanthosis and hyperkeratosis. Therefore, acquired fibrokeratomas are fibroepithelial tumors.<sup>3,4,8</sup>

Complete surgical excision is the treatment of choice and is usually curative.<sup>3,5</sup> In cases of early diagnosis, shaving excision should be considered.<sup>4</sup> Larger lesions should be treated by conventional surgery with direct primary closure or with the aid of flaps.<sup>3,5</sup> In our case, we opted for conventional surgical excision followed by

healing by second intention, with good evolution.

For those reasons, the diagnosis of acquired fibrokeratoma should be remembered, even when the lesion is located in regions other than the digits. Plantar lesions, due to the local cutaneous pe-

culiarity, can show difficulties of surgical reconstruction. Therefore, healing by second intention is an option with good aesthetic and functional results. □

#### REFERENCES

1. Bart RS, Andrade R, Kopf AW, Leider M. Acquired digital fibrokeratomas. Arch Dermatol. 1968;97:120-9.
2. Kint A, Baran R, De Keyser H.. Acquired (digital) fibrokeratoma. J Am Acad Dermatol. 1985;12:816-21.
3. Bron C, Noël B, Panizzon RG. Giant fibrokeratoma of the heel. Dermatology. 2004;208:271-2.
4. Zakopoulou N, Bokotas C, Frangoulis M, Karypidis D, Hatzolou E, Papadopoulos O. Giant tumour of the heel: acquired fibrokeratoma. Clin Exp Dermatol. 2009;34:605-6.
5. Baykal C, Buyukbabani N, Yazganoglu KD, Saglik E. Acquired digital fibrokeratoma. Cutis. 2007;79:129-32.
6. Qiao J, Liu YH, Fang K. Acquired digital fibrokeratoma associated with ciclosporin treatment. Clin Exp Dermatol. 2009;34:257-9.
7. Verallo VV. Acquired digital fibrokeratomas. Br J Dermatol. 1968;80:730-6.
8. de Freitas PM, de Sb Xavier MH, Pereira GB, Rochael MC, de Oliveira Cortes JL, Quevedo LP, . Acquired fibrokeratoma presenting as a giant pedunculated lesion on the heel. Dermatol Online J. 2008;14:10.
9. Frydman AF, Mercer SE, Kleinerman R, Yanofsky VR, Birge MB. Acquired fibrokeratoma presenting as multiple plantar nodules. Dermatol Online J. 2010;16:5.
10. Longhurst WD, Khachemoune A. An unknown mass: the differential diagnosis of digit tumors. Int J Dermatol. 2015;54:1214-25.

**How to cite this article:** Noriega LF, Di Chiacchio NG, Di Chiacchio N, Ventura A. Unusual size, topography and surgical resolution of an acquired fibrokeratoma. An Bras Dermatol. 2018;93(1):126-8.