

Conflicts of interest

None declared.

References

1. Islam PS, Chang C, Selmi C, Generali E, Huntley A, Teuber SS, et al. Medical complications of tattoos: a comprehensive review. *Clin Rev Allergy Immunol*. 2016;50:273–86.
2. Simunovic C, Shinohara MM. Complications of decorative tattoos: recognition and management. *Am J Clin Dermatol*. 2014;15:525–36.
3. De Cuyper C. Complications of cosmetic tattoos. *Curr Probl Dermatol*. 2015;48:61–70.
4. Monk E, Shalita A, Siegel DM. Clinical applications of non-antimicrobial tetracyclines in dermatology. *Pharmacol Res*. 2011;63:130–45.
5. Valbuena MC, Sánchez L, Franco VE, Jiménez HD. Sarcoid granulomatous reaction in tattoos: report of two cases. *An Bras Dermatol*. 2017;92:129–32.

Tamires Ferri Macedo *, Simone Perazzoli , Renan Rangel Bonamigo , Renata Heck 

Service of Dermatology, Sanitary Dermatology Outpatient Clinic, Secretaria de Saúde do Estado do Rio Grande do Sul, Porto Alegre, RS, Brazil

* Corresponding author.

E-mail: tamiresfmacedo@gmail.com (T.F. Macedo).

Received 10 June 2021; accepted 9 August 2021

Available online 27 April 2023

<https://doi.org/10.1016/j.abd.2021.08.019>

0365-0596/ © 2023 Sociedade Brasileira de Dermatologia.

Published by Elsevier España, S.L.U. This is an open access article under the CC BY license (<http://creativecommons.org/licenses/by/4.0/>).

Segmental hypopigmented acneiform nevus with *FGFR2* gene mutation[☆]



Dear Editor,

Segmental acneiform nevus associated with mutations of Fibroblast Growth Factor Receptor 2 (*FGFR2*) was first reported by Munro and Wilkie.¹ Very few similar cases were reported under different names making this disorder confusing. Here, the authors report a new case with a missense mutation in the *FGFR2* gene and summarized the features of this specific entity.

A 13-year-old Chinese boy presented with a segmental hypopigmented patch on his left abdomen and back following the Blaschko line since birth. Since the age of 10, comedones, scattered red papules, pustules, and nodules developed on the hypopigmented patch (Fig. 1A-B). Dilated follicular ostia with keratin plug, less pigmented terminal hairs with abnormal curled growth pattern, and follicle-centered hypomelanosis were identified under the Dermoscopy examination (Fig. 1C). During early childhood the patient had a minor delay in mental development and an attention deficit disorder, but no solid evidence of mental deficiency was found when he presented. The patient's general health status, magnetic resonance imaging scan, skeletal X-Ray, and routine laboratory examinations were normal. Their family history was unremarkable.

Venous blood was taken from the patient and his parents, and skin biopsies from the lesional and normal skin of the patient were performed. Histological examination showed dilated plugged follicular infundibula and perifollicular lymphohistiocytic infiltrate (Fig. 1D). Sanger sequencing of *FGFR2* (NM_022970) detected the heterozygous mutation c.758C>G in exon 7 in the affected skin (Fig. 1E) which was neither present in unaffected skin nor in the lymphocytes

from him and his parents. The sequence alteration represents a somatic mosaic mutation leading to a Pro253Arg amino acid change (CCT253CGT).

Few similar cases have been reported under different names (Table 1). A patient with mosaic *FGFR2* mutation (p.Ser252Trp) showed similar clinical symptoms.² Kiritisi et al.³ reported a severe case in a patient presenting with multiple segments involved. Ma et al.⁴ described a similar case but not confirmed by gene investigation. In addition, some documented nevus comedonicus cases with hypopigmentation may be the same disease.⁵

Acneiform lesions are the primary feature of this entity. *FGFR2* mutation in keratinocytes could induce the hypercornification of the pilosebaceous duct and inflammatory response.² The p.Pro253Arg mutation is located in the highly conserved linker region of *FGFR2* and leads to ligand-dependent *FGFR2* activation *in vivo* due to a conformational change that increases ligand-binding affinity.³ Extensive acneiform lesions, and depigmentation of hair, skin and eyes have been described in Apert syndrome in which two-thirds of patients exhibit a germline *FGFR2* mutation.⁶ The acneiform lesions responded to treatment with isotretinoin 20 mg daily like those in Apert syndrome.^{3,6}

The presence of early-onset hypopigmentation is another persistent characteristic feature reported in almost all published cases except the first case in which whether there was pigmentation change was not mentioned. It could be caused by the failure of melanosome transfer from melanocytes to keratinocytes or by elevated IL-1 α -mediated postinflammatory hypopigmentation.²

Based on clinical and molecular data of these published cases, here, the authors propose that 'segmental hypopigmented acneiform nevus with *FGFR2* mutation' might be a more comprehensive description for this specific entity. In addition, the authors suggest any atypical nevus comedonicus with a feature of hypopigmentation and/or inflammatory lesion should consider this disorder and bear in mind that postzygotic mosaicism for a genetic disease such as Apert syndrome can also affect the gonads, thus resulting in a risk of transmission to offspring.⁶

[☆] Study conducted at the Shanghai General Hospital, Shanghai, China.

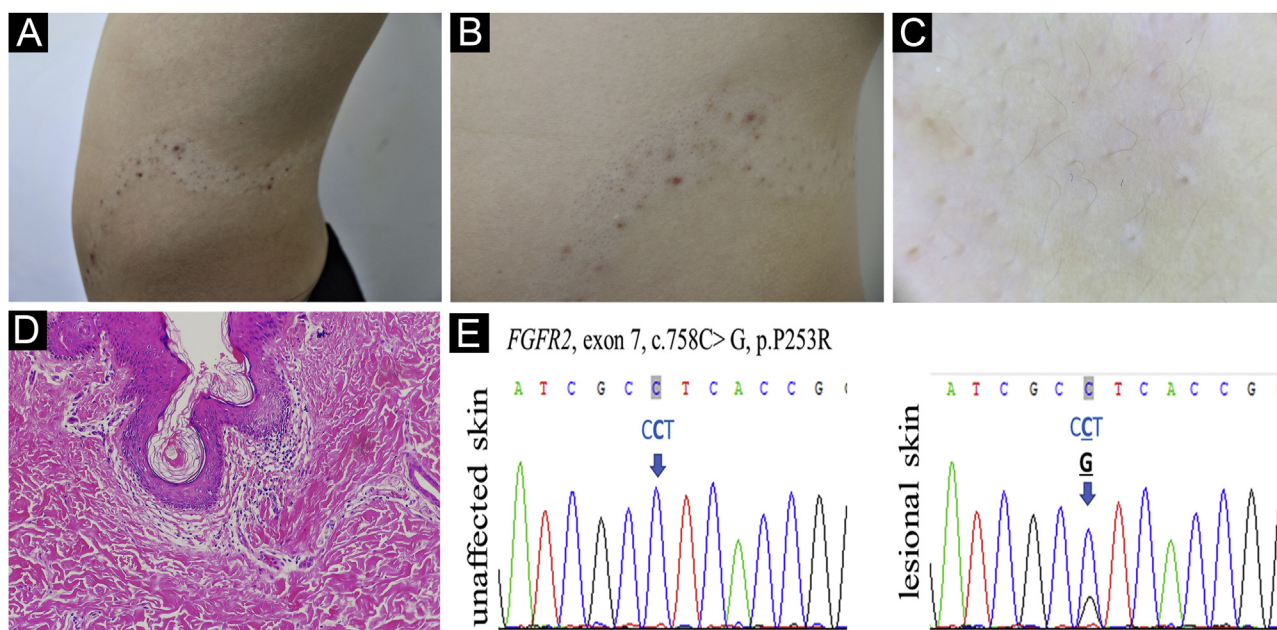


Figure 1 (A) Acneiform nevus on hypopigmentation patch following the Blaschko line. (B) Detailed comedones, inflammatory papules and nodules. (C) Follicular plug, curled hairs, and follicle-centered hypomelanosis by Dermoscopy, $\times 10$. (D) Dilated plugged follicular infundibula and perifollicular lymphohistiocytic infiltrate (Hematoxylin & eosin, $\times 100$). (E) *FGFR2* DNA sequence of the acneiform nevus and contralateral unaffected skin of the patient is shown. The heterozygous somatic mutation is indicated by the arrow

Table 1 Main features of published cases of a segmental acneiform nevus with hypopigmentation

Reference	Age at onset	Age at diagnosis	Sex	Distribution of lesions	Morphology of lesions	Mutation
1	12	14	Male	Single segmental (left arm)	Mostly comedones with scattered inflammatory papules	<i>FGFR2</i> mutation (p.Ser252Trp)
2	10	15	Male	Multiple segmental (right chest, trunk, shoulder, and arm)	Multiple comedones, inflammatory papules and pustules with hypopigmentation	<i>FGFR2</i> mutation (p.Ser252Trp)
3	1	12	Male	Multiple segmental (left and right sides of chest, trunk, shoulders, arms, and right face)	Multiple comedones, inflammatory papules, pustules, nodules, scars with hypopigmentation	<i>FGFR2</i> mutation (p.Pro253Arg)
Ours	1	13	Male	Single segmental (left abdomen and back)	Multiple comedones and inflammatory papules, pustules, nodules with hypopigmentation	<i>FGFR2</i> mutation (p.Pro253Arg)
4	1	25	Male	Single segmental (right chest and back)	Mostly comedones with scattered inflammatory papules with hypopigmentation	NA

Financial support

None declared.

Authors' contributions

Yongyi Xie: Contribution with data collection and interpretation; preparation and writing of the manuscript; manuscript review.

Baoyi Liu: Contribution with data collection and interpretation; preparation and writing of the manuscript; manuscript review.

Zhouwei Wu: Approval of the final version of the manuscript; manuscript review.

Conflicts of interest

None declared.

Acknowledgments

The authors thank the patient and his family. The authors also thank Dr. Ming Li from Xinhua hospital, Shanghai Jiaotong university for their expert consultation.

References

1. Munro CS, Wilkie AO. Epidermal mosaicism producing localized acne: somatic mutation in FGFR2. *Lancet*. 1998;352:704–5.
2. Melnik BC, Vakilzadeh F, Aslanidis C, Schmitz G. Unilateral segmental acneiform naevus: a model disorder towards understanding fibroblast growth factor receptor 2 function in acne? *Br J Dermatol*. 2008;158:1397–9.
3. Kiritsi D, Lorente AI, Happle R, Wittel JB, Has C. Blaschko line acne on pre-existent hypomelanosis reflecting a mosaic FGFR2 mutation. *Br J Dermatol*. 2015;172:1125–7.
4. Ma H, Xu Q, Zhu G, Su X, Yin S, Lu C, et al. Unilateral keratosis pilaris occurring on linear hypopigmentation patches: a new variant of keratosis pilaris in an Asian? *J Dermatol*. 2015;42:437–8.
5. Torchia D, Schachner LA, Izakovic J. Segmental acne versus mosaic conditions with acne lesions. *Dermatology*. 2012;224:10–4.
6. Steglich EMB, Steglich RB, Melo MM, Almeida HL Jr. Extensive acne in Apert syndrome. *Int J Dermatol*. 2016;55:e596–8.

Yongyi Xie ^{a,b}, Baoyi Liu ^{a,b}, Zhouwei Wu ^{a,b,*}

^a Department of Dermatology, Shanghai General Hospital, Shanghai, China

^b Department of Dermatology, Shanghai Jiao Tong University School of Medicine, Shanghai, China

* Corresponding author.

E-mail: zhouwei.wu@shgh.cn (Z. Wu).

Received 1 August 2021; accepted 23 September 2021

Available online 12 May 2023

<https://doi.org/10.1016/j.abd.2021.09.021>

0365-0596/ © 2023 Published by Elsevier España, S.L.U. on behalf of Sociedade Brasileira de Dermatologia. This is an open access article under the CC BY license (<http://creativecommons.org/licenses/by/4.0/>).

Umbilical lichen planus induced by nivolumab[☆]



Dear Editor,

Skin adverse events are the most common side effects under anti-PD1 immunotherapy. They usually develop early in the course of treatment and do not require interruption.¹ However, alternative clinical presentations may be observed.^{1,2} The authors encourage you to report them as they may improve knowledge of both, drugs and disease. Hence, the authors present an unusual case of lichen planus (LP) in the umbilicus after the fifteenth dose of nivolumab.

A 77-year-old Caucasian female presented with a 3-month history of a red, scaly, itchy, asymmetrical patch located at the umbilicus (Fig. 1). The patch had developed over a few days, persisted since, and no other lesions were found upon complete mucocutaneous examination. Under dermoscopy, white streaks on a violaceous background could be observed (Fig. 2). The patient had a past personal history of metastatic melanoma under treatment with nivolumab 240 mg every two weeks until the date. She started it 20

months prior to the appearance of the umbilical patch. A 4 mm punch biopsy was performed.

Histology showed hyperkeratosis and cytooid bodies with a bandlike inflammatory cell infiltrate composed of lymphocytes, histiocytes, and occasional eosinophils in the papillary dermis (Fig. 3). The features favored a diagnosis of LP.³ Serologies for VHB and VHC were negative. She has been pre-

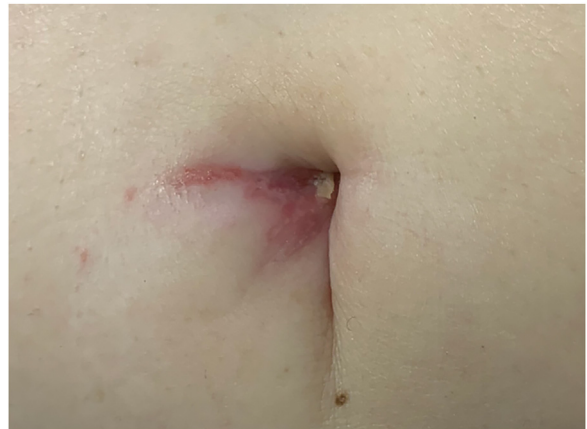

Fig. 1 A single violaceous patch with a fine reticulate pattern of dots and lines (Wickham's striae) on the umbilicus

[☆] Study conducted at the Hospital Universitario de la Princesa, Madrid, Spain.