

Treatment consists of surgical excision, with margins ranging from 1 cm to large resections, depending on the histopathology of the tumor.<sup>1,3</sup> Radiotherapy and chemotherapy have been described as alternative or adjuvant treatments.<sup>1,3</sup> To reduce the risk of recurrence, the evaluation of the margins with Mohs micrographic surgery is the procedure of choice,<sup>1,3,4</sup> as well as the close follow-up of these patients.<sup>1,3</sup>

## Financial support

None declared.

## Authors' contributions

Andrea Abê Pereira: Critical review of the literature; drafting and editing of the manuscript; approval of the final version of the manuscript; design and planning of the study.

Jéssica Lüders Bueno: Critical review of the literature; approval of the final version of the manuscript; design and planning of the study; drafting and editing of the manuscript.

Ana Leticia Boff: Drafting and editing of the manuscript; collection, analysis and interpretation of data; critical review of the manuscript.

Paulo Ricardo Martins Souza: Approval of the final version of the manuscript; design and planning of the study; drafting and editing of the manuscript; collection, analysis and interpretation of data; intellectual participation in the propaedeutic and/or therapeutic conduct of the studied cases; critical review of the literature; critical review of the manuscript.

## Conflicts of interest

None declared.

## References

1. Satyaprakash AK, Sheehan DJ, Sangüeza OP. Proliferating trichilemmal tumors: a review of the literature. *Dermatol Surg.* 2007;33:1102–8.
2. Peryassu MA, Peryassu BC, Peryassu RC, Piñeiro-Maceira J, Ramos-E-Silva M. Proliferating trichilemmal tumor: a case on the nose of a 70-year-old man. *Case Rep Dermatol.* 2013;5:248–53.
3. Tierney E, Ochoa MT, Rudkin G, Soriano TT. Mohs' micrographic surgery of a proliferating trichilemmal tumor in a young black man. *Dermatol Surg.* 2005;31:359–63.
4. Sharma R, Verma P, Yadav P, Sharma S. Proliferating trichilemmal tumor of scalp: benign or malignant, a dilemma. *J Cutan Aesthet Surg.* 2012;5:213–5.
5. Park BS, Yang SG, Cho KH. Malignant proliferating trichilemmal tumor showing distant metastases. *Am J Dermatopathol.* 1997;19:536–9.

Andrea Abê Pereira <sup>a,b,\*</sup>, Jéssica Lüders Bueno <sup>a,b</sup>, Ana Leticia Boff <sup>a,b</sup>, Paulo Ricardo Martins Souza <sup>a,b</sup>

<sup>a</sup> *Department of Dermatology, Universidade Federal de Ciências da Saúde de Porto Alegre, Porto Alegre, RS, Brazil*

<sup>b</sup> *Department of Dermatology, Santa Casa de Misericórdia de Porto Alegre, Porto Alegre, RS, Brazil*

\* Corresponding author.

E-mail: [andrea.abetm@gmail.com](mailto:andrea.abetm@gmail.com) (A.A. Pereira).

Received 16 September 2021; accepted 11 November 2021  
Available online 3 August 2023

<https://doi.org/10.1016/j.abd.2021.11.015>

0365-0596/ © 2023 Published by Elsevier España, S.L.U. on behalf of Sociedade Brasileira de Dermatologia. This is an open access article under the CC BY license (<http://creativecommons.org/licenses/by/4.0/>).

## Recurrence of psoriasis on the resolution sites left with lentiginous pigmented patches after TNF inhibitor therapy<sup>☆</sup>



Dear Editor,

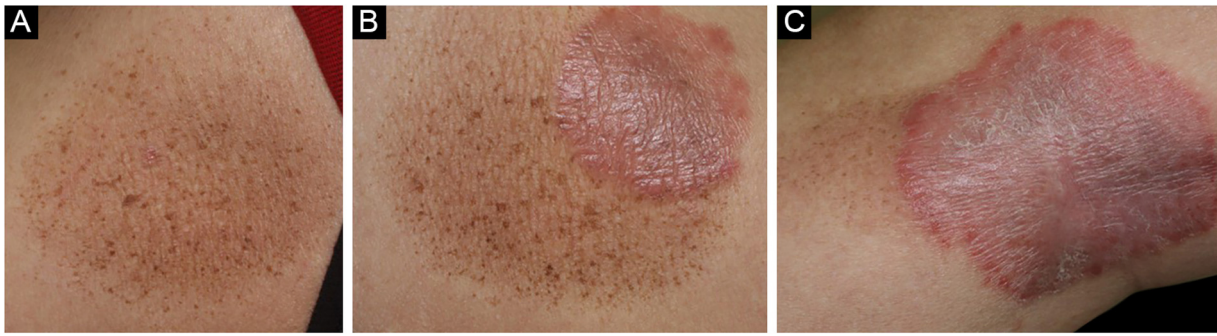
To date, several cases of multiple lentiginous in resolved psoriasis lesions have been reported. Herein, we describe a rare case of psoriasis that resolved leaving multiple small lentiginous patches in the lesions after successful treatment with a Tumor Necrosis Factor (TNF) inhibitor. Moreover, a recurrence of psoriasis was observed in the pigmentary patches.

A 55-year-old male was diagnosed with psoriasis vulgaris 6 years previously and had been treated with topical corticosteroid ointment. Joint pain appeared on the bilateral fingers, wrists, and ankles 3 years previously, and he

received systemic therapy with adalimumab (subcutaneous injection of 80 mg, and 40 mg thereafter every other week). Both cutaneous and joint manifestations responded well to adalimumab. Psoriasis Activity and Severity Index (PASI) score was reduced from 6.0 to 0 (PASI clear), and also, he was relieved from joint pain. After the complete disappearance of psoriasis, pigmentation emerged. However, during maintenance therapy with adalimumab, cutaneous psoriasis relapsed 7 months later, but without recurrence of joint pain. Physical examination showed multiple brownish plaques on the lower extremities. A few psoriatic plaques were observed in some, but not all, of the resolved lesions (Fig. 1A–C). In one of the lesions, psoriatic lesions appeared within the pigmented macule and spread beyond the pigmented macule (Fig. 1C).

There are several cases of psoriatic plaques that were treated with biologics such as TNF inhibitors, Interleukin-17 (IL-17) inhibitors, IL-12/23 inhibitors, T-cell inhibitors, and phosphodiesterase 4 inhibitors, and left lentiginous lesions in the resolved area.<sup>1–4</sup> Previous studies have shown that inflammatory cytokines such as TNF- $\alpha$  and IL-17 can

<sup>☆</sup> Study conducted at the Fukushima Medical University, Fukushima, Japan.



**Figure 1** (A) A number of small brownish lentiginous patches appeared after improvement of psoriasis. (B) Psoriatic plaques were observed within part of the pigimentary macule. (C) Psoriasis occurred within the pigimentary macule and spread beyond the pigimentary macule

inhibit melanocyte growth, downregulate pigmentation-related gene expression, and render tyrosinase activity.<sup>4</sup> Therefore, inhibitors of those cytokines may cause hyperpigmentation in susceptible individuals' skin type and genetic predisposition. It is known that psoriasis arises in the resolved areas, which is considered to be an isomorphic response of Köbner. In the present case, scaly erythematous lesions recurred on some of the pre-existing lesions. The recurred psoriasis plaques did not perfectly but mostly correspond to the pre-existing areas. In another lesion, psoriasis initially recurred in the resolved areas and extended beyond the pigimentary macule. Previous studies showed that epidermal CD8<sup>+</sup> T-cells increased in the Köbner-positive psoriasis skin, and CD8<sup>+</sup> tissue Resident Memory T-cells (T<sub>RM</sub>) enriched in the resolved lesion preferentially produced IL-17 and IL-22 upon restimulation.<sup>5</sup> However, triggering factors that stimulate T-cell activation are currently unknown. One possible cause may be the decrease in the efficacy of TNF inhibitors on cutaneous psoriasis. Unfortunately, we could not compare the frequency of epidermal T<sub>RM</sub> on the non-lesional skin, improved skin with pigmentation, recurred psoriasis lesion in the resolved area, and recurred psoriasis lesion in the previously non-lesional area, because the patient refused biopsy. Further studies are necessary to elucidate the mechanism of lentiginous pigmentation after the improvement of psoriasis and the role of T<sub>RM</sub> in such conditions.

### Financial support

None declared.

### Author' contributions

Toshiyuki Yamamoto: Study conception and planning; data collection, analysis and interpretation; management of studied cases; preparation and writing of the manuscript; approval of the final version of the manuscript.

### Conflicts of interest

None declared.

### References

1. Dogan S, Atakan N. Multiple lentigines confined to psoriatic plaques induced by biologic agents in psoriasis therapy: a case and review of the literature. *Cutan Ocul Toxicol.* 2015;34:262–4.
2. Maria PS, Valenzuela F, Morales C, Fuente RD, Cullen R. Lentiginous eruption in resolving psoriasis plaques during treatment with ixekizumab: a case report and review of the literature. *Dermatol Rep.* 2017;9:7079.
3. Lee EB, Reynolds KA, Pithadia DJ, Wu JJ. Appearance of lentigines in psoriasis patient treated with guselkumab. *Dermatol Online J.* 2019;25:13.
4. Zhang S, Liang J, Tian X, Zhou X, Liu X, Chen X, et al. Secukinumab-induced multiple lentigines in areas of resolved psoriatic plaques: a case report and literature review. *Dermatol Ther.* 2021;34:e15048.
5. Yamamoto T, Kurihara K, Tokura Y. Tissue resident memory T cells in the lesional and unlesional psoriatic skin on the scar. *J Dermatol.* 2020;47:e210–1.

Toshiyuki Yamamoto 

Department of Dermatology, Fukushima Medical University, Fukushima, Japan

E-mail: [toyamade@fmu.ac.jp](mailto:toyamade@fmu.ac.jp)

Received 23 February 2022; accepted 13 April 2022

Available online 23 June 2023

<https://doi.org/10.1016/j.abd.2022.04.015>

0365-0596/ © 2023 Sociedade Brasileira de Dermatologia.

Published by Elsevier España, S.L.U. This is an open access article under the CC BY license (<http://creativecommons.org/licenses/by/4.0/>).