

Communication

[Comunicação]

Peracute bovine mastitis caused by *Klebsiella pneumoniae*

[Mastite bovina hiperaguda causada por *Klebsiella pneumoniae*]

M.G. Ribeiro, R.G. Motta, A.C. Paes, S.D. Allendorf, T. Salerno, A.K. Siqueira,
M.C. Fernandes, G.H.B. Lara

Faculdade de Medicina Veterinária e Zootecnia – UNESP
Caixa Postal 560
18618-000 – Botucatu, SP

The causal agents involved in bovine mastitis were conventionally classified in contagious and environmental pathogens. Fungi, algae, and coliforms are the most important environmental pathogens in the etiology of bovine mammary infections (Santos and Fonseca, 2007).

Escherichia coli, *Klebsiella pneumoniae*, and *Enterobacter aerogenes* are recognized as the most common coliforms in bovine mastitis (Bannerman et al., 2003). Exposure of uninfected quarters to coliform pathogens occur primarily between milkings and, secondarily, during milking procedures and dry period. Coliform pathogens are essentially opportunistic. Their primary reservoir in transmission is represented by feces, water, soil, sawdust, and shavings that contaminate the canal of the teats (Radostits et al., 2007).

These enteric Gram-negative microorganisms possess lipopolysaccharides (LPS) – so called endotoxins – in the outer layer of the cell wall, which in contact with the immune system lead to liberation of potent pro-inflammatory mediators (cytokines). Mammary glands of the domestic animals are extremely sensible to LPS (Munoz et al., 2006). The endotoxins induce to severe changes in vascular permeability, and increase of somatic cells in mammary gland and milk, resulting in edema, depression, toxemia, and severe peracute or acute clinical signs of mastitis. Occasionally, complication of coliform mastitis occurs when pathogens disseminate from the mammary gland to systemic circulation, leading

the animal to severe clinical signs of bacteremia and/or septicemia (Radostits et al., 2007).

Classically, coliform mastitis is characterized by clinical signs in two weeks prior to lactation or in the first weeks of the dry period. Fever, agalactia, anorexia, depression, rumen static, and dehydration are the most common clinical signs of peracute coliform mastitis in cattle (Ribeiro et al., 2006; Santos and Fonseca, 2007). The mammary gland presents marked swelling and regions containing signs of congestion and necrosis. Mammary secretion is watery to serous, containing small flakes and great increase of neutrophils. These high migrations of neutrophils into the affected quarter have been associated to severe leukopenia and neutropenia in bovine coliform mastitis (Radostits et al., 2007).

Treatment of coliform mastitis involves aggressive fluid therapy, associated to antimicrobial and anti-inflammatory drugs. However, some cows die within six to 24 hours of the onset of the clinical signs due to endotoxic and/or septicemic complications (Santos e Fonseca, 2007). The present report describes a peracute bovine mastitis caused by *Klebsiella pneumoniae*.

A five-year-old Holstein cow was referred to the veterinary hospital presenting history of peracute clinical signs of mastitis and toxemia, three weeks prior to calving. The owner informed that the disease had a sudden onset of agalactia, one week after a prolonged rainy period. The animal

came from a small dairy farm. It was raised on pasture and was milked once a day. In the clinical exam, fever (41°C), polypnea, anorexia, rumen static, shivering, tachycardia, and depression were observed. The specific exam of udder revealed positive *Tamis* test (clinical mastitis) in the right posterior quarter, and scored 3+ in *California Mastitis Test* (subclinical

mastitis) in the others three quarters. In the palpation, the quarters presented cold, swollen, painful and warm and the mammary lymph node was enlarged. Discolored areas (red and blue-blackish) were observed in right posterior quarter (Fig. 1). Milk secretion showed watery in all quarters, containing flakes in right the posterior quarter.

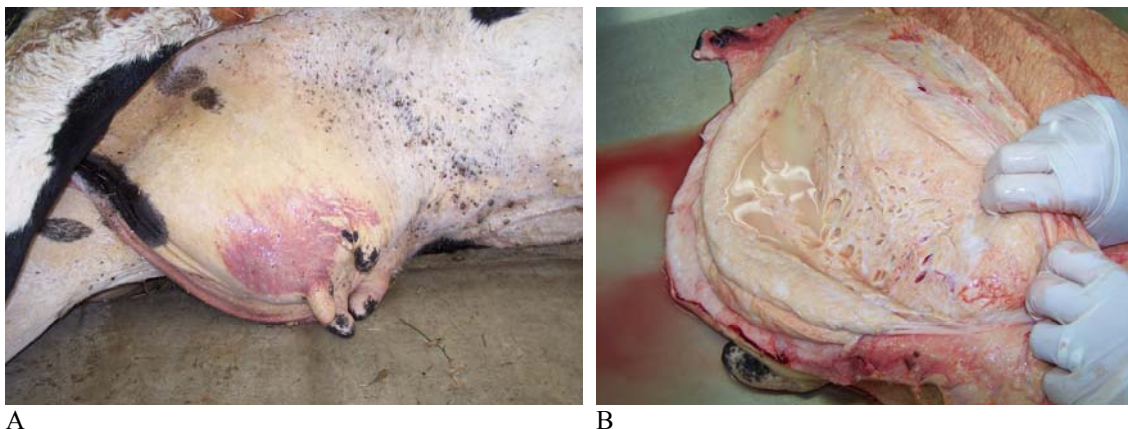


Figure 1. A) Severe peracute mastitis in cattle caused by *Klebsiella pneumoniae* infection; B) Detail of mammary lesion at necropsy, showing congestion of parenchyma and watery milk. Botucatu, SP, Brazil.

Milk samples from the four quarters were aseptically obtained and submitted to microbiological culture on defibrinated bovine blood agar (5%) and MacConkey agar, aerobically incubated, at 37°C for 72h. The isolated microorganisms were classified based on macro and microscopical morphology (Gram stain), culture characteristics, and biochemical profile (Krieg and Holt, 1984; Quinn et al., 1994). Circular, non-hemolytic, grayish colonies were observed on bovine blood agar after 24h of incubation; while on MacConkey agar, numerous mucoid, brilliant, pink (lactose-positive) colonies were observed. Biochemical tests performed from the lactose-positive colonies enabled to classify the microorganism as *Klebsiella pneumoniae*. The microorganism was submitted to *in vitro* antimicrobial susceptibility test using the disk diffusion method (Bauer et al., 1966). It showed susceptibility to cefalexin (30µg), gentamicin (10µg), and ceftriaxona (30µg), and resistance to ampicillin (10µg), tetracyclin (30µg), and florfenicol (30µg).

In virtue of severe clinical signs, emergency treatment was attempted using commercial cephalosporin (30mg/kg, 24h, IV), flunixin

meglumin (1.1mg/kg, 24h, SC), and aggressive intravenous fluid therapy. In despite of therapy, 12 hours after the onset of the treatment, euthanasia was recommended due to worse of general conditions and evolution of clinical signs. Pneumonia and edema pulmonar, renal and hepatic congestions, enlargement and congestion of mammary lymph nodes, and congestion of mammary parenchyma, containing watery secretion were observed at necropsy (Fig. 1). Fragments of lungs, liver, kidneys, and mammary gland were submitted to microbiological culture. *K. pneumoniae* was isolated from fragments of the mammary gland and lungs, showing same antimicrobial profile of that strain isolated from milk.

E. coli, *K. pneumoniae*, and *E. aerogenes* are worldwide recognized as the predominant coliform microorganisms involved in bovine mastitis (Radostits et al., 2007). In Brazil, *E. coli* is considered the most common bacteria from environmental origin, described in clinical bovine mastitis (Ribeiro et al., 2006; Santos and Fonseca, 2007), including peracute and toxemic cases, with lethal evolution (Ribeiro et al., 2002). However, little attention has been dispended in

order to evaluate the occurrence and severity of *K. pneumoniae* in the etiology of toxemic and/or septicemic bovine mammary infections in Brazil.

K. pneumoniae has been reported in different countries in serious outbreaks or in isolated cases of peracute or acute bovine mastitis, predominantly in the first two weeks of lactation. The mammary infections frequently are associated with wood or sawdust contamination used in the environment of the animals (Wenz et al., 2001; Munoz et al., 2006; Sampimon et al., 2006; Radostits et al., 2007). In the present report, the animal did not have contact with sawdust or wood products in the environment. However, severe clinical signs were observed three weeks prior to calving, after a prolonged rainy period. The excess of rain and deficient management of organic material certainly increased humidity and fecal material in the environment, which probably were the primary sources of the microorganism for transmission to the mammary gland. From a similar way, others studies have also hypothesized that fecal sheeding of *K. pneumoniae* and excess of organic material in the environment between milking would be associated with bovine mastitis by that microorganism (Munoz et al., 2006). Thus, the adoption of hygienic measures in order to avoid the accumulation of organic material in the environment between milkings, in the milking-room facilities, and fecal contamination of wood or sawdust used as bed for dairy animals, tends to control the occurrence of (per)acute coliform mastitis, including that caused by *K. pneumoniae*.

It is well established in the literature that clinical signs of coliform mastitis occurs, in part, due to severe systemic inflammatory response, upregulated by endotoxins (LPS) liberation. The mammary gland of domestic animals is highly sensible to LPS. These lipopolysaccharide molecules present in the outer membrane of Gram-negative bacteria – including *K. pneumoniae* – are liberated during multiplication and/or death of the bacteria (Bannerman et al., 2003). In the present case, the peracute severe clinical signs observed in the animal certainly were determined by the LPS liberation from the outer surface membrane of *K. pneumoniae* isolated from the mammary gland, leading to an exaggerated inflammatory response. The microbiological identification of *K. pneumoniae* from lungs of the present case causing bacteremia, with consequent systemic complications (septicemia), has also been described in similar cases (Wenz et al., 2001), and probably contributed for the severity of clinical signs and worse of corporal condition, that led to the euthanasia of the animal.

The present report reinforce the need of rapid diagnosis of etiology in peracute coliform mastitis in cattle for establishment of effective treatment protocol and control measures, in order to avoid the toxemic and/or septicemic complications, generally associated to poor prognosis. Furthermore, it alerts to the importance of *K. pneumoniae* as severe coliform pathogen in the etiology of peracute bovine mastitis in Brazil.

Keywords: cattle, milk, mastitis, *Klebsiella pneumoniae*, endotoxin, lipopolysaccharide

RESUMO

Relata-se a ocorrência de graves sintomas de mastite hiperaguda em vaca, causada por Klebsiella pneumoniae, na terceira semana de lactação. Descrevem-se aspectos epidemiológicos, sintomas clínicos, procedimentos de diagnóstico microbiológico, conduta terapêutica e medidas de controle.

Palavras-chave: bovino, leite, mastite, Klebsiella pneumoniae, endotoxina, lipopolissacarídeo

REFERENCES

BANNERMAN, D.D.; PAAPE, M.J.; HARE, W.R. et al. Increased levels of LPS-binding protein in bovine blood and milk following bacterial lipopolysaccharide challenge. *J. Dairy Sci.*, v.86, p.3128-3137, 2003.

BAUER, A.W.; KIRBY, W.M.M.; SHERRIS, J.C. et al. Antibiotic susceptibility testing by a standardized single disk method. *Am. J. Clin. Pathol.*, v.45, p.493-496, 1966.

- KRIEG, N.R.; HOLT, J.G. (Eds). *Bergey's Manual of Systematic Bacteriology*. London: Williams & Wilkins. p.984, 1984.
- MUNOZ, M.A.; AHLSTROM, C.; RAUCH, B.J. et al. Fecal shedding of *Klebsiella pneumoniae* by dairy cows. *J. Dairy Sci.*, v.89, p.3425-3430, 2006.
- QUINN, P.J.; CARTER, M.E.; MARKEY, B. et al. (Eds). *Clinical veterinary microbiology*. London: Wolfe, 1994. 648p.
- RADOSTITS, O.M.; GAY, C.C.; HINCHCLIFF, K.W. et al. (Eds). *Veterinary medicine: A textbook of the diseases of cattle, horses, sheep, pigs, and goats*. 10.ed. Philadelphia: Saunders, 2007. p.673-762.
- RIBEIRO, M.G.; COSTA, E.O.; LEITE, D.S. et al. Fator necrosante citotóxico em *Escherichia coli* isolada de mastite clínica bovina. *Arq. Bras. Med. Vet. Zootec.*, v.54, p.648-650, 2002.
- RIBEIRO, M.G.; COSTA, E.O.; LEITE, D.S. et al. Fatores de virulência em linhagens de *Escherichia coli* isoladas de mastite bovina. *Arq. Bras. Med. Vet. Zootec.*, v.58, p.724-731, 2006.
- SAMPIMON, O.C.; SOL, J.; KOCK, P.A. An outbreak of *Klebsiella pneumoniae* mastitis. *Tijdschr Diergeneeskd*, v.131, p.2-4, 2006.
- SANTOS, M.V.; FONSECA, L.F.L. (Eds.) *Estratégias para controle de mastite e melhoria da qualidade do leite*. São Paulo: Manole, 2007. 314p.
- WENZ, J.R.; BARRINGTON, G.M.; GARRY, F.B. et al. Bacteremia associated with naturally occurring acute coliform mastitis in dairy cattle. *J. Am. Vet. Med. Assoc.*, v.219, p.976-981, 2001.