

EXPERIMENTAL INDUCTION OF STEATOSIS IN DIFFERENT TISSUES AFTER THE INGESTION OF A CARBOHYDRATE-RICH DIET: effect on the liver, on the heart and on indicators of oxidation

Nadia Juliana Beraldo Goulart Borges **HAUBERT**¹, Gilberto João **PADOVAN**¹, Sérgio **ZUCOLOTO**², Hélio **VANNUCCHI**¹ and Julio Sergio **MARCHINI**¹

ABSTRACT - Context – The western dietary pattern is characterized by a high calorie intake with a high proportion of simple sugars. This diet is associated with comorbidities such as hepatic fat deposition and is possibly related to non-alcoholic fatty liver disease. **Objective** – To evaluate the capacity of a hyperglucidic diet to induce steatosis in adult male Wistar rats. After the administration of a carbohydrate-rich diet, we also evaluated the presence of hepatic and cardiac steatosis and the levels of intrinsic antioxidants in the liver. **Methods** – Forty-six eutrophic adult male Wistar rats were used and 10 of them were chosen, at random, to serve as controls, while the remaining ones formed the experimental group. Control animals received the standard ration offered by the animal house and the experimental group received the hyperglucidic diet. The diets were offered for 21 days and, at the end of this period, tissue samples were collected for analysis of indicators of oxidative stress (malondialdehyde, and reduced glutathione) and of vitamin E. The animals were then sacrificed by decapitation and their viscera were removed for analysis of liver and heart fat. **Results** – The hyperglucidic diet used induced hepatic fat deposition, with lipid vacuoles being detected in 83% of the livers analyzed by histology. No lipid vacuoles were observed in the heart. Malondialdehyde and reduced glutathione levels remained unchanged when the animals were submitted to the hyperglucidic diet, probably because there was no liver development of fibrosis or inflammation. In contrast, the levels of vitamin E (antioxidant) were reduced, as confirmed in the literature for steatotic animals. **Conclusion** – The hyperglucidic diet induced hepatic steatosis. In the heart there was an increase in fat content, although no histological changes were observed. These alterations cannot be explained by the presence of malondialdehyde or reduced glutathione (indicators of oxidation), since the values were similar in the groups studied. However, a significant reduction of vitamin E was observed in the experimental group. **HEADINGS** – Fatty liver. Dietary carbohydrates. Oxidative stress. Rats.

INTRODUCTION

Animal studies have helped understand the physiopathogenic and therapeutic mechanisms of non-alcoholic fatty liver disease. Several animal models are currently available for the study of this condition and of hepatic steatosis, although none of them can fully reproduce the essential components of the human disease^(5, 13, 18). An efficient model for the induction of steatosis is the offer of choline- and methionine-deficient animals to small-sized animals^(18, 26).

However, in view of the eating habits of the western population based on a rapid absorption carbohydrate-rich diet, and especially the habits of the obese patient, the objective of the present study was to offer a high content of simple carbohydrates diet^(4, 15), to eutrophic

rats and to determine lipid deposition in the liver. In addition to the liver and in view of the importance of cardiac events, we also determined the presence of fatty deposition in cardiac muscle and related it to indicators of oxidation. Thus, the hypothesis of the present study was that a high sucrose intake would result in steatosis histologically determined both in the liver and in the heart, with an increase of the indicators of oxidation.

METHODS

The study was approved by the Ethics Committee for the Use of Experimental Animals of the Faculty of Medicine of Ribeirão Preto, USP, Ribeirão Preto, SP, Brazil.

¹Departamento de Clínica Médica/Nutrologia; ²Departamento de Patologia e Medicina Legal, Faculdade de Medicina de Ribeirão Preto, Universidade de São Paulo – SP, Brazil
Correspondence: Prof. Julio Sérgio Marchini - Avenida Bandeirantes, 3900 - 14049-900 - Ribeirão Preto, SP, Brazil. Email: jsmarchini@fmrp.usp.br

The study was conducted on adult male Wistar rats weighing 250-320 g at the beginning of the experiment, provided by the Central Animal House of the Ribeirão Preto Campus of USP and later maintained in the Animal Facilities of the Department of Internal Medicine, Faculty of Medicine of Ribeirão Preto, USP. The animals were housed in individual cages with a feeder and drinking bottle and kept on a 12 hour light-12 hour dark cycle in rooms with natural ventilation at a controlled temperature of $24 \pm 2^\circ\text{C}$. To determine weight evolution, the animals were weighed in the morning between 8:00 and 9:00 hours once a week with a Filizola[®] electronic scale with a maximum capacity of 1.5 kg and graduated in 1 g.

Ten animals were selected, at random, from an initial lot of 46 and used as controls (Gcon) and the remaining animals were considered to be the experimental group (Gexp).

Gcon animals received the standard ration of the animal house, with a single lot of the same ration being used throughout the experiment. This diet consisted of 42% carbohydrate (ground whole corn), 22% casein, 4% soy oil, and 0.2% choline, plus a salt and vitamin mix, methionine and lysine.

Gexp animals received the hyperglucidic diet, prepared in the Animal Facilities of the Department of Internal Medicine, Faculty of Medicine of Ribeirão Preto, USP, consisting of 70% sucrose (refined sugar), 16% casein, 8% soy oil, 5% vitamin mix, 1% salt mix, and 0.2 choline.

All animals received the daily amounts of vitamin and minerals recommended by the AIN 93⁽²³⁾ and the respective diets for 21 days and ration intake was checked daily.

The animals were sacrificed by decapitation. Laparotomy for removal of the viscera was started with a median longitudinal incision reaching the abdominal cavity. Liver and heart samples were then collected for histology and for the analysis of indicators of oxidative stress according to a technique previously established in the Animal Facilities of the Department of Internal Medicine.

Blood was collected and centrifuged at 2500 rpm/10 min for plasma separation and plasma was stored at -70°C . Liver samples from the right lobe and heart samples were weighed, wrapped with aluminum foil and stored frozen in liquid nitrogen at -70°C for later analysis.

Lipid peroxidation was determined by measuring thiobarbituric acid reactive substances in plasma using a DU[®] 640 spectrophotometer (Beckman, USA), and by the reaction of thiobarbituric acid with malondialdehyde (MDA)⁽²⁵⁾. Tissue analyzes of antioxidants such as vitamin E and reduced glutathione were performed by reverse high performance liquid chromatography⁽⁷⁾, using a model LC10A[®] Shimadzu instrument with an isocratic system, and a model SPD[®] - 10AV Shimadzu instrument equipped with a UV-visible spectrophotometric detector, and by the determination of the sulfhydryl group with the Ellman reagent⁽²⁴⁾, respectively.

Fragments of the heart and of the right liver lobe were collected, cut into slices of approximately 3 mm in thickness, fixed in 4% buffered formol, dehydrated, cleared, and embedded in paraffin⁽¹⁷⁾. Total liver and heart fat was analyzed by the Soxhlet MA[®]-487/6/250 method for fat extraction⁽⁶⁾. The paraffin-embedded fragments were then cut into 4 μm thick

sections and stained with Harris hematoxylin and eosin for the semi-quantitative determination of hepatic steatosis with a standard light microscope (400x). Steatosis was classified according to the quantity of hepatocytes containing fat vacuoles as follows: absence of steatosis, involvement of 25% of the hepatocytes, involvement of up to 50%, of 75% and of more than 75%^(3,9).

Data are reported as means \pm SD. Differences were calculated using appropriate tests for parametric and non-parametric samples. The Kolmogorov-Smirnov test was used to determine parametric or non-parametric distribution of the data and differences were determined by the Tukey-Kramer test in the former case and by the Steel-Dwass test in the latter.

RESULTS

During the 21 days of the hyperglucidic diet, the animals of the experimental group ingested a total amount of food similar to that ingested by the control group (Figure 1). Figure 2 shows that the animals also gained weight in a similar manner, with no difference between Gcon and Gexp. The weight at the end of the experiment was greater than the initial weight in both groups, with no difference between Gcon and Gexp.

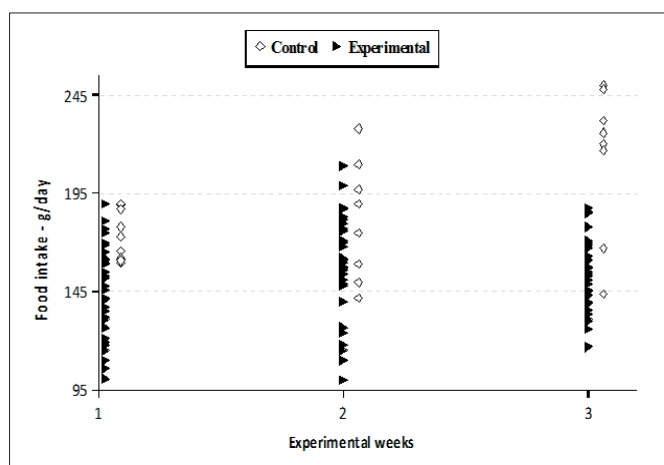


FIGURE 1. Food intake of the control and experimental groups during the 3 weeks of the experiment. The experimental group received a hyperglucidic diet (70% carbohydrates) and the same energy value as the control group

Table 1 presents the morphometric and biochemical results obtained from groups. No difference in total liver or heart mass was detected between groups. However, at the end of the experiment, the percentage of fat was increased in both organs.

In the liver no difference in MDA or reduced glutathione was observed at the end of the experiment. On the other hand, vitamin E levels were reduced, by about 50%, at the end of the experiment.

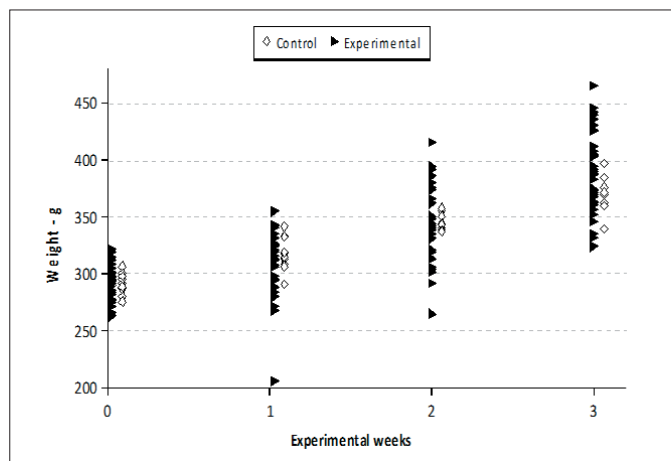


FIGURE 2. Weight evolution (g) of the control and experimental groups during the 3 weeks of the experiment. The experimental group received a hyperglucidic diet (70% carbohydrates) and the same energy value as the control group

TABLE 1. Organ weight, fat proportion and indicators of oxidation at the end of the period with a 70% hyperglucidic diet

		Control	Experimental
Liver	Total mass- g	9.6 ± 0.1	11.6 ± 1.1
	Fat mass- g	0.5 ± 0.2	1.1 ± 0.4
	% fat	5.2	9.7*
	Vitamin E - μmol/g tissue	149 ± 90	73 ± 42*
	MDA† - ηmol/mg protein	0.15 ± 0.02	0.18 ± 0.02
	GSH‡ - μmol/g protein	33 ± 6	23 ± 5
Heart	Total mass- g	1.20 ± 0.28	1.26 ± 0.08
	Fat mass- g	0.07 ± 0.01	0.10 ± 0.03
	% fat	5.8	7.9*

*P<0.05 compared to control. † Malondialdehyde. ‡ Reduced glutathione

It was possible to show macroscopically and histologically that fat deposition occurred in the liver (Figures 3 and 4) of 83% of Gexp animals. In the heart, despite the detection

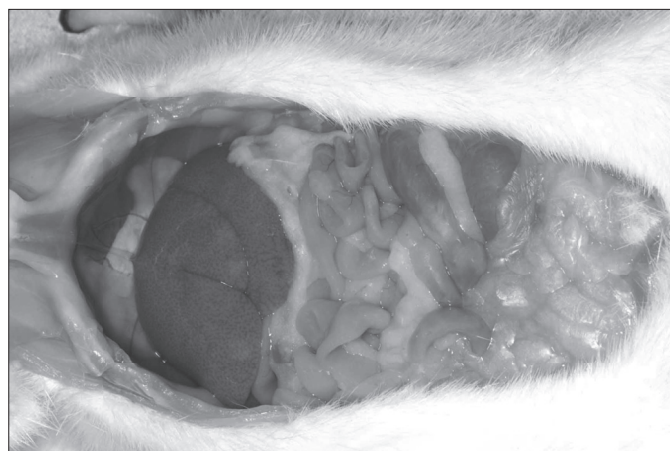


FIGURE 3. Macroscopic liver steatosis induced in Wistar rats by a hyperglucidic diet. The experimental group received a hyperglucidic diet (70% carbohydrates) and the same energy value as the control group

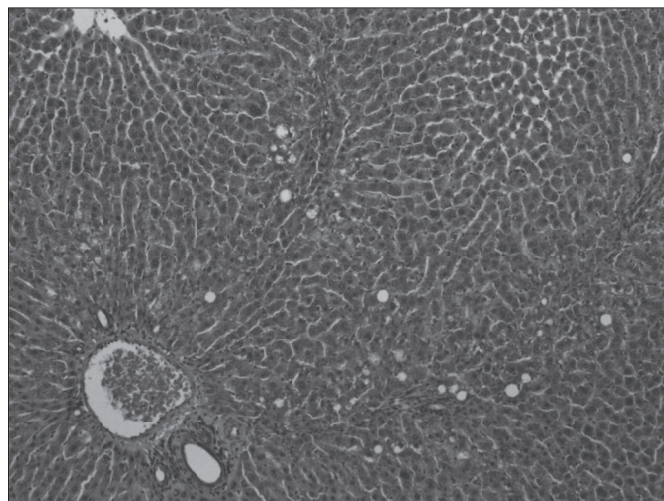


FIGURE 4. HE-stained histological liver section revealing lipid vacuoles (macro- and microgutticular steatosis). Magnification: 100x. The experimental group received a hyperglucidic diet (70% carbohydrates) and the same energy value as the control group

of a greater proportion of fat at the end of the experiment, it was not possible to show an increased presence of lipids histologically (Figure 5).

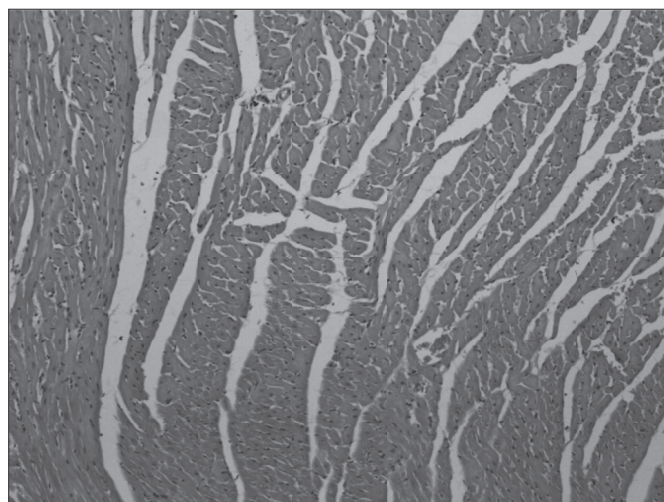


FIGURE 5. HE-stained histological cardiac section with no evidence of lipid vacuoles. Magnification: 100x. The experimental group received a hyperglucidic diet (70% carbohydrates) and the same energy value as the control group

DISCUSSION

In the present study, a hyperglucidic diet (70% sucrose) administered for 21 days induced steatosis as revealed by the lipid vacuoles detected by histological analysis in most of the animals. A similar finding has been reported even with diets containing 50% carbohydrates administered for 21 days⁽²⁾.

According to the theory about the development of hepatic steatosis⁽¹⁴⁾ related to a hyperglucidic diet, there is increased fatty acid synthesis in the hepatocytes, exceeding their capacity of metabolization and export, perhaps due the lipogenic action of insulin⁽¹⁾. Although insulin levels were not determined in the present study, they would be expected to be increased as a secondary result of the hyperglucidic diet. The hyperinsulinemia may, therefore, favor lipid deposition in tissues, including the liver. In the heart, although it was not possible to characterize fat deposition histologically, there was a greater tissue proportion of lipids. The study of the presence of fat in cardiac tissue is justified by the fact that lipid accumulation directly injures the myocardium⁽¹⁶⁾. Studies with animal models of obesity have revealed that intramyocardial accumulation of triacylglycerols provokes cardiac dysfunction such as non-ischemic dilated cardiomyopathy⁽¹⁶⁾. In the associated presence of higher plasma triacylglycerides level, it may be suggested that, if the duration of the experiment had been longer, it would have also been possible to demonstrate histologically lipid deposition in the heart.

On the other hand, factors related to oxidative stress⁽⁸⁾ determined in hepatic tissue (MDA and reduced glutathione) did not differ in Gexp and Gcon, although there was a significant reduction of vitamin E at the end of the experiment. There were no technical conditions that would permit us to determine these indicators in cardiac muscle. This fact may have occurred because hepatic fibrogenesis probably was not present, as observed by histological analysis. Oxidative stress occurring within a

context of triacylglyceride deposition inside the hepatocytes appears to be important for the progression of steatosis to steatohepatitis and fibrosis^(19, 20). Several studies have demonstrated that reactive oxygen species are increase in steatohepatitis, whereas antioxidant (vitamin E and glutathione) levels are decreased^(10, 11).

The mechanism by which the carbon molecules originating from carbohydrates (glucose, fructose, lactose etc.) are transformed into fatty acids is called *de novo* lipogenesis, which is highly active in rodents⁽²¹⁾. The expression of some enzymes that participate in this mechanism such as acetyl-CoA carboxylase and fatty acid synthase may be increased. Thus, hyperglucidic diets considerably stimulate lipogenesis, increasing the expression of lipogenic enzymes and predisposing to an increased fatty acid supply for the liver^(12, 22).

In conclusion, the hyperglucidic diet induced hepatic steatosis. Fat levels increased in the heart, although no histological changes were observed. These changes cannot be explained by the presence of MDA or reduced glutathione (indicators of oxidation), since the values were similar in the groups studied. However, in the experimental group there was a significant reduction of vitamin E.

ACKNOWLEDGMENTS

We are grateful to the Animal House and the Laboratory of Nutrition of the Department of Internal Medicine, da FMRP-USP, to the nutritionist Sueli Gobbo, to FAPESP for financial support, and to CNPq.

Haubert NJBGB, Padovan GJ, Zucoloto S, Vannucchi H, Marchini JS. Esteatose experimental em diferentes tecidos induzida pela ingestão de dieta rica em carboidratos: efeito sobre o fígado, coração e indicadores do estresse oxidativo. *Arq Gastroenterol.* 2010;47(4):388-92.

RESUMO - Contexto – O padrão alimentar ocidental é caracterizado pela ingestão de dieta rica em açúcares simples. Esta alimentação é associada com comorbidades como, por exemplo, deposição de gordura no fígado e possivelmente relacionada com a esteatose hepática não-alcoólica. **Objetivo** – Avaliar a capacidade de uma alimentação hiperglicídica induzir esteatose em ratos Wistar adultos. Após administração de uma dieta rica em hidratos de carbono, foi avaliada a presença de esteatose hepática cardíaca e a presença de antioxidantes no fígado. **Métodos** – Quarenta e seis ratos Wistar adultos eutróficos foram utilizados no experimento. Destes, 10 animais escolhidos por meio de sorteio simples (ao acaso) foram considerados controles e os demais pertencentes ao grupo experimental. Os animais controles receberam, durante todo experimento dieta usual do biotério. Os animais do grupo experimental, durante 21 dias, receberam dieta com 70% de sacarose. Ao final os animais foram sacrificados por decapitação e suas vísceras (fígado e coração) analisada quanto ao teor de gordura. As amostras de tecido hepático foram também analisadas quanto ao teor de antioxidantes (malondialdeído e glutatona reduzida) e vitamina E. **Resultados** – A dieta hiperglicídica induziu a deposição de gordura no fígado, sendo os vacúolos lipídicos detectados em 83% das amostras no fígado (histologia). No coração foi detectado bioquimicamente aumento do percentual de gordura, sem a detecção de vacúolos lipídico por histologia. Os teores de malondialdeído e glutatona reduzida não foram diferentes entre os animais dos grupos controle e experimental. Por outro lado, os valores de vitamina E, no grupo experimental, foram significativamente inferiores ao do grupo controle. **Conclusão** – A dieta hiperglicídica induziu ao esteatose hepática. No coração houve maior deposição de lípidos, embora a histologia não tenha mostrado alterações. Esta deposição, tanto no coração como no fígado, não pode ser explicada pelos indicadores de oxidação utilizados. No entanto, foram observados baixos níveis de vitamina E, que pode estar associada a esta indução de esteatose, principalmente, hepática.

DESCRITORES – Fígado gorduroso. Carboidratos na dieta. Estresse oxidativo. Ratos.

REFERENCES

1. Axen KV, Axen K. Very low-carbohydrate versus isocaloric high-carbohydrate diet in dietary obese rats. *Obesity (Silver Spring)*. 2006;14:1344-52.
2. Bacon BR, Park CH, Fowell EM, McLaren CE. Hepatic steatosis in rats fed diets with varying concentrations of sucrose. *Fundam Appl Toxicol*. 1984;4:819-26.
3. Brunt EM, Ramrakhiani S, Cordes BG, Neuschwander-Tetri BA, Janney CG, Bacon BR, DiBisceglie AM. Concurrence of histologic features of steatohepatitis with other forms of chronic liver disease. *Mod Pathol*. 2003;16:49-56.
4. Carlos JV, Rolim S, Bueno MB, Fisber RM. Porcionamento dos principais alimentos e preparações consumidos por adultos e idosos residentes no município de São Paulo. *Rev Nutr*. 2008;21:383-91.
5. Dentin R, Benhamed F, Hainault I, Fauveau V, Fougelle F, Dyck JR, Girard J, Postic C. Liver-specific inhibition of ChREBP improves hepatic steatosis and insulin resistance in ob/ob mice. *Diabetes*. 2006;55:2159-70.
6. Feldsine P, Abeyta C, Andrews WH. AOAC International Methods Committee guidelines for validation of qualitative and quantitative food microbiological official methods of analysis. *J AOAC Int*. 2002;85:1187-200.
7. Gueguen S, Pirollet P, Leroy P, Guillaud JC, Arnaud J, Paille F, Siest G, Visvikis S, Hercberg S, Herbeth B. Changes in serum retinol, alpha-tocopherol, vitamin C, carotenoids, zinc and selenium after micronutrient supplementation during alcohol rehabilitation. *J Am Coll Nutr*. 2003;22:303-10.
8. Jordão AA, Zanuto ME, Domenici FA, Portari GV, Cecchi AO, Zucoloto, Vannucchi. Progression of lipid peroxidation measured as thiobarbituric acid reactive substances, damage do DNA and histopathological changes in the liver of rats subjected to a methionine-choline-deficient diet. *Basic Clin Pharmacol Toxicol*. 2009;105:150-5.
9. Kleiner DE, Brunt EM, Van Natta M, Behling C, Contos MJ, Cummings OW, Ferrell LD, Liu YC, Torbenson MS, Unalp-Arida A, Yeh M, McClullough AJ, Sanyal AJ. Design and validation of a histological scoring system for nonalcoholic fatty liver disease. *Hepatology*. 2005;41:1313-21.
10. Leclercq IA, Farrell GC, Field J, Bell DR, Gonzalez FJ, Robertson, GR. CYP2E1 and CYP4A as microsomal catalysts of lipid peroxides in murine nonalcoholic steatohepatitis. *J Clin Invest*. 2000;105:1067-75.
11. Lee KS, Buck M, Houglum K, Chojkier M. Activation of hepatic stellate cells by TGF alpha and collagen type I is mediated by oxidative stress through c-myc expression. *J Clin Invest*. 1995;96:2461-8.
12. Letexier D, Pinteur C, Large V, Frering V, Beylot M. Comparison of the expression and activity of the lipogenic pathway in human and rat adipose tissue. *J Lipid Res*. 2003;44:2127-34.
13. Lieber CS, Leo MA, Mak KM, Xu Y, Cao Q, Ren C, Ponomarenko A, DeCarli LM. Model of nonalcoholic steatohepatitis. *Am J Clin Nutr*. 2004;79:502-9.
14. Maio R, Dichi JB, Burini RC. Consequências nutricionais das alterações metabólicas dos macronutrientes na doença hepática crônica. *Arq Gastroenterol*. 2000;37:52-7.
15. Marcondelli P, Costa THM, Schmitz BAS. Nível de atividade física e hábitos alimentares de universitários do 3º ao 5º semestres da área de saúde. *Rev Nutr*. 2008;21:39-47.
16. McGavock JM, Victor RG, Unger RH, Szczepaniak LS. American College of Physicians and the American Physiological Society. Adiposity of the heart, revisited. *Ann Intern Med*. 2006;144:517-24.
17. Mandler MH, Kanel G, Govindarajan S. Proposal for a histological scoring and grading system for non-alcoholic fatty liver disease. *Liver Int*. 2005;25:294-304.
18. Nanji AA. Animal models of nonalcoholic fatty liver disease and steatohepatitis. *Clin Liver Dis*. 2004;8:559-74.
19. Oliveira CP, da Costa Gayotto LC, Tatai C, Della Bina BI, Janiszewski M, Lima ES, Abdalla DS, Lopasso FP, Laurindo FR, Laudanna AA. Oxidative stress in the pathogenesis of nonalcoholic fatty liver disease, in rats fed with a choline-deficient diet. *J Cell Mol Med*. 2002;6:399-406.
20. Oliveira CP, Coelho AM, Barbeiro HV, Lima VM, Soriano F, Ribeiro C, Molan NA, Alves VA, Souza HP, Machado MC, Carrilho FJ. Liver mitochondrial dysfunction and oxidative stress in the pathogenesis of experimental nonalcoholic fatty liver disease. *Braz J Med Biol Res*. 2006;39:189-94.
21. Parks EJ. Dietary carbohydrate's effects on lipogenesis and the relationship of lipogenesis to blood insulin and glucose concentrations. *Br J Nutr*. 2002;87:S247-53.
22. Polacow VO, Lancha Junior AH. Dietas hiperglicídicas: efeitos da substituição isoenergética de gordura por carboidratos sobre o metabolismo de lipídios, adiposidade corporal e sua associação com atividade física e com o risco de doença cardiovascular. *Arq Bras Endocrinol Metabol*. 2007;51:389-400.
23. Reeves PG, Nielsen FH, Fahey GC Jr. AIN-93 purified diets for laboratory rodents: final report of the American Institute of Nutrition ad hoc writing committee on the reformulation of the AIN-76A rodent diet. *J Nutr*. 1993;123:1939-51.
24. Sedlak J, Lindsay RH. Estimation of total, protein-bound, and nonprotein sulfhydryl groups in tissue with Ellman's reagent. *Anal Biochem*. 1968;25:192-205.
25. Svingen BA, Buege JA, O'Neal FO, Aust SD. The mechanism of NADPH-dependent lipid peroxidation. The propagation of lipid peroxidation. *J Biol Chem*. 1979;254:5892-9.
26. Zamin I Jr, Mattos AA, Mattos AZ, Migno E, Soares E, Perry ML. Modelo de esteatohepatite não-alcoólica com dieta deficiente em metionina e colina. *Arq Gastroenterol*. 2009;46:69-74.

Received:18/5/2010.
Accepted:30/6/2010.