Arq Neuropsiquiatr 2005;63(2-A):335-338

DISTAL POSTERIOR INFERIOR CEREBELLAR ARTERY ANEURYSM

Case report

Ricardo Ramina[1], Viviane Aline Buffon[2], Jerônimo Buzetti Milano[2], Erasmo Barros da Silva Jr[2], Kelly Cristina Bordignon[2]

ABSTRACT - The majority of posterior inferior cerebellar artery (PICA) aneurysms are usually found on the bifurcation of the vertebral artery (VA) - PICA junction. Aneurysms arising from more peripheral PICA segments named distal PICA aneurysm are uncommon. The major clinical manifestation is that of an intracranial bleeding and the site of hemorrhage is related to the PICA segment originating the aneurysm. Lesions originating from distal PICA segments, particularly those arising from the telovelotonsillar segment, are associated with hemorrhage extending into the ventricular system, mainly the IV ventricle. A case of a 50-year-old woman with sudden headaches and vomiting, and intraventricular hemorrhage (four ventricles) caused by an aneurysm of the telovelotonsillar segment of the PICA, is presented. No signs of subarachnoidal hemorrhage were found in the computerized tomography. The aneurysm was clipped and the patient presented a favorable outcome. Anatomical aspects and clinical series are reviewed.

KEY WORDS: intracranial aneurysm, posterior circulation, posterior inferior cerebellar artery, subarachnoid hemorrhage.

Aneurisma da artéria cerebelar posterior e inferior distal: relato de caso

RESUMO - A maioria dos aneurismas da artéria cerebelar posterior inferior (PICA) é geralmente encontrada na junção artéria vertebral (VA) - PICA. Aneurismas originando-se nos segmentos mais distais da PICA são considerados raros. A manifestação clínica em geral por hemorragia intracraniana, e o local desta está relacionado ao segmento que origina o aneurisma. Lesões localizadas em segmentos mais distais da PICA, em especial os originados do segmento telovelotonsilar, estão associados a hemorragias no sistema ventricular, particularmente no quarto ventrículo. Relatamos o caso de mulher de 50 anos de idade que desenvolveu quadro de cefaléia súbita e vômitos, com hemorragia nos quatro ventrículos, causada por ruptura de aneurisma localizado no segmento telovelotonsilar da PICA. Não havia sinais de hemorragia subaracnóidea na tomografia computadorizada de crânio. O aneurisma foi clipado e a paciente apresentou evolução favorável. Aspectos anatômicos e outras séries são revisados.

PALAVRAS-CHAVE: aneurismas intracranianos, circulação posterior, artéria cerebelar posterior inferior, hemorragia subaracnóidea.

Aneurysms of the posterior inferior cerebellar artery (PICA) are uncommon, complaining approximately 0.49% of all intracranial aneurysms[1] and 20% of the posterior fossa aneurysms[2]. The majority of them are localized at the vertebral artery (VA) PICA junction[3-5]. There are few large series of distal PICA aneurysms[6-7], with no more than 26 cases. These lesions are very rare, their anatomy is complex and the clinical features, outcome and treatment are not well understood. We report the case of a 50-year-old woman with intraventricular hemorrhage caused by hemorrhage of an aneurysm at the telovelotonsilar portion of the right PICA. The anatomy and clinical series are reviewed.

Anatomy – The PICA has the most complex, tortuous and variable course, as well as supplying area, of all cerebellar arteries[8]. In most cases, it arises from the VA at its intracranial portion (80-95% of cases)[9-10], passes laterally to the medulla and infe-

Instituto de Neurologia de Curitiba, Curitiba PR, Brasil: [1]Neurosurgeon, Chief of the Department of Neurosurgery; [2]Residents in Neurosurgery.

Received 28 July 2004, received in final form 14 September 2004. Accepted 5 November 2004.

Ricardo Ramina, M.D. - Department of Neurosurgery, Instituto de Neurologia de Curitiba - Rua Jeremias Maciel Perreto 300 - 81210-310 Curitiba PR - Brazil. E-mail: ramina@inc-neuro.com.br

riorly to the oliva, thus taking a posterior direction to the lobulo biventre of the cerebellum[11]. An extracranial origin of the PICA can be found in up to 20% of cases[7] .It is closely related to the cerebello-medullary fissure, inferior half of the roof of the IV ventricle, inferior cerebellar peduncle and suboccipital surface of the cerebellum.

Based on its relationship to the medulla and cerebellum, the PICA can be divided in five segments and two loops[5-6,8]. This artery also has, in most cases, a bifurcation, which is located mainly at the level of the telovelotonsilar fissure, giving up two trunks: medial (with branches to the inferior portion of vermis, tonsila and cerebelar cortex) and lateral (which give multiple hemispheric branches and short tonsilar branches irrigating the posterior-inferior portion if the tonsila). Segments[8]: 1) Anterior medullary segment: extends from the origin of PICA at VA, passes through the hypoglossal (CN XII) rootlets, until the most prominent portion of the oliva, the limit between the anterior and lateral surfaces of the medulla. 2) Lateral medullary segment: from the most prominent portion of the oliva to the origin of glossopharyngeal (CN IX), vagus (CN X) and accessory (CN XI) nerves. 3) Telovelomedullary segment: from the origin CN IX, X and XI, extends medially at the posterior surface of medulla, near the caudal half of the tonsila. This portion has the caudal loop, located at the inferior portion of the tonsila. 4) Telovelotonsillar segment: is the most complex segment, ascents from the medial surface of the tonsila to the roof of the IV ventricle, ending at the fissure between the vermis, tonsila and the suboccipital portion of cerebellar hemisphere. It contents the cranial loop, which is caudal to the fastigium, between the tonsila and the velum medullaris. 5) Cortical segment: segment that extends to cerebellar vermis and hemisphere. The Figure 1 illustrates the segments described above.

From the PICA also arise several perforating branches to the medulla, choroidal arteries to the tela choroidea and cortical arteries. The perforating branches are small and arise mainly from the three medullary segments of the PICA. They can be divided into direct and circumflex arteries, having a plexiform aspect of several anastomosis within the brainstem.

Choroidal arteries supply the tela choroidea, from near the midline of choroidal plexus of the IV ventricle to the medial portion of the lateral recess (of Luschka). They originate mainly from tonsilo-medullary and telovelomedular segments.

Cortical branches supply a great portion of the suboccipital surface of cerebellar hemisphere, tonsila and the inferior half of vermis. These branches can be divided into hemispheric (from lateral trunk) and vermian (from medial trunk).

Based on these findings, Lewis defined an anatomical-surgical classification, to determinate whether the PICA can be sacrificed without major deficits to the patient[6]. The proximal segments (anterior and lateral medullary) give branches to the bra-

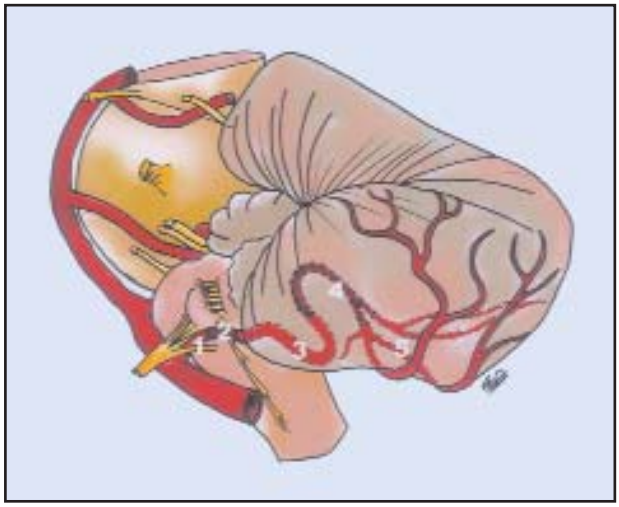

Fig 1. Illustration of PICA segments: 1, anterior medullary segment; 2, lateral medullary segment; 3, telovelomedullary segment; 4, telovelotonsillar segment; 5, cortical segment.

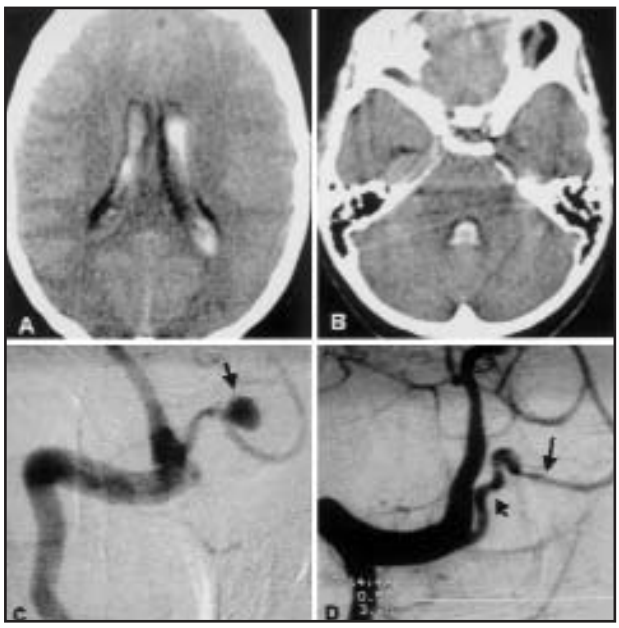

Fig 2. Radiologic evaluation: A and B, CT scan showing bleeding in all four ventricles, with no subarachnoidal hemorrhage. C, right vertebral DSA, oblique view, disclosing the aneurysm arising from the PICA, distal to its origin. D, postoperative DSA, showing no residual aneurysm and preservation of the PICA distal to the clipping.

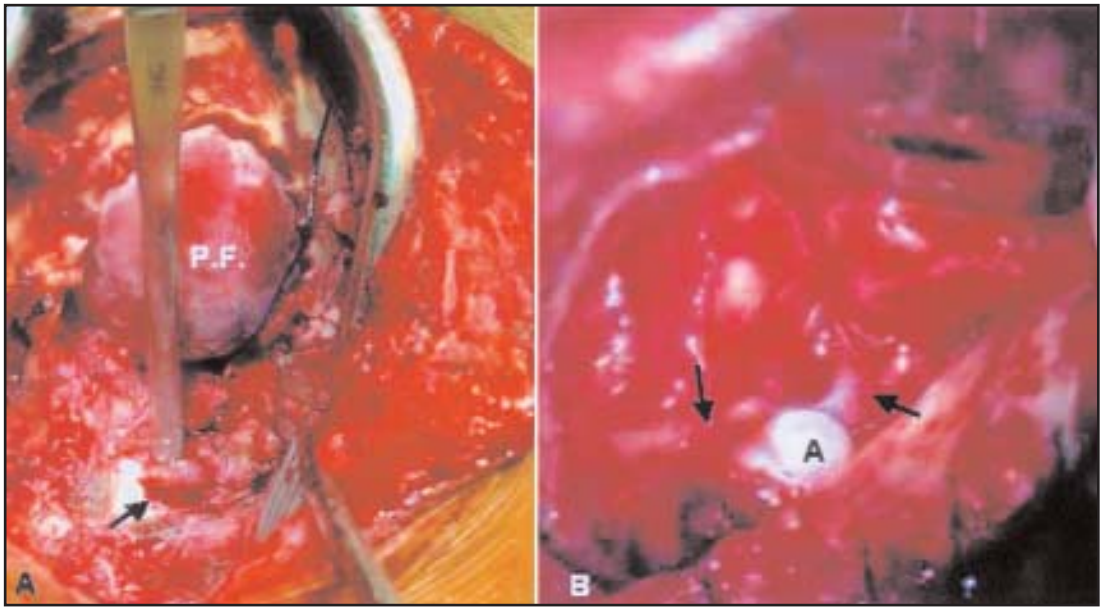

Fig 3. Surgical exposure: A. Right suboccipital craniectomy, with wide exposure of the posterior fossa (P.F.) and the extradural vertebral artery (arrow). B. Microsurgical view, with exposure of distal segments of the PICA (arrows) and the aneurysm (A).

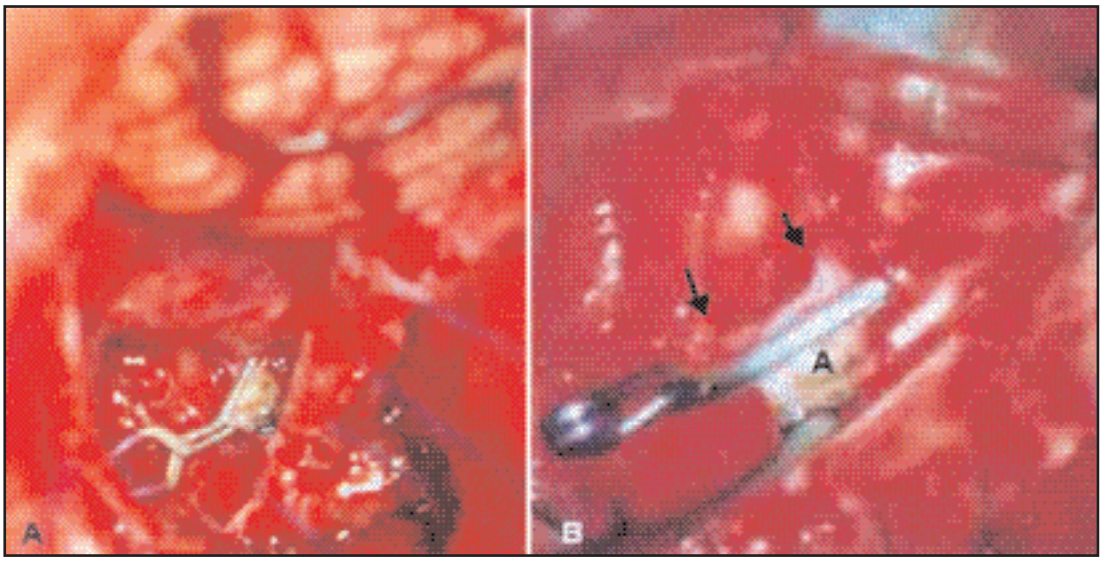

Fig 4. Post-clipping. The aneurysm (A) was totally excluded from the circulation and coagulated, with preservation of the distal segments of the PICA (arrows).

instem, making the preservation of PICA mandatory. The transitional (tonsillomedullary) segment has some perforating branches. The distal (telovelotonsillar and cortical) segments give no perforating arteries to the brainstem, but supply only the cerebellum, and thus if needed the PICA could be sacrificed.

CASE

A 50 year-old woman woke up at the early night with sudden severe headache and vomiting. Although she has previously systemic arterial hypertension, the arterial blood pressure value was normal. She was admitted to other hospital where a computerized tomography (CT) scan examination showed intraventricular hemorrhage (all four ventricles), with no subarachnoid hemorrhage (SAH) or hydrocephalus (Fig 2A and B). She arrived at our service within 24 hours from the ictus, alert, oriented, complaining of severe headache, presenting mild nucal rigidity, with no neurological deficits (Hunt and Hess grade II). Digital subtraction angiography (DSA) presented a right distal (telovelotonsillar) PICA saccular aneurysm (Fig 2C). The aneurysm was approached 36 hours after the ictus through a right suboccpital craniectomy. The right vertebral artery (VA) was exposed extradurally at the cra-

nial cervical junction (Fig 3A). The cisterna magna was drained, and the right intradural VA was dissected, with exposure of the exit of the PICA. The aneurysm was identified at the median opening (of Magendie) of the forth ventricle (Fig 3B), dissected and totally clipped with a single titanium clip (of Yasargil), with preservation of the distal PICA (Fig 4). Postoperative she presented no neurological deficits, and was discharged, asymptomatic at the eleventh postoperative day. The postoperative control DSA conformed the exclusion of the aneurysm and preservation of the PICA (Fig 2D).

DISCUSSION

Aneurysms arising from the PICA are reported as uncommon. In a cooperative study, they reported 0.49% of 2672 intracranial aneurysms[1]. The great majority of these aneurysms are located at the junction of the VA-PICA. In a clinical-anatomical study of 21 PICA aneurysms, only four arouse from distal PICA branches[3]. In Yasargil series, from 15 aneurysms of PICA, 10 were originated from the origin of the vessel[12]; Salcman analyzed 13 aneurysms, 10 of witch arose from the junction of VA-PICA[2]. The pathogenesis of aneurysms in PICA is matter of discussion. It is well accepted that the site of prediction of general aneurysms are the arterial bifurcations; however, the great majority of aneurysms at the distal PICA are not related to its branches[3-6]. Hemodynamic stress at the hairpin curve of the PICA may play a role in branchless aneurysm formation[7]. The development of an aneurysm at the straight portion of the PICA may be related to its embryological development from plexiform formation around the brainstem, leading to several anatomic variations and congenital vascular fragility and thus making a predisposition to aneurysm formation[7,13].

Recently, 2 large series of distal PICA aneurysms were published. Horiuchi reported 24 patients with 27 aneurysms arising from distal branches of the PICA[7]. They accomplished 0.28 of all intracranial aneurysms operated, and 0.38 of ruptured ones. 7 patients had 8 aneurysms (29.6% of the total) at the telovelotonsilar portion, and they were treated with clipping via midline suboccpital approach. All but one patient had a good recovery. Lewis[6] reported 20 aneurysms from the distal PICA, five of which were from the telovelotonsilar PICA; in one patient the aneurysm was fusiform, and the PICA was sacrificed. All patients had good or excellent outcome. Again, midline suboccipital approach was preferred for more distal cases.

Patterns of hemorrhage are described for each site of aneurysm[6]. The telovelomedullary PICA aneurysms usually present with both intracerebellar and intraventricular hemorrhage. As seen on CT scan (Fig 1), our patient presented all ventricles filled with no intracerebellar bleeding. There was no hydrocephalus. Hydrocephalus is associated with unfavorable outcome[7]. In Horowitz series of 38 PICA aneurysms, 11 patients have hydrocephalus requiring shuntting[5]. Predicting the site of the aneurysm with knowledge of the pattern of bleeding despite the absence of vasospasm is important because this kind of lesions can be missed in up to 21.7% of cases[7], despite the absence of vasospasm[2]. Careful four-vessels angiography is always recommended[4].

Although outcomes of distal PICA aneurysms were usually satisfactory[7], complications related to the disease or treatment can be presented in up to 60% of patients[6]. The majority of these patients presented a favorable long-term outcome, in contrast to PICA-VA junction lesions that present a high incidence of lower cranial nerve dysfunction[5]. Telovelomedullar portion of the PICA does not have direct relationship to lower cranial nerves and aneurysms at this location can be treated with low morbidity.

REFERENCES

1. Locksley HB. Report on the Cooperative Study if Intracranial Aneurysms and Subarachnoid Hemorrhage: Section V, Part 1 - Natural history of subarachnoid hemorrhage, intracranial aneurysms and arteriovenous malformation. Based on 6368 cases in the Cooperative Study. J Neurosurg 1966;25:219-239.
2. Salcman M, Rigamonti D, Numaguchi Y, Norihiro S. Aneurysms of the posterior inferior cerebellar artery –vertebral artery complex: variations on a theme. Neurosurgery 1990;27:12-21.
3. Hudgins RJ, Day AL, Quisling RG, Rotton AL Jr, Sytert GW, Garcia-Bengochea F. Aneurysms of the posterior inferior cerebellar artery aneurysms. J Neurosurg 1983;58:381-387.
4. Nishizaki T, Tamaki N, Nishida Y, Fujita K, Matsumoto S Aneurysms of the distal posterior inferior cerebellar artery: experience with three cases and review of the literature. Neurosurgery 1985;16:829-832.
5. Horowitz M, Kopitnik T, Landreneau F, et al. Posterior inferior cerebellar artery aneurysms: surgical results for 38 patients. Neurosurgery 1998; 43:1026-1032.
6. Lewis SB, Chang DJ, Peace DA, LaFrentz PJ, Day AL. Distal posterior inferior cerebellar artery aneurysms: clinical features and management. J Neurosurg 2002;97:756-766.
7. Horiuchi T, Tanaka Y, Hongo K, Nitta J, Kusano Y, Kobayashi S. Characteristics of distal posteroinferior cerebellar artery aneurysms. Neurosurgery 2003;53:589-596.
8. Rothon AL Jr. The cerebellar arteries. Neurosurgery 2000;47(Suppl 3):S29-68.
9. Fine AD, Cardoso A, Rhoton AL Jr. Microsurgical anatomy of the extracranial-extradural origin of the posterior inferior cerebellar artery .J Neurosurg 1999;91:645-652.
10. Lister JR, Rhoton AL Jr, Matsushima T, Peace DA. Microsurgical anatomy of the posterior inferior cerebellar artery. Neurosurgery 1982;10:170-199.
11. Meneses MS, Jacobonski AP. Vascularização do sistema nervoso central. In Meneses MS: Neuroanatomia Aplicada. Rio de Janeiro: Guanabara Koogan, 1999:316.
12. Yasargil MG. Vertebrobasilar aneurysms. In Yasargil MG. Microneurosurgery, vol 2. New York: Thieme-Stratton, 1984:232-295.
13. Padget DH Development of cranial arteries in human embryo. Contrib Embryol 1948;32:205-262.