

Terson's syndrome in the context of intracranial hemorrhage

Síndrome Terson no contexto das hemorragias intracranianas

Ana Paula Alves Fonseca¹, Marcos Rosa Júnior²

A 62-year-old man was admitted with a hypertensive emergency, anisocoria and decreased level of consciousness. The CT scan showed a hemorrhage in the brainstem and an intraocular hemorrhage (Figure), consistent with Terson's syndrome, a condition that is classically characterized as a vitreous hemorrhage secondary to a subarachnoid hemorrhage. However, it can also

be considered as a traumatic hemorrhage and, more rarely, as an intraparenchymal hemorrhage. The etiology has been attributed to a rapid increase in intracranial pressure, resulting in reduced retinal venous drainage and leading to vitreous bleeding. Terson's syndrome is associated a high rate of morbidity and mortality not only in patients with subarachnoid hemorrhage^{1,2,3,4,5}.

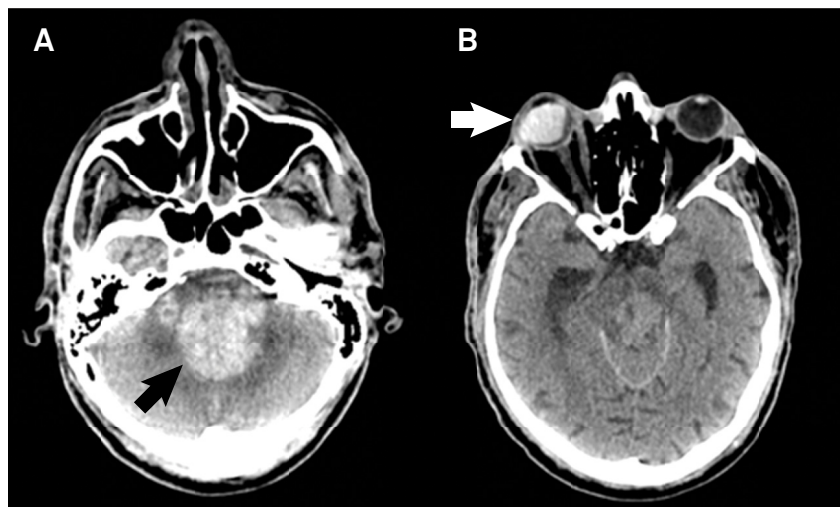


Figure. Computed tomography (CT) showed a hemorrhage in the brainstem and in the vermis of the cerebellum (black arrow in A) and an intraocular hemorrhage in the right eye (white arrow in B), which appeared as spontaneously hyperdense areas on the CT.

References

1. Joswig H, Eprecht L, Valmaggia C, Leschka S, Hildebrandt G, Fournier JY et al. Terson syndrome in aneurysmal subarachnoid hemorrhage-its relation to intracranial pressure, admission factors, and clinical outcome. *Acta Neurochir (Wien)*. 2016;158(6):1027-36. <https://doi.org/10.1007/s00701-016-2766-8>
2. Czorlich P, Skevas C, Knosp V, Vettorazzi E, Richard G, Wagenfeld L et al. Terson syndrome in subarachnoid hemorrhage, intracerebral hemorrhage, and traumatic brain injury. *Neurosurg Rev*. 2015;38(1):129-36. <https://doi.org/10.1007/s10143-014-0564-4>
3. Takkar A, Kesav P, Lal V, Gupta A. Teaching neuroimages: Terson syndrome in cortical venous sinus thrombosis. *Neurology*. 2013;81(6):e40-1. <https://doi.org/10.1212/WNL.0b013e31829e6f13>
4. Kim HS, Lee SW, Sung SK, Seo EK. Terson syndrome caused by intraventricular hemorrhage associated with moyamoya disease. *J Korean Neurosurg Soc*. 2012;51(6):367-9. <https://doi.org/10.3340/jkns.2012.51.6.367>
5. Kapoor S. Terson syndrome: an often overlooked complication of subarachnoid hemorrhage. *World Neurosurg*. 2014;81(1):e4. <https://doi.org/10.1016/j.wneu.2013.08.012>

¹Universidade Federal do Espírito Santo, Departamento de Radiologia, Vitória ES, Brasil;

²Universidade Federal do Espírito Santo, Departamento de Neurorradiologia, Vitória ES, Brasil.

Correspondence: Marcos Rosa Júnior; Departamento de Neurorradiologia da UFES / Centro de Ciências da Saúde; Avenida Marechal Campos, 1355; 29041-295 Vitória ES, Brasil; E-mail: marcosrosajr@hotmail.com

Conflict of interest: There is no conflict of interest to declare.

Received 24 September 2016; Accepted 11 August 2017.