

Relationship of white matter hyperintensities with clinical features of seizures in patients with epilepsy

A relação das hiperintensidades da substância branca com as características clínicas das crises em pacientes com epilepsia

Ferda İlgen USLU¹, Elif ÇETINTAŞ², İsmail YURTSEVEN³, Alpay ALKAN³, Mehmet KOLUKISA¹

ABSTRACT

Background: Although epilepsy is primarily known as a cortical disorder, there is growing body of research demonstrating white matter alterations in patients with epilepsy. **Objective:** To investigate the prevalence of white matter hyperintensities (WMH) and its association with seizure characteristics in patients with epilepsy. **Methods:** The prevalence of WMH in 94 patients with epilepsy and 41 healthy controls were compared. Within the patient sample, the relationship between the presence of WMH and type of epilepsy, frequency of seizures, duration of disease and the number of antiepileptic medications were investigated. **Results:** The mean age and sex were not different between patients and healthy controls ($p>0.2$). WMH was present in 27.7% of patients and in 14.6% of healthy controls. Diagnosis of epilepsy was independently associated with the presence of WMH ($\beta=3.09$, 95%CI 1.06–9.0, $p=0.039$). Patients with focal epilepsy had higher prevalence of WMH (35.5%) than patients with generalized epilepsy (14.7%). The presence of WMH was associated with older age but not with seizure characteristics. **Conclusions:** WMH is more common in patients with focal epilepsy than healthy controls. The presence of WMH is associated with older age, but not with seizure characteristics.

Keywords: Epilepsy; White Matter; Epilepsies, Partial; Epilepsy, Generalized.

RESUMO

Antecedentes: Embora a epilepsia seja principalmente conhecida como um distúrbio cortical, há um crescente corpo de pesquisas que demonstra alterações na substância branca em pacientes com epilepsia. **Objetivo:** Investigar a prevalência de hiperintensidades da substância branca (WMH) e sua associação com características das crises em pacientes com epilepsia. **Métodos:** A prevalência de WMH em 94 pacientes com epilepsia e 41 controles saudáveis foi comparada. Na amostra de pacientes, foi investigada a relação entre a presença de WMH e o tipo de epilepsia, a frequência das crises, a duração da doença e o número de medicamentos antiepilépticos. **Resultados:** A média de idade e o sexo não diferiram entre pacientes e controles saudáveis ($p>0,2$). WMH estava presente em 27,7% dos pacientes, enquanto em 14,6% dos controles saudáveis. O diagnóstico de epilepsia foi independentemente associado à presença de WMH ($\beta=3,09$, IC95% 1,06–9,0, $p=0,039$). Pacientes com epilepsia focal apresentaram maior prevalência de WMH (35,5%) do que pacientes com epilepsia generalizada (14,7%). A presença de WMH foi associada à idade avançada, mas não a características das crises. **Conclusões:** Pacientes com epilepsia focal têm WMH mais comum do que controles saudáveis. A presença de WMH está associada à idade avançada, mas não a características das crises epilépticas.

Palavras-chave: Epilepsia; Substância Branca; Epilepsias Parciais; Epilepsia Generalizada.

INTRODUCTION




Epilepsy is a common disorder that affects over 60 million people worldwide and is an important contributor to the global burden of neurological disease^{1,2}. According to



latest classification system of the International League Against Epilepsy (ILAE), epilepsies are mainly classified as focal, generalized, and unknown epilepsies³. Neuroimaging is an important tool in the setting of diagnosis and classification of epilepsies along with detailed medical history,

¹Bezmialem Vakif University, Medical Faculty, Department of Neurology, Fatih, İstanbul, Turkey.

²Bezmialem Vakif University, Medical Faculty, Fatih, İstanbul, Turkey.

³Bezmialem Vakif University, Medical Faculty, Department of Radiology, Fatih, İstanbul, Turkey.

FIU  <https://orcid.org/0000-0002-2124-5037>; EC  <https://orcid.org/0000-0003-4011-0952>; İY  <https://orcid.org/0000-0001-7482-668X>;

AA  <https://orcid.org/0000-0002-3002-1641>; MK  <https://orcid.org/0000-0001-9415-3638>

Correspondence: Ferda İlgen Uslu; Email: ferdailgen@yahoo.com.

Conflicts of interest: There is no conflict of interest to declare.

Authors' contributions: FIU: designed, directed, and coordinated the study, analyzed data and wrote the paper; EC: acquisition of clinical and MRI data; İY: performed radiologic analyses; AA, MK: data interpretation, revising the article.

Received on January 12, 2021; Received in its final form on April 06, 2021; Accepted on April 30, 2021.



physical examination, and application of electroencephalography (EEG). Although structural magnetic resonance imaging (MRI) does not usually show any visual abnormalities in patients with generalized epilepsies, it is helpful for the identification of common epileptogenic lesions such as hippocampal sclerosis, tumors, vascular lesions, gliosis/encephalomalacia, and congenital/developmental abnormalities in patients with focal epilepsies^{4,5,6}. However, studies have demonstrated that MRI reveals potentially epileptogenic lesions only in about half of the adult patients with new-onset focal seizures^{5,6}.

Epilepsy is primarily considered a disease resulting from disorders of the cortical network organization⁷. However, there is accumulating evidence that both focal and generalized epilepsies represent widespread white matter alterations even in the absence of visible structural lesions^{8,9,10,11,12,13}. This raises the critical question of whether visible white matter lesions would be more common in patients with epilepsy, but this has not been well studied. White matter hyperintensities (WMH) are commonly seen imaging markers especially in elderly population and they are attributed to cerebral small vessel diseases. However, WMH can also be seen in different clinical settings such as genetic disorders, inflammatory diseases, toxic/metabolic conditions, and migraine^{14,15}.

In this study, we aimed to compare the presence and extent of WMH between patients with epilepsy and healthy controls. We also investigated the association of WMH with type of epilepsy, duration of disease, frequency of seizures, and the number of antiepileptic medications used in patients with epilepsy.

METHODS

The data of this study were obtained from a prospective single center study performed between June 1, 2019 and January 31, 2020. The inclusion criteria for this study were as follows: a) being >18 years old; b) diagnosis of epilepsy according to the ILAE criteria (3); c) being followed-up at the Outpatient Clinic for Epilepsy at least for 1 year; d) having a brain MRI that was done in accordance with the 'epilepsy-specific MRI protocol'. Patients were classified as focal, generalized, and unclassified epilepsy using medical history, characteristics of seizures, EEG, and MRI. Patients with unclassified epilepsy were excluded from the analysis. Other exclusion criteria of the study were as follows: a) patients who have acute symptomatic seizures; b) patients who have had a single unprovoked seizure; c) unreliable seizure history or suspicion of psychogenic nonepileptic seizure; d) patients with vascular risk factors such as hypertension, diabetes mellitus, and cardiac diseases; e) patients with neurodegenerative diseases such as Alzheimer's disease and Parkinson's disease; f) patients with a history of central nervous system diseases such as brain

tumor, inflammatory and demyelination diseases; g) patients who had lesions other than WMH on MRI such as lacunar infarcts or vascular lesions; h) history of psychiatric diseases; i) being pregnant or lactating; j) patients not willing to participate in the study. Demographics, age at the seizure onset, duration of epilepsy (≤ 10 years vs. > 10 years), frequency of seizures (seizure-free in the previous year vs. at least 1 seizure in the previous year), and the number of antiepileptic medications (1 vs. > 1) were recorded for all patients. Healthy controls were selected from participants who did not have a diagnosis of epilepsy or any other neurological diseases, who had a normal neurological examination, and who fulfilled the above-mentioned exclusion criteria. This study was performed with the approval of and in accordance with the guidelines of the institutional review board of The Ethics Committee of Bezmialem Vakıf University. All participants provided written informed consent.

Structural magnetic resonance imaging and analyses

All patients underwent an MRI at 1.5 T (Siemens Avanto, Erlangen, Germany). The MRI protocol included axial T2-weighted (time of repetition (TR) TR/time of echo (TE): 4.280/91 ms; matrix: 384×211; number of signal averages (NSA): 1; slice thickness: 5 mm), axial T1-weighted (TR/TE: 500/87 ms; matrix: 256×125; NSA: 1; slice thickness: 5 mm), axial fluid attenuated inversion recovery (FLAIR) (TR/TE/TI: 8.000/118/23.687 ms; matrix: 256×140; NSA: 1; slice thickness: 5 mm), coronal FLAIR (TR/TE/TI: 8.000/118/23.695 ms; matrix: 256×144; NSA: 1; slice thickness: 5 mm), and T2-weighted sagittal (TR/TE: 4.810/90; matrix: 320×247; NSA: 1; slice thickness: 5 mm) and sagittal 3D T1-weighted (TR/TE: 476/86; matrix: 256×154; NSA: 1; slice thickness: 1 mm) images. Healthy controls underwent a structural MRI with similar protocol. All MRIs were examined by the same radiologist who was blind to the diagnosis. WMH are defined as lesions ≥ 5 mm hyperintense on T2-weighted and FLAIR, and isointense or mild hypointense on T1-weighted sequences. The locations were grouped as periventricular when the lesions were adjacent to the ventricular system and deep (subcortical) when they were located in deep areas of cerebral white matter. Hemispheric (right/left) and lobar (frontal/parietal/temporal/occipital) locations of deep WMHs were also recorded. Finally, total burden of WMH was graded according to the age-related white matter changes (ARWMC) scale¹⁶. In the ARWMC scale, the degree of white matter changes is rated on a 4-point scale (0: no lesion, 1: focal lesion, 2: onset of lesions fusion, 3: diffuse changes) in five different regions (frontal, parietal-occipital, temporal, basal ganglia, and infratentorial) of the two hemispheres. The total ARWMC score is the sum of the score for each region in both hemispheres and ranges between 0 to 30. The global ARWMC score, on the other hand, is the score of the region with the most severe WMH. Hence, this global

score provides only four grading of WMC severity, with scores ranging from 0 to 3.

Electroencephalography

A standardized EEG examination was done in all patients within at least 7 days apart from the last seizure. EEG electrodes were placed according to the 10–20 international electrode system, and recording was done with a digital EEG-acquisition and analysis system (Medelec) with 21 electrodes. During the examinations, the time constant was normalized to 0.3 sec, the low-frequency filter to 0.5 Hz, and the high-frequency filter to 70 Hz. The Cz electrode was used as the reference electrode. The protocol of EEG included eye opening-and-closing tests (7 times), intermittent photic stimulation (IFS; 5–30 Hz), and 5-minute hyperventilation (HV) tests. All EEGs were evaluated for background activity (frequency, response to eye opening-closing, hemisphere symmetry in terms of quantity, frequency, and amplitude), pathological slow waves, paroxysmal abnormalities (localization, lateralization, morphology, continuity, frequency), and activation methods (HV, IFS). The presence of any epileptiform abnormality is considered as ‘pathological EEG.’

Statistical analysis

First, patients with epilepsy and healthy controls were compared for demographics and for the presence and burden of WMH. Then, patients with WMH and those without WMH were compared for demographics, disease characteristics (frequency of seizures, disease duration, number of antiepileptic medications, type of epilepsy), and EEG abnormalities. Discrete variables were presented as count (%) and continuous variables as mean (\pm SD) or median (interquartile range [IQR]), as appropriate based on data distribution. Group comparisons were carried out using independent Student’s *t*-test (for normal distributions) or Wilcoxon rank-sum test (for non-normal distribution) for continuous variables. Pearson chi-square or Fisher’s exact tests were applied when evaluating associations among discrete variables. Separate logistic regression analyses were used to investigate the independent associations between the presence of WMH and diagnosis of epilepsy (versus healthy controls) as well as type of epilepsy (focal versus generalized). All statistical analyses were conducted using Statistical Package for the Social Sciences (SPSS), version 20, software. A *p* value less than 0.05 was considered statistically significant.

RESULTS

During the study period, 316 patients were evaluated at the outpatient clinic. Of these, 94 patients with epilepsy were included in the study while 222 were excluded for various reasons (Figure 1). Forty-one healthy controls were also recruited for the current study.

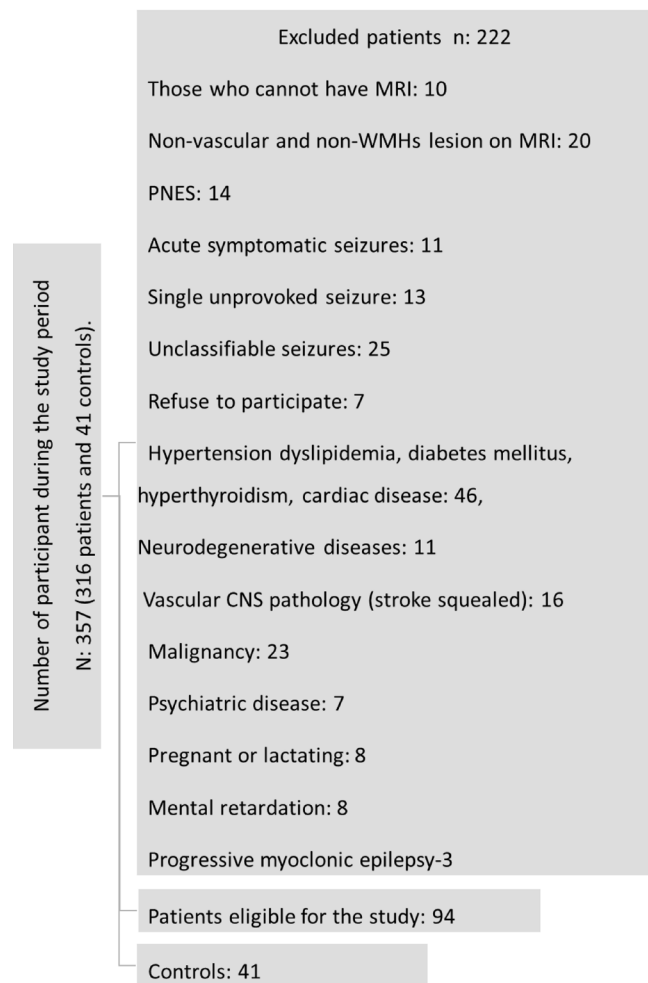


Figure 1. Flowcharts of patient inclusion and exclusion.

The mean age of patients with epilepsy was 30.45 ± 11.5 years and 59.6% were female. The mean age of healthy controls was 33.11 ± 11.7 years and 63.4% were female. Neither age nor sex differed between patients and controls ($p=0.222$ and $p=0.773$, respectively).

Of patients, the mean age of seizure onset was 21.4 ± 11.9 years, and the duration of epilepsy was 8.9 ± 7.7 years. Sixty-five patients (69.1%) had seizures for ≤ 10 years, while 29 patients (30.9%) had seizures for > 10 years. Sixty patients (63.8%) were seizure-free in the previous year, while 34 patients (36.2%) were not. Sixty-eight (72.3%) patients were taking 1 antiepileptic drug while the remaining 26 (27.7%) were taking more than 1 antiepileptic drug. Sixty patients (63.8%) were categorized as focal epilepsy and 34 patients (36.2%) as generalized epilepsy. The mean age did not significantly differ between patients with focal and with generalized epilepsy ($p=0.133$). Of EEGs, 70 (74.5%) were within normal limits, 16 (17%) showed focal epileptic abnormalities, and the remaining 8 (8.5%) showed generalized epileptic abnormalities.

WMH were present in 26 (27.7%) patients with epilepsy and in 6 (14.6%) healthy controls ($p=0.126$). WMH were located only in one hemisphere in 22 (84.6% of all

patients) patients with epilepsy, while they were bilateral in the remaining 4 (15.4%) patients (Figure 2). Of healthy controls with WMH, 4 (66.6%) had bilateral and the remaining 2 (33.3%) had unilateral WMHs. In both patients and healthy controls, all WMH were seen as focal lesions in all regions, therefore global ARWMC scores were 1 in both patients and healthy controls. Total ARMMC scores did not change between groups either ($p=0.312$). Considering lobar locations of WMH, 14 patients had WMH in frontal, 4 in frontal and parietal, 5 in parietal, 1 in temporal and occipital, 1 in temporal and 1 patient in occipital region. In healthy controls, on the other hand, all WMH were located in frontal lobes.

The mean age was significantly higher in patients with WMH than those without WMH (36.3 ± 15.4 vs 28.1 ± 8.8 , $p=0.022$). Age was also significantly different between healthy controls with WMH and those without WMH (43.6 ± 17 vs 31.3 ± 9.8 , $p=0.015$). Sex was not associated with the presence of WMH, either in patients ($p=0.641$) or in healthy controls ($p=0.651$). In a logistic regression analysis with the presence of WMH as dependent variable and age, sex, and diagnosis of epilepsy (vs healthy controls) as independent variables, increase in age ($\beta=1.07$, 95%CI 1.02–1.11, $p=0.001$) as well as the diagnosis of epilepsy ($\beta=3.09$, 95%CI 1.06–9.0, $p=0.039$) were independently associated with the presence of WMH.

Within the patient sample, the presence of WMH was not associated with the frequency of seizure ($p=0.444$), duration of epilepsy ($p=0.610$), number of antiepileptic medications used ($p=0.148$) or with the presence of EEG abnormalities ($p=0.848$).

According to the type of epilepsy, 21 (35%) patients with focal epilepsy and 5 (14.7%) with generalized epilepsy had WMH. The presence of WMH was significantly higher in patients with focal epilepsy than in patients with generalized epilepsy ($p=0.035$). In a logistic regression analysis with the presence of WMH as dependent variable and age, sex and type of epilepsy (focal vs. generalized) as independent variable, increase in age was independently associated with the presence of WMH ($\beta=1.06$, 95%CI 1.01–1.11, $p=0.011$) while diagnosis of focal epilepsy showed a trend toward association with the presence of WMH ($p=0.064$).

When analyzing the two types of epilepsy separately, age was significantly higher in WMH+ patients with focal epilepsy than WMH- patients with focal epilepsy (38.0 ± 16.5 vs

28.4 ± 9.6 , $p=0.006$). On the other hand, the presence of WMH was not associated with age in patients with generalized epilepsy ($p=0.720$). Sex was not associated with the presence of WMH, either in patients with focal epilepsy ($p=0.587$) or in patients with generalized epilepsy ($p=1.0$). Frequency of seizures, duration of disease, presence of pathological EEG, and number of antiepileptic medications were also not associated with the presence of WMH in separate analyses of patients with focal and generalized epilepsy ($p>0.2$ for all comparisons).

Of the 21 patients with focal epilepsy and WMH, seizures were in the temporal lobe in 13 and in the frontal lobe in eight patients. In 13 patients with temporal seizures, one patient had WMH in the temporal region, but the EEG abnormality of this patient was seen in the contralateral hemisphere. In eight patients with frontal lobe epilepsy, five patients had WMH in the frontal, one patient in the frontal and temporal, one patient in the parietal, and one patient in the occipital region. One of these patients with frontal WMH and frontal localization showed EEG abnormality in the same region while others did not.

DISCUSSION

In this study, we found that the prevalence of WMH in patients with epilepsy were comparable that with healthy controls. Within patients with epilepsy, the presence of WMH was more common in patients with focal epilepsy compared to patients with generalized epilepsy. In focal epilepsy, the presence of WMH was associated with higher age, but not with frequency of seizures, duration of disease, or number of antiepileptic drugs. The location of WMH did not seem to correspond with the location or lateralization of seizures.

WMH are commonly seen as imaging markers particularly in the elderly population, and the main mechanism leading to these lesions is chronic ischemia due to cerebral small vessel diseases¹⁷. However, they can also be seen in other neurological diseases and even in the healthy population^{14,18}. In our study, WMH were present in about one third of the patients with epilepsy and in about one seventh of the healthy participants. Consistent with the evidence from previous studies, older age was significantly associated

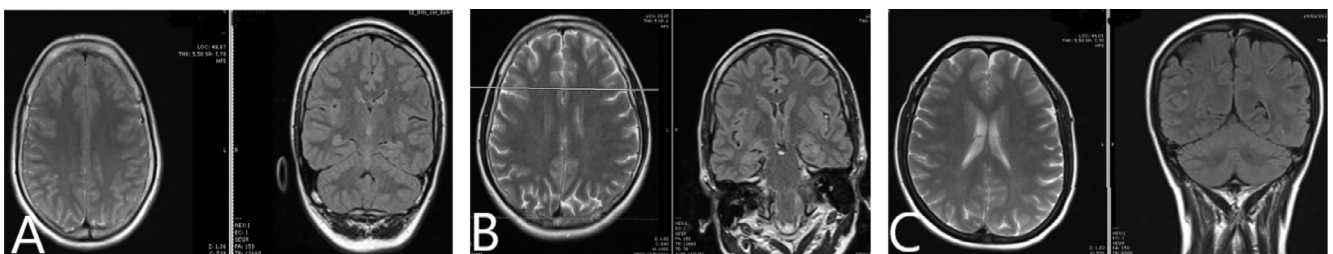


Figure 2. (A) 25 years old female, focal epilepsy; (B) 46 years old male, focal epilepsy; (C) 35 years old female, focal epilepsy.

with the presence of WMH in both patients and healthy controls^{18,19}.

Patients with focal epilepsies had higher rates of WMH compared to patients with generalized epilepsy. The prevalence of WMH in generalized epilepsy (14.7%) was comparable to health controls (14.6%). These results suggest that the risk of WMH is increased in patients with focal epilepsy, but not in patients with generalized epilepsy. In the subgroup of patients with focal epilepsy, a relationship between the presence of WMH and characteristics of epilepsy was not found. There was no obvious relationship between the location of WMH and localization/lateralization of epilepsy either.

Over the past years, several brain imaging studies using diffusion MRI have demonstrated white matter alterations in patients with epilepsy. Studies on focal epilepsy have reported that white matter abnormalities are more pronounced in the hemisphere of the epileptic focus²⁰ while studies in patients with generalized epilepsy have reported widespread microstructural alterations, particularly in the frontal and parietal regions²¹. These findings have been confirmed in a very recent multicenter study including 1249 patients with epilepsy and 1069 healthy controls²². It has also been reported that these alterations were more pronounced in patients with a younger age of onset and longer duration of epilepsy, supporting the idea that these alterations are consequences of epilepsy rather than a potential causal relationship^{22,23}. WMH can be defined as gross radiological markers of white matter alterations as previous longitudinal reports have demonstrated that WMH develop in normal appearing white matter that show microstructural alterations at baseline²⁴. Therefore, we also hypothesize that microstructural white matter alterations, which are potential markers of secondary injury from epilepsy, become visible with time as WMH in patients with epilepsy. Our study did not find any relationship between the presence of WMH and frequency of seizures or duration of

epilepsy. However, this might be due to fact that the detection rates of WMH in clinical MRIs are lower than in diffusion MRI, as well as due to our small sample size. Further prospective longitudinal studies evaluating both microstructural alterations and WMH are needed to better understand the relationship between epilepsy and white matter changes.

Another potential explanation for the presence of WMH in patients with epilepsy might be the presence of occult vascular disease pathology. There are multiple lines of evidence demonstrating that WMH and other markers of small vessel diseases are associated with late-onset epilepsy supporting a causal relationship^{25,26}. However, none of our patients fulfilled the criteria for late-onset epilepsy, which is defined as seizures starting at age 60 or later. We also excluded all patients who have a history of vascular disease.

This study had limitations. First, our study had a small sample size. This is particularly due to our extensive exclusion criteria. As WMH can be seen in people with vascular risk factors or with other neurological diseases, we excluded all these patients to better understand the potential relationship between WMH and epilepsy. Second, we did not have data on white matter alterations that would help to investigate the potential correlations between the degree of white matter alterations and WMH. Future studies are needed using both clinical MRI and diffusion MRI to explore potential mechanisms underlying white matter changes in epilepsy. Third, patients underwent only a standard EEG. Using a more advanced EEG technique might help to understand possible relationships between the location of WMH and epileptogenic abnormalities.

In conclusion, patients with focal epilepsy had more WMH in an age-dependent manner than patients with generalized epilepsy. Future studies are needed to better understand the underlying mechanism of WMH in patients with epilepsy.

References

1. Ngugi AK, Bottomley C, Kleinschmidt I, Sander JW, Newton CR. Estimation of the burden of active and life-time epilepsy: a meta-analytic approach. *Epilepsia*. 2010 May;51(5):883-90. <https://doi.org/10.1111/j.1528-1167.2009.02481.x>
2. Disease GBD, Injury I, Prevalence C. Global, regional, and national incidence, prevalence, and years lived with disability for 310 diseases and injuries, 1990-2015: a systematic analysis for the Global Burden of Disease Study 2015. *Lancet*. 2016 Oct;388(10053):1545-602. [https://doi.org/10.1016/S0140-6736\(16\)31678-6](https://doi.org/10.1016/S0140-6736(16)31678-6)
3. Scheffer IE, Berkovic S, Capovilla G, Connolly MB, French J, Guilhoto L, et al. ILAE classification of the epilepsies: position paper of the ILAE Commission for Classification and Terminology. *Epilepsia*. 2017 Apr;58(4):512-21. <https://doi.org/10.1111/epi.13709>
4. Crocker CE, Pohlmann-Eden B, Schmidt MH. Role of neuroimaging in first seizure diagnosis. *Seizure*. 2017 Jul;49:74-8. <https://doi.org/10.1016/j.seizure.2016.05.015>
5. Hakami T, McIntosh A, Todaro M, Lui E, Yerra R, Tan KM, et al. MRI-identified pathology in adults with new-onset seizures. *Neurology*. 2013 Sep;81(10):920-7. <https://doi.org/10.1212/WNL.0b013e3182a35193>
6. Olszewska DA, Costello DJ. Assessment of the usefulness of magnetic resonance brain imaging in patients presenting with acute seizures. *Ir J Med Sci*. 2014 Dec;183(4):621-4. <https://doi.org/10.1007/s11845-013-1061-4>
7. Kramer MA, Cash SS. Epilepsy as a disorder of cortical network organization. *Neuroscientist*. 2012 Aug;18(4):360-72. <https://doi.org/10.1177/1073858411422754>
8. Deleo F, Thom M, Concha L, Bernasconi A, Bernhardt BC, Bernasconi N. Histological and MRI markers of white matter damage in focal epilepsy. *Epilepsy Res*. 2018 Feb;140:29-38. <https://doi.org/10.1016/j.eplepsyres.2017.11.010>
9. Hatton SN, Huynh KH, Bonilha L, Abela E, Alhusaini S, Altmann A, et al. White matter abnormalities across different epilepsy syndromes in adults: an ENIGMA-Epilepsy study. *Brain*. 2020 Aug;143(8):2454-73. <https://doi.org/10.1093/brain/awaa200>

10. Buksakowska I, Szabó N, Martinkovič L, Faragó P, Király A, Vrána J, et al. Distinctive patterns of seizure-related white matter alterations in right and left temporal lobe epilepsy. *Front Neurol*. 2019;10:986. <https://doi.org/10.3389/fneur.2019.00986>
11. Gong J, Chang X, Jiang S, Klugah-Brown B, Tan S, Yao D, et al. Microstructural alterations of white matter in juvenile myoclonic epilepsy. *Epilepsy Res*. 2017 Sep;135:1-8. <https://doi.org/10.1016/j.eplepsyres.2017.04.002>
12. Focke NK, Yogarajah M, Bonelli SB, Bartlett PA, Symms MR, Duncan JS. Voxel-based diffusion tensor imaging in patients with mesial temporal lobe epilepsy and hippocampal sclerosis. *Neuroimage*. 2008 Apr;40(2):728-37. <https://doi.org/10.1016/j.neuroimage.2007.12.031>
13. Lee CY, Tabesh A, Spampinato MV, Helpert JA, Jensen JH, Bonilha L. Diffusional kurtosis imaging reveals a distinctive pattern of microstructural alterations in idiopathic generalized epilepsy. *Acta Neurol Scand*. 2014 Sep;130(3):148-55. <https://doi.org/10.1111/ane.12257>
14. Weidauer S, Nichtweiss M, Hattingen E. Differential diagnosis of white matter lesions: Nonvascular causes-Part II. *Clin Neuroradiol*. 2014 Jun;24(2):93-110. <https://doi.org/10.1007/s00062-013-0267-1>
15. Porter A, Gladstone JR, Dodick DW. Migraine and white matter hyperintensities. *Curr Pain Headache Rep*. 2005 Aug;9(4):289-93. <https://doi.org/10.1007/s11916-005-0039-y>
16. Wahlund LO, Barkhof F, Fazekas F, Bronge L, Augustin M, Sjogren M, et al. A new rating scale for age-related white matter changes applicable to MRI and CT. *Stroke*. 2001 Jun;32(6):1318-22. <https://doi.org/10.1161/01.str.32.6.1318>
17. Wardlaw JM, Smith EE, Biessels GJ, Cordonnier C, Fazekas F, Frayne R, et al. Neuroimaging standards for research into small vessel disease and its contribution to ageing and neurodegeneration. *Lancet Neurol*. 2013 Aug;12(8):822-38. [https://doi.org/10.1016/S1474-4422\(13\)70124-8](https://doi.org/10.1016/S1474-4422(13)70124-8)
18. Hopkins RO, Beck CJ, Burnett DL, Weaver LK, Victoroff J, Bigler ED. Prevalence of white matter hyperintensities in a young healthy population. *J Neuroimaging*. 2006 Jul;16(3):243-51. <https://doi.org/10.1111/j.1552-6569.2006.00047.x>
19. Mao YT, Goh E, Churilov L, McIntosh A, Ren YF, O'Brien TJ, et al. White matter hyperintensities on brain magnetic resonance imaging in people with epilepsy: a hospital-based study. *CNS Neurosci Ther*. 2016 Sep;22(9):758-63. <https://doi.org/10.1111/cns.12571>
20. Labate A, Cherubini A, Tripepi G, Mumoli L, Ferlazzo E, Aguglia U, et al. White matter abnormalities differentiate severe from benign temporal lobe epilepsy. *Epilepsia*. 2015 Jul;56(7):1109-16. <https://doi.org/10.1111/epi.13027>
21. Szaflarski JP, Lee S, Allendorfer JB, Gaston TE, Knowlton RC, Pati S, et al. White matter abnormalities in patients with treatment-resistant genetic generalized epilepsies. *Med Sci Monit*. 2016 Jun;22:1966-75. <https://doi.org/10.12659/msm.897002>
22. Hatton SN, Huynh KH, Bonilha L, Abela E, Alhusaini S, Altmann A, et al. White matter abnormalities across different epilepsy syndromes in adults: an ENIGMA-Epilepsy study. *Brain*. 2020 Aug;143(8):2454-73. <https://doi.org/10.1093/brain/awaa200>
23. Owen TW, de Tisi J, Vos SB, Winston GP, Duncan JS, Wang Y, et al. Multivariate white matter alterations are associated with epilepsy duration. *Eur J Neurosci*. 2021 Apr;53(8):2788-803. <https://doi.org/10.1111/ejn.15055>
24. de Groot M, Verhaaren BF, de Boer R, Klein S, Hofman A, van der Lugt A, et al. Changes in normal-appearing white matter precede development of white matter lesions. *Stroke*. 2013 Apr;44(4):1037-42. <https://doi.org/10.1161/STROKEAHA.112.680223>
25. Johnson EL, Krauss GL, Lee AK, Schneider AL, Kucharska-Newton AM, Huang J, et al. Association between white matter hyperintensities, cortical volumes, and late-onset epilepsy. *Neurology*. 2019 Feb;92(9):e988-e995. <https://doi.org/10.1212/WNL.0000000000007010>
26. Sarkis RA, Willment KC, Pennell PB, Marshall G. Late-onset unexplained epilepsy: What are we missing? *Epilepsy Behav*. 2019 Oct;99:106478. <https://doi.org/10.1016/j.yebeh.2019.106478>