

Rat Subcutaneous Tissue Response to MTA Fillapex® and Portland Cement

Nádia Carolina Teixeira Marques¹, Natalino Lourenço Neto¹, Ana Paula Fernandes¹, Camila de Oliveira Rodini², Marco Antônio Hungaro Duarte³, Thais Marchini Oliveira¹

¹Department of Pediatric Dentistry, Orthodontics and Public Health;
²Department of Biological Sciences;
³Department of Operative Dentistry, Dental Materials and Endodontics, Bauru Dental School, USP - University of São Paulo, Bauru, SP, Brazil

Correspondence: Profa. Dra. Thais Marchini Oliveira, Alameda Dr. Octávio Pinheiro Brisolla, 9-75, Vila Universitária, 17012-901 Bauru, SP, Brasil. Tel: +55-14-3235-8224. e-mail: marchini@usp.br

The aim of this study was to evaluate the response of rat subcutaneous tissue to MTA Fillapex® (Angelus), an experimental root canal filling material based on Portland cement and propylene glycol (PCPG), and a zinc oxide, eugenol and iodoform (ZOEI) paste. These materials were placed in polyethylene tubes and implanted into the dorsal connective tissue of Wistar rats for 7 and 15 days. The specimens were stained with hematoxylin and eosin, and evaluated regarding inflammatory reaction parameters by optical microscopy. The intensity of inflammatory response against the sealers was analyzed by two blinded and previously calibrated examiners for all experimental periods ($\kappa=0.96$). The histological evaluation showed that all materials caused a moderate inflammatory reaction at 7 days, which subsided with time. A greater inflammatory reaction was observed at 7 days in the tubes filled with ZOEI paste. Tubes filled with MTA Fillapex presented some giant cells, macrophages and lymphocytes after 7 days. At 15 days, the presence of fibroblasts and collagen fibers was observed indicating normal tissue healing. The tubes filled with PCPG showed similar results to those observed in MTA Fillapex. At 15 days, the inflammatory reaction was almost absent at the tissue, with several collagen fibers indicating normal tissue healing. Data were analyzed by the nonparametric Kruskal-Wallis test ($\alpha=0.05$). Statistically significant difference ($p<0.05$) was found only between PCPG at 15 days and ZOEI at 7 days groups. No significant differences were observed among the other groups/periods ($p>0.05$). MTA Fillapex and Portland cement added with propylene glycol had greater tissue compatibility than the PCPG paste.

Key Words: biocompatibility, connective tissue, Portland cement, MTA.

Introduction

Successful endodontic therapy depends on correct diagnosis, effective cleaning, elimination of infection and adequate filling of root canals (1). The root filling material will be in contact with the apical tissues and therefore the biocompatibility of dental materials is an important requirement because the toxic components in these materials could produce irritation or even degeneration of the surrounding tissues. Therefore, the biocompatibility of all experimental dental materials that might come in contact with tissues should be examined (2).

Periapical tissue reaction after root canal treatment may be influenced by various factors depending on the chemical nature of the endodontic sealer (1,3). Biocompatibility is one of the most important properties of root filling materials (1,4) because the release of certain substances from sealers may generate different reactions in the periapical tissues and compromise apical repair (1,3). Subcutaneous tissue reaction is one of the *in vivo* biocompatibility tests that have been used for examining several root filling materials (2,5-8).

Mineral trioxide aggregate (MTA) has been originally developed to seal root-end cavities and root perforations (2,5). However, due to its excellent biological properties and mineralization-inducing ability, this material became being

indicated for other clinical endodontic procedures as well. Initially, MTA was not recommended as a root canal sealer because of its poor handling properties (9). However, a new endodontic sealer with a resin sealer based on mineral trioxide aggregate (MTA Fillapex®; Angelus, Londrina, PR, Brazil) was recently developed with this indication (6,8).

On the other hand, great interest has been focused on the evolution of Portland cement (PC) as an alternative to MTA and several experimental studies have compared both materials (10-12). Both materials have comparable antibacterial activity (13,14) and almost identical properties macroscopically, microscopically and by x-ray diffraction analysis (11,13,14). It was also shown that PC and MTA had similar effect on pulp cells when used for direct pulp capping in rat teeth (15).

The aim of this study was to evaluate the response of rat subcutaneous tissue to MTA Fillapex, an experimental root canal filling material based on PC with addition of propylene glycol (PCPG), and a paste containing zinc oxide, eugenol and iodoform (ZOEI).

Material and Methods

After approval of the research protocol by the institutional Ethics Committee (Process #025/2010), 12 male Wistar rats weighing between 200 and 250 g were

randomly assigned to 3 groups: MTA Fillapex, PCPG and ZOEL paste.

Thirty-six polyethylene tubes (1.0 mm inner diameter, 1.6 mm outer diameter and 10.0 mm length) were disinfected with 5% NaOCl for 1 h, washed with saline for 15 min, dried out with sterile gauze and filled with freshly prepared test materials. The materials were prepared in a sterile glass plate by mixing one MTA kit spoon of each powder with two drops of the respective liquids.

The same surgical sequence was used for all animals. They were anesthetized with an intramuscular injection of a mixture of ketamine and xylazine hydrochloride (Dopalen® - 0.4 mL/kg and Anasedan® - 0.02 mL/kg). The dorsal skin was shaved, disinfected with 5% tincture of iodine, and two parallel small incisions (anterior and posterior), approximately 1.5 cm long, were made with a scalpel blade. Two separated pockets were created by blunt dissection, one in the cranial portion and another on the caudal portion, to implant the tube in the subcutaneous tissue in a 5 cm distance of each other. The tubes containing freshly mixed materials were then introduced into the pockets. Care was taken to prevent spilling of the material into the tissue. After implantation, the wounds were sutured.

After 7 and 15 days of the surgery, 6 animals were sacrificed at each experimental period by anesthetic overdose. The tubes were explanted together with skin and connective tissue around them. The samples were immersed in buffered 10% formalin in 0.1 M/L solution for 48 h. Five-micrometer-thick paraffin-embedded tissue sections were made and stained with hematoxylin and eosin.

The histological sections were examined under an optical microscopic, as regards to tissue reaction on the sealer-connective tissue interface at the opening ends of the tubes. The connective tissue response alongside the lateral wall outside tubes, served as a negative control. The examiners did not have any knowledge of the material used in specimens. The overall mean value for each material was determined in subjects at each period. Evaluation of inflammatory reaction was performed according to Coutinho-Filho (16) modified criteria. The degree of inflammation was determined according to the type and number of predominant cells. The presence of absence of neutrophils, inflammatory infiltrate, giant cells, and macrophages was recorded. For each of these elements, the following numerical scores were attributed as grade 0, none (without inflammatory cells); grade 1, mild (inflammatory cells present in small numbers or in small groups); grade 2 moderate (inflammatory cells present in large numbers, yet not predominantly in the microscopic field); grade 3, intense (present as infiltrated, predominantly in the microscopic field); grade 4, necrosis. Kruskal-Wallis test was used for statistical analysis. Statistical significance

level was defined as $p < 0.05$.

Results

Two blinded and previously calibrated observers analyzed the intensity of inflammatory response in the connective tissue around the sealers used in this study for all experimental periods ($\kappa = 0.96$). The connective tissue response alongside the lateral wall outside of the tube was also evaluated, as a negative control for the technique showing no inflammatory reaction in all experimentation periods. The histological evaluation showed that all the materials caused an intense to moderate inflammatory reaction at 7 days that decreased with time.

After 7 days, 75% of ZOEL group's specimens received grade 3 inflammation, which consisted of a dense infiltration of inflammatory and giant cells. A bulk of remaining material was also observed in some cases. At 15 days, 58.3% of the specimens demonstrated grade 2 inflammation, in accordance with the tissue repair occurring in these period (Fig. 1).

As much as 66.7% of PCPG group's specimens were classified as grade 2 after 7 days presenting sporadic inflammatory infiltration cells in some cases without tissue edema. At 15 days, 83.4% of the specimens were graded as 1, with almost absence of inflammation at the tissue, and presence of collagen fibers, indicating normal tissue healing (Fig. 2).

In the MTA Fillapex group, 66.7% of the specimens demonstrated grade 3 inflammation at 7 days, with the tissue presenting infiltration predominantly by macrophages and lymphocytes. At 15 days, 83.4% of the specimens demonstrated grade 2 inflammation, and the presence of fibroblast and collagen fibers were indicating of normal tissue healing (Fig. 3).

There was statistically significant difference ($p < 0.05$) between the PCPG group at 15 days and the ZOEL group at 7 days. No statistically significant difference ($p > 0.05$) was observed among the other groups.

These findings are in accordance with the morphological analysis of the specimens in which the MTA Fillapex group showed less inflammation than the ZOEL group. In view of this, both MTA Fillapex and the experimental PC may be considered to present better biocompatibility properties, although tissue repair of the specimens from the PCPG was the most satisfactory in all periods.

Discussion

Implantation of new endodontic materials into the subcutaneous tissues of rats is one of the most suitable methods to determine the local effects and biocompatibility of those (2,7,16-18). The materials used in root-end filling, furcal perforation, and as apical barrier besides the

necessary preliminary test, must have their biocompatibility characteristics investigated because the toxic components present in these materials could produce irritation or even degeneration of the surrounding tissues, especially when accidentally extruded into the periradicular tissues (1,5). Several endodontic materials routinely used as root-end

fillings materials do not provide complete periodontal regeneration (16).

Several studies have reported excellent results when using MTA in contact with pulp tissue (19-22). MTA has been used in pulp capping, pulpotomy, perforation repairs, and as root-end filling materials with good biocompatibility

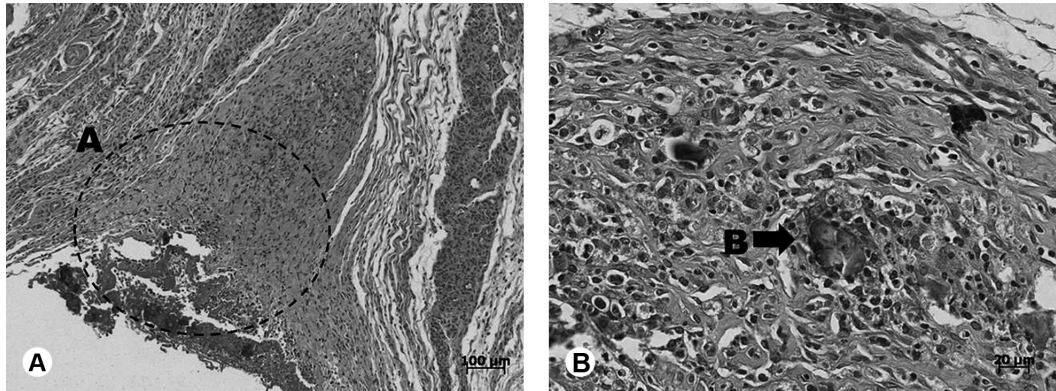


Figure 1. ZOEl group. Intense inflammatory infiltration at 7 days (A) and presence of giant cells close to the residual material at 15 days (B).

N.C.T. Marques et al.

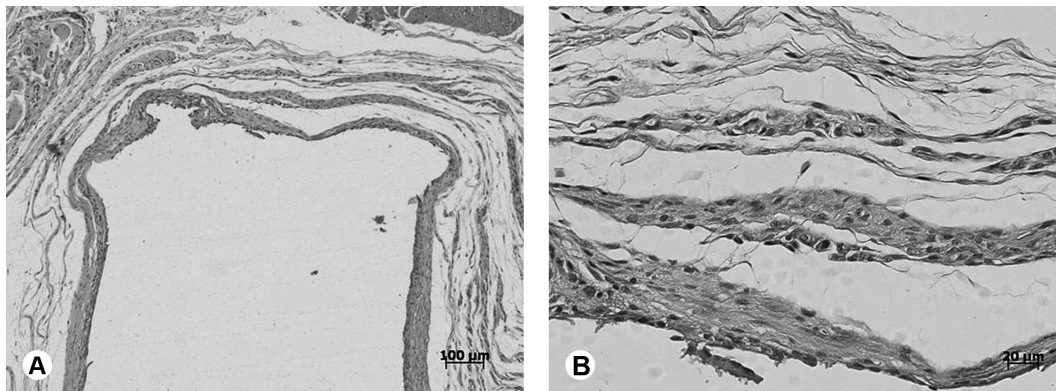


Figure 2. PCPG group. Several collagen fibers and almost no tissue inflammation could be observed at 15 days.

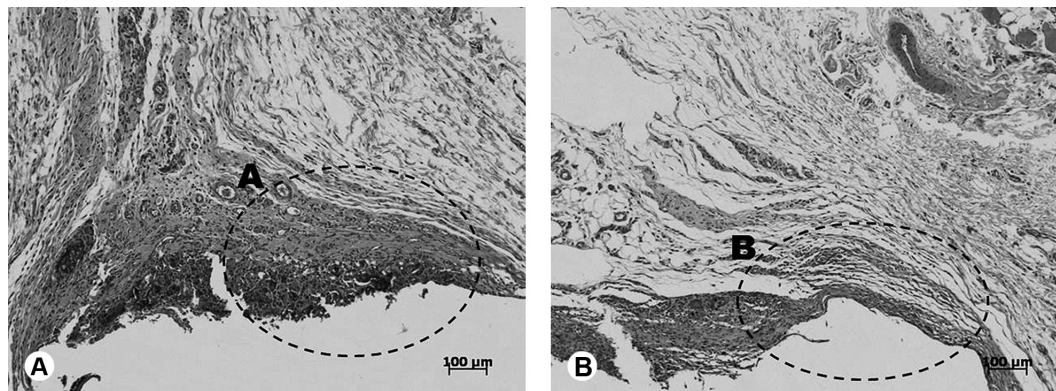


Figure 3. MTA Fillapex group. Moderate inflammatory infiltration with the presence of inflammatory cells at 7 days (A) and fibroblasts and newly formed collagen fibers at 15 days (B).

(21). The factor responsible for the beneficial effects in MTA is also found in PC (10-12,14,23). This has resulted in a significant body of research showing that PC appears to be a useful substitute for MTA (12,14,18,24). Danesh et al. (10) showed that MTA displayed superior properties than PC, which was significantly more soluble, reached lower microhardness values and was less radiopaque. Menezes et al. (19) suggested that the ability of MTA and PC to induce the formation of a dentin bridge may be due to its excellent sealing ability and fast setting time, around 5 min, avoiding diffusion of the material into the tissues, and microleakage throughout the entire procedure. These materials were capable of inducing hard tissue deposition over showing to be effective pulp capping materials.

Recently, MTA Fillapex has been introduced as a root canal sealer and its properties have been investigated (7,18). In this study, the criteria for evaluation as presented by Coutinho-Filho (16) make it possible to supplement the descriptive analysis with an objective analysis of the results. The histological evaluation showed that MTA Fillapex and PCPG caused a moderated inflammatory reaction at 7 days that decreased with time. At 15 days, the inflammation presented almost absent at the tissue, with many collagen fibers indicating normal tissue healing, these findings are in accordance to those observed by Gomes-Filho et al. (7) for MTA Fillapex. PC added with propylene glycol demonstrated promising results material in terms of subcutaneous implantation.

The ZOEl group showed a less favorable biological behavior compared with MTA Fillapex and PCPG groups. This group presented an inflammatory infiltration at 7 days, which persisted throughout the study period. At 15 days, bulk of the remaining material from the ZOEl paste was in the tissue as well as slight formation of collagen fibers. These findings are in accordance with those of previous studies (18,25), which tested others cements with zinc oxide and eugenol and found severe inflammatory infiltration up to the latest periods.

For PC, the results of the present study could be used as a preliminary source of information on the biocompatibility of this material for root canal filling. Other experimental and clinical studies are still needed in order to determine the safe clinical indication of these new endodontic cements. In conclusion, MTA Fillapex and the experimental PCPG were more biocompatible than the ZOEl paste.

Resumo

O objetivo deste estudo foi avaliar a resposta do tecido subcutâneo de rato ao MTA Fillapex® (Angelus), a um cimento endodôntico experimental à base de cimento Portland e propilenoglicol, e à pasta de óxido de zinco e eugenol com iodofórmio. Estes materiais foram colocados em tubos de polietileno e implantados no tecido conjuntivo do dorso de ratos Wistar, por 7 e 15 dias. Os espécimes foram corados com hematoxilina

e eosina e os parâmetros de reação inflamatória foram avaliados em microscópio óptico. A intensidade da resposta inflamatória provocada pelos cimentos foi analisada em todos os períodos por dois observadores previamente calibrados (κ 0,96) e sem conhecimento dos grupos experimentais. O exame histológico mostrou que todos os materiais provocaram reação inflamatória moderada aos 7 dias que regrediu com o tempo. A maior resposta inflamatória do tecido foi observada aos 7 dias, nos tubos preenchidos com pasta de Óxido de Zinco e Eugenol com Iodofórmio. Os tubos com MTA Fillapex apresentaram algumas células gigantes, macrófagos e linfócitos após 7 dias. Aos 15 dias, a presença de fibroblastos e fibras de colágenas foi observada, indicando processo de cicatrização do tecido. Os tubos com o cimento Portland mostraram resultados semelhantes aos observados no grupo MTA Fillapex. Aos 15 dias, a reação inflamatória apresentada foi praticamente ausente, com muitas fibras colágenas, indicando cicatrização normal do tecido. A análise estatística mostrou diferença estatisticamente significativa entre o grupo de cimento Portland (15 dias) e óxido de zinco eugenol com Iodofórmio (7 dias) ($p < 0,05$). Nos outros grupos não houve diferença estatística significativa. MTA Fillapex e cimento Portland são mais biocompatíveis do que os outros cimentos testados.

References

- Zafalon EJ, Versiani MA, de Souza CJ, Moura CC, Dechichi P. *In vivo* comparison of the biocompatibility of two root canal sealers implanted into the subcutaneous connective tissue of rats. *Oral Surg Oral Med Oral Pathol Oral Radiol Endod* 2007;103:88-94.
- Parirokh M, Mirsoltani B, Raof M, Trabrizchi H, Haghdoost AA. Comparative study of subcutaneous tissue response to a novel root-end filling material and white and gray mineral trioxide aggregate. *Int Endod J* 2011;44:283-289.
- Kaplan AE, Ormaechea MF, Picca M, Canzobre MC, Ubios AM. Rheological properties and biocompatibility of endodontic sealers. *Int Endod J* 2003;36:527-532.
- Ozbas H, Yaltirik M, Bilgic B, Issever H. Reactions of connective tissue to compomers, composite and amalgam root-end filling materials. *Int Endod J* 2003;36:281-287.
- Torabinejad M, Pitt Ford TR. Root end filling materials: a review. *Endod Dent Traumatol* 1996;12:161-178.
- Gomes-Filho JE, Bernabé PFE, Nery MJ, Otoboni-Filho JA, Dezan-Júnior E, Costa MMTM, et al. Reaction of rat connective tissue to a new calcium hydroxide-based sealer. *Oral Surg Oral Med Oral Pathol Oral Radiol Endod* 2008;106:71-76.
- Gomes-Filho JE, Watanabe S, Lodi CS, Cintra LT, Nery MJ, Filho JA, et al. Rat tissue reaction to MTA FILLAPEX®. *Dent Traumatol* 2012;28:452-456.
- Bin CV, Valera MC, Camargo SE, Rabelo SB, Silva GO, Balducci I, et al. Cytotoxicity and genotoxicity of root canal sealers based on mineral trioxide aggregate. *J Endod* 2012;38:495-500.
- Holland R, Ferreira LB, de Souza V, Otoboni-Filho JA, Murata SS, Dezan-Junior E. Influence of the type of vehicle and limit of obturation on apical and periapical tissue response in dogs' teeth after root canal filling with mineral trioxide aggregate. *J Endod* 2007;33:693-697.
- Danesh G, Dammaschke T, Gerth HUV, Zandbiglari T, Schafer E. A comparative study of selected properties of ProRoot mineral trioxide aggregate and two Portland cements. *Int Endod J* 2006;39:213-219.
- Islam I, Chng HK, Yap AUJ. Comparison of the physical and mechanical properties of MTA and Portland cement. *J Endod* 2006;32:193-197.
- Sakai VT, Moretti AB, Oliveira TM, Fornetti AP, Santos CF, Machado MA, et al. Pulpotomy of human primary molars with MTA and Portland cement: a randomized controlled trial. *Br Dent J* 2009;207:128-129.
- Song JS, Mante FK, Romanow WJ, Kim S. Chemical analysis of powder and set forms of Portland cement, gray ProRoot MTA, white ProRoot MTA, and gray MTA-Angelus. *Oral Surg Oral Med Oral Pathol Oral Radiol Endod* 2006;102:809-815.
- Steffen R, van Waas H. Understanding mineral trioxide aggregate/Portland-cement: a review of literature and background factors. *Eur Arch Paediatr Dent* 2009;10:93-97.
- Shahi S, Rahimi S, Yavari HR, Mokhtari H, Roshangar L, Abasi MM, et

- al.. Effect of mineral trioxide aggregates and Portland cements on inflammatory cells. J Endod 2010;36:899-903.
16. Coutinho-Filho T, De-Deus G, Klein L, Manera G, Peixoto C, Gurgel-Filho ED. Radiopacity and histological assessment of Portland cement plus bismuth oxide. Oral Surg Oral Med Oral Pathol Oral Radiol Endod 2008;106:69-77.
 17. Al-Omari WM, Abu-Zaghlán MS, Hammad HM. Reaction of rat connective tissue to mineral trioxide aggregate and Diaket. BMC Oral Health 2011;11:17. doi:10.1186/1472-6831-11-17.
 18. Znemer O, Lalis RM, Pameijer CH, Chaves C, Kokubu G, Grana D. Reaction of rat subcutaneous connective tissue to a mineral trioxide aggregate-based and a zinc oxide and eugenol sealer. J Endod 2012;38:1233-1238.
 19. Menezes R, Bramante CM, Letra A, Carvalho VGG, Garcia RB. Histologic evaluation of pulpotomies in dog using two types of mineral trioxide aggregate and white Portland cements as wound dressings. Oral Surg Oral Med Oral Pathol Oral Radiol Endod 2004;98:376-379.
 20. Moretti AB, Sakai VT, Oliveira TM, Fornetti AP, Santos CF, Machado MA, et al. Effectiveness of mineral trioxide aggregate, calcium hydroxide and formocresol for pulpotomies in primary teeth. Int Endod J 2008;41:547-555.
 21. Parirokh M, Torabinejad M. Mineral trioxide aggregate: a comprehensive literature review. Part I: chemical, physical and antibacterial properties. J Endod 2010;36:16-27.
 22. Cardoso-Silva C, Barbería E, Maroto M, Garcia-Godoy F. Clinical study of Mineral Trioxide Aggregate in primary molars. Comparison between Grey and White MTA - A long-term follow-up (84 months). J Dent 2011;39:187-193.
 23. Holland R, Souza V, Murata SS, Nery MJ, Bernabé PF, Otoboni Filho JA, et al.. Healing process of dog dental pulp after pulpotomy and pulp covering with mineral trioxide aggregate or Portland cement. Braz Dent J 2001;12:109-113.
 24. Fayazi S, Ostad SN, Razmi H. Effect of ProRoot MTA, Portland cement, and amalgam on the expression of fibronectin, collagen I, and TGFβ by human periodontal ligament fibroblasts *in vitro*. Indian J Dent Res 2011;22:190-194.
 25. Scarparo RK, Grecca FS, Fachin EV. Analysis of tissue reactions to methacrylate resin-based, epoxy resin-based, and zinc oxide-eugenol endodontic sealers. J Endod 2009;35:229-232.

Received November 16, 2012
Accepted January 30, 2013