



Angle Class III malocclusion, subdivision right, treated without extractions and with growth control*

Sérgio Henrique Casarim Fernandes**

Abstract

Angle Class III malocclusion is characterized by anteroposterior dental and facial discrepancies usually accompanied by skeletal changes associated with a genetic component. Early, accurate diagnosis and appropriate treatment are of paramount importance to promote growth control and prevent relapse. This article reports the two-phase treatment of a female patient, aged 12 years, with an Angle Class III, subdivision right malocclusion with anterior crossbite in maximum intercuspation (MIC) and end-on bite in centric relation, further presenting with lack of maxillary space. The case was treated without extractions and with growth control. This case was presented to the Brazilian Board of Orthodontics and Facial Orthopedics (BBO) as representative of Category 1, i.e., Angle Class III malocclusion treated without tooth extractions, as part of the requirements for obtaining the BBO Diploma.

Keywords: Angle Class III. Maxillary protraction. Interceptive orthodontics.

* Case report, Category 1 - approved by the Brazilian Board of Orthodontics and Facial Orthopedics (BBO).

** M.Sc. and Specialist in Orthodontics and Facial Orthopedics, COP/PUC-Minas Gerais State, Brazil. Coordinator, Specialization Program in Orthodontics, Brazilian Dental Association (ABO), Juiz de Fora, Minas Gerais State, Brazil. Diplomate of the Brazilian Board of Orthodontics and Facial Orthopedics (BBO).

HISTORY AND ETIOLOGY

The female Caucasian patient presented for orthodontic consultation at age 12, with good general health, reporting no history of serious illness and/or trauma. She had no sucking or postural habit and had normal swallowing and speech.

She was in the permanent dentition phase with second maxillary molars still missing. Menarche had occurred five months earlier, suggesting that the patient was in the deceleration phase of pubertal growth spurt. She

had no relevant carious lesions and no periodontal problems. In centric relation (CR) she presented with an end-on bite in the anterior region, and maximum intercuspation (MIC), severe anterior crossbite (Figs 1, 2 and 3). In researching the family history it was found that the mother had an end-on dental relation in the anterior region. The patient's chief complaint was esthetics-related. According to her, she was greatly disturbed by the protrusion of her lower teeth.

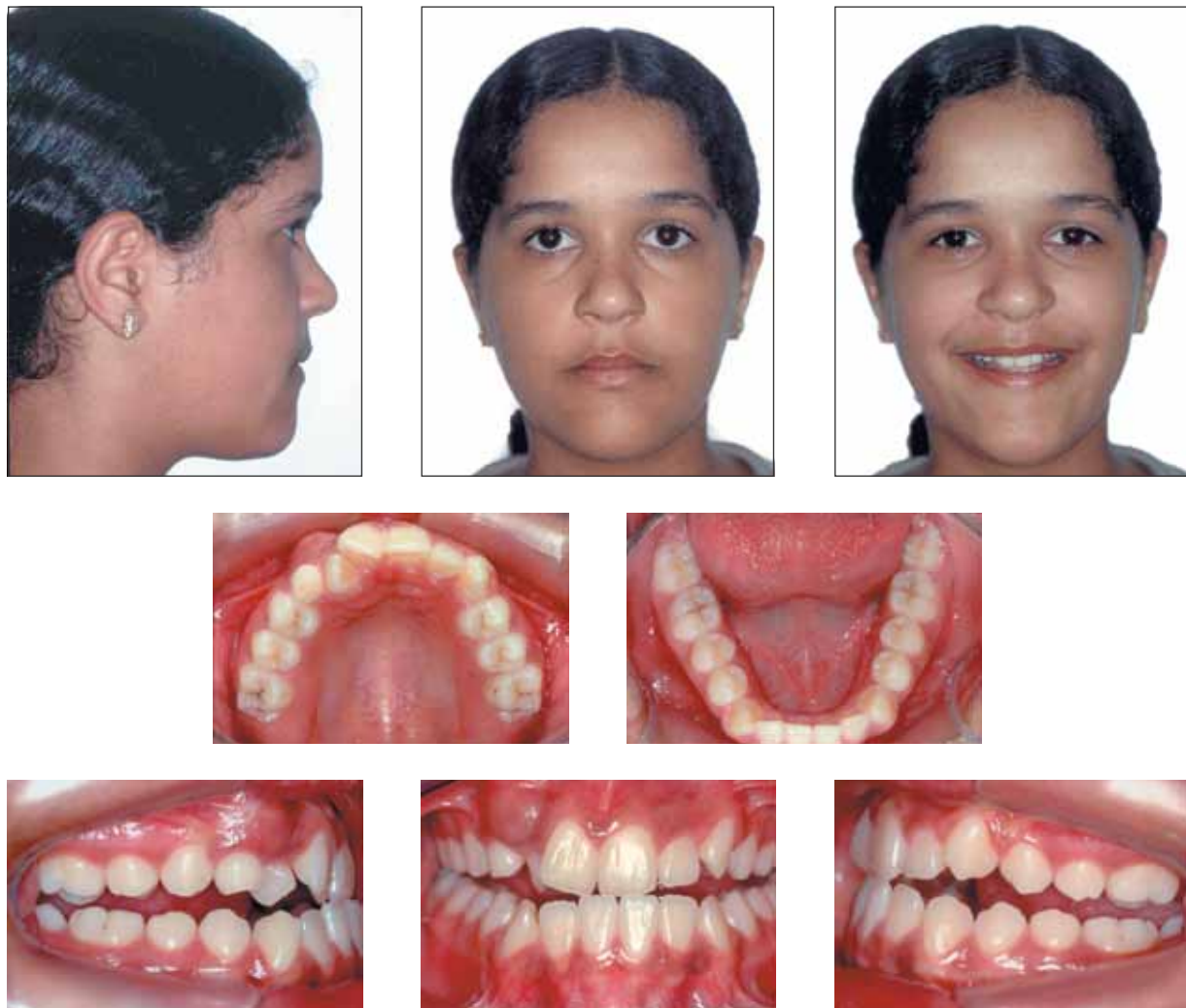

FIGURE 1 - Initial facial and intraoral photographs in centric relation (CR).

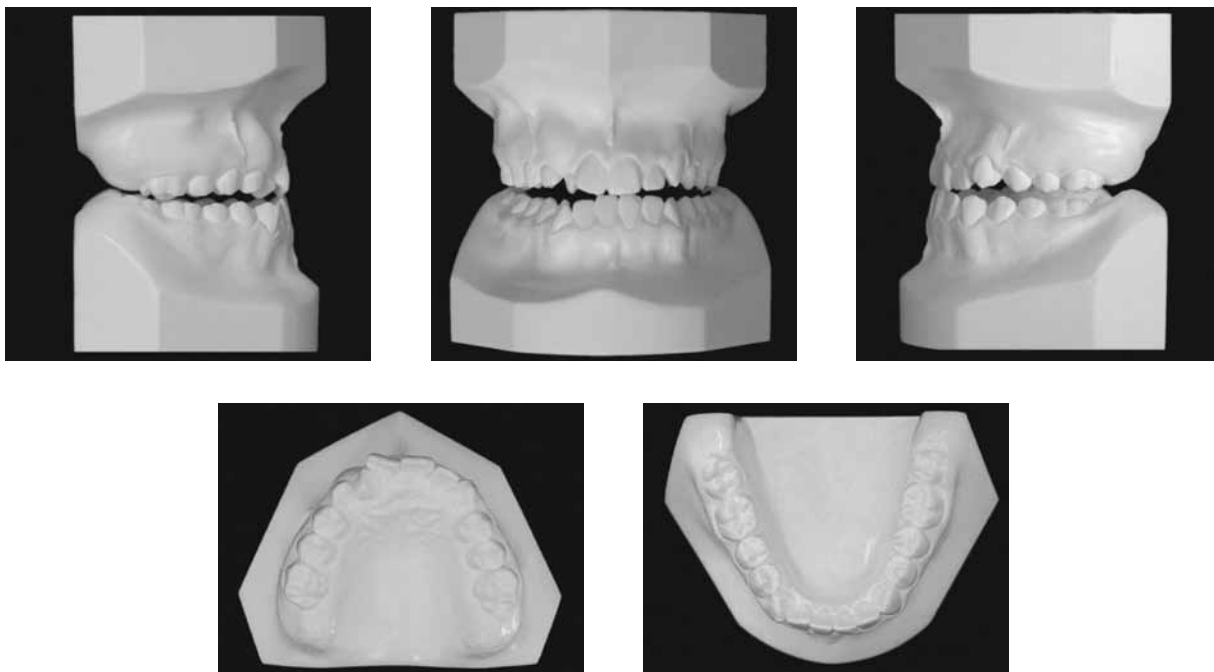


FIGURE 2 - Initial models in CR.

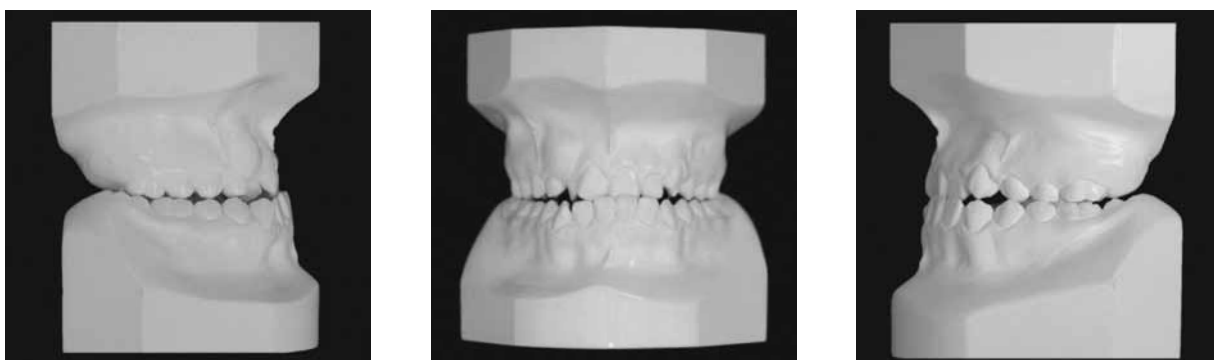


FIGURE 3 - Initial models in maximum intercuspation (MIC).

DIAGNOSIS

The patient showed facial symmetry, a straight profile, proportional vertical thirds, lip competence and a predominantly nasal breathing pattern (Fig 1).

From a dental perspective, she presented, in CR, an Angle Class III malocclusion, right subdivision, end-on incisor relationship and, on the right side, bilateral posterior open bite, maxillary and mandibular crowding with rotations, lack of space for tooth 13 with slight impingement, permanence of tooth 53 and midline shift greater than

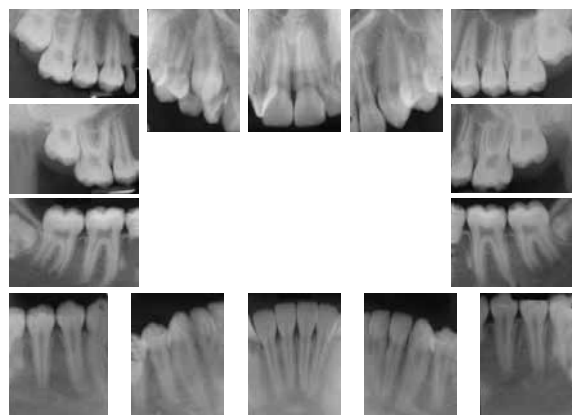


FIGURE 4 - Initial periapical radiographs.

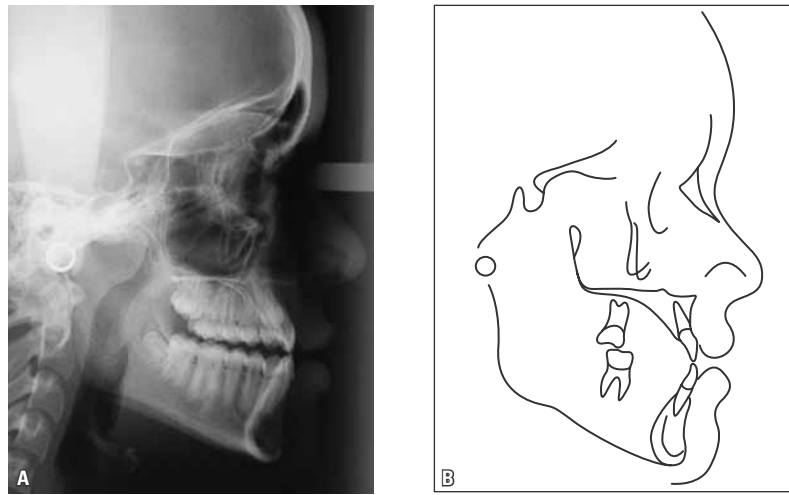


FIGURE 5 - Initial lateral cephalogram in CR (A), and cephalometric tracing (B).

3.5 mm to the right (Figs 1, 2). When in MIC, the Angle Class III malocclusion worsened with severe anterior and right lateral crossbite, as well as deep overbite (Fig 3).

The analysis of periapical radiographs revealed the presence of all permanent teeth, in addition to tooth 53, and the early formation of third molars. No changes capable of compromising orthodontic treatment were found (Fig 4).

The dental pattern featured retroclined lower incisors ($1-NB = 15.5^\circ$ and $IMPA = 84^\circ$), slightly protruding and inclined maxillary incisors ($1-NA = 6.5$ mm and $1-NB = 24$), which was consistent with her Class III malocclusion (Table 1).

Cephalograms in CR (Fig 5) exhibited a Class III skeletal pattern, especially due to maxillary retrusion ($WITS = -7$ mm; $ANB = -2^\circ$, with $SNA = 75^\circ$ and $SNB = 77^\circ$), with an increased lower facial third ($SN-GoGn = 34.5^\circ$; $FMA = 32^\circ$ and Y Axis = 67). It is noteworthy that these values were influenced by the end-on relation of the incisors during projection in CR. The cephalometric measurements can be evaluated in Table 1.

TREATMENT GOALS

Since this patient was still growing, the key

objective was to redirect mandibular growth, improving the relationship between the upper and lower lips. As regards the dental aspects, space was required for the correction of crowding, rotations and midline. The purpose was to maintain the inclination of maxillary incisors and enhance lower incisor inclination buccally, as well as achieve appropriate canine and molar relationships. From a skeletal standpoint, the aim was to reduce the anteroposterior discrepancy by maxillary protraction and redirection of mandibular growth with the purpose of enabling a more harmonious growth, expanding the upper arch and controlling the vertical direction of growth.

TREATMENT PLANNING

To attain the desired results, the patient and her parents were informed of the importance of compliance in wearing the appliances and the need to perform the treatment in two phases.

In the first phase, a removable "Skyhook" type appliance (600 g) would be used in conjunction with a Hyrax-type palatal expansion appliance with two daily activations to correct the crossbite. In addition to the expander, brackets would be

bonded to the upper incisors (Roth prescription, 0.022x 0.028-in slot) to start the alignment and leveling phase, and if necessary, slightly protrude these teeth.

In the second phase, the expander would be removed and a chin cup prescribed for night use. The complete fixed orthodontic appliance would be set up to proceed with alignment and leveling using 0.012-in nickel-titanium (NiTi) and 0.014-in to 0.020-in stainless steel archwires. If necessary, from the moment archwire progression reached 0.018-in archwires, Class III intermaxillary elastics would be used on the right side. Rectangular 0.019x0.025-in stainless steel archwires would then be used in both arches to finish the case. After the end of active treatment, a 0.8 mm lower fixed canine-to-canine lingual retainer would be bonded and in the upper arch a removable wraparound type appliance to be worn 24/7 for six months, and then nights only for six months. The patient and her parents were also informed in writing of the need for careful hygiene and proper care of the appliances to ensure the normal development of treatment and retention.

TREATMENT PROGRESS

Initially, bands were contoured for the first molars and an impression of the upper arch and chin were taken for fabrication of the appliances planned for the case. The Hyrax-type appliance was installed with two buccal extensions in the canine region for attachment of the protraction elastics, with a recommendation of two daily activations (0.5 mm per day). The Skyhook was also set up (to be used at least 16 hours per day), with a maxillary traction force of 300 g on each side (heavy 3/16-in elastics). The elastics were placed at an angle of 30° to the occlusal plane so as to offset a counterclockwise rotation likely to occur in the maxilla. Expansion proceeded as expected and after ten days of activation the screw was stabilized. After 21 days, Roth prescription straight wire metal brackets were bonded to the maxillary

incisors for leveling and alignment while creating space for tooth 13. Six months later, the expander and protraction appliance were removed. The patient's anterior and posterior crossbites were corrected, along with the dental Class III. At this point, the remaining upper and lower appliances were installed and the first NiTi 0.012-in archwire inserted for alignment and leveling. This was followed by a sequence of 0.014-in, 0.016-in, 0.018-in and 0.020-in stainless steel archwires. From this point on, Class III elastics began to be used (5/16-in with 200 g force) to control the Angle Class III malocclusion. In the lower arch interproximal stripping was performed on the incisors to correct the crowding. Next, rectangular 0.018x0.025-in archwires were used to correct the torque of tooth 12 and adjust its root position, which was palatally tipped. After the final correction of the torques with an ideal 0.019x0.025-in archwire and the assurance that the intended goals had been achieved, the brackets were removed and the retainer bonded. A lower bonded canine-to-canine retainer was made with 0.8 mm stainless steel wire and was used, along with an upper wraparound-type removable appliance, and the patient was instructed to wear the removable retainer 24 hours a day during the first six months and then nights only for another six months.

TREATMENT RESULTS

In evaluating the results (Figs 6 to 10) on completion of treatment and six years after removal of the appliance (Figs 11 to 15), one can observe that both the intended goals and the stability of treatment were rather successfully achieved. The posterior crossbite was corrected and the redirection of growth in the anteroposterior direction was also successful. In the mandible there was an increase of 1.5° in SNB, from 77° to 78.5° during treatment while the maxilla showed an increase of 2.5° in SNA, from 75° to 77.5°. Thus, there was an increase of 1° in the ANB, which rose from -2° to -1° (Fig 10, Table 1).

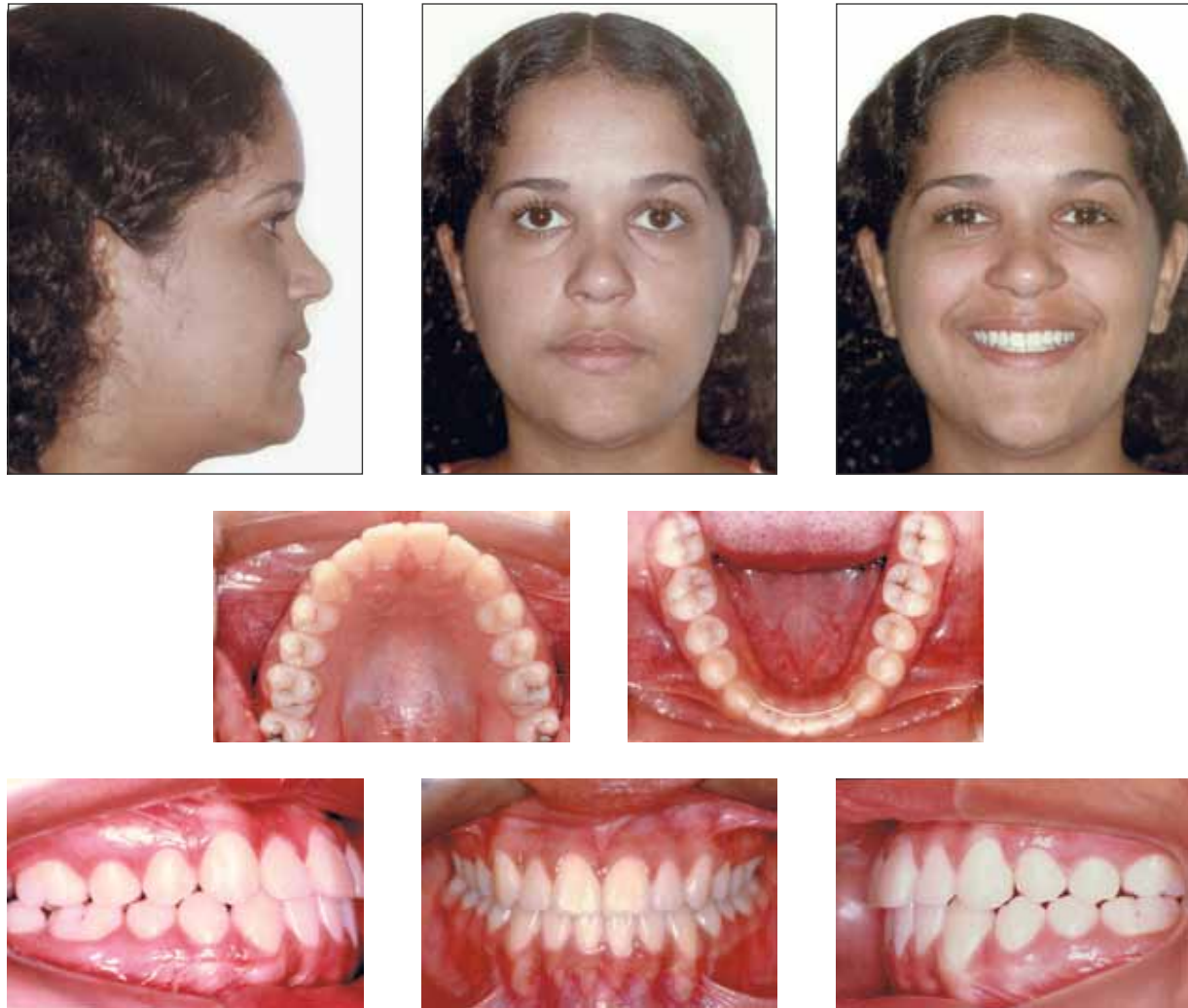

FIGURE 6 - Final facial and intraoral photographs.

The vertical dimension was controlled, maxillary position maintained and mandibular plane angle (SN-GoGn) decreased from 34.5° to 31° . Although it may seem a considerable decrease, it is important to remember that the first cephalometric radiograph was performed in CR, and in this position the incisors had an end-on relationship, which led to further opening of the mandibular plane. Regarding dental positions, appropriate alignment and leveling were attained as well as correction of the Angle Class III, crossbite, midline, overbite and overjet, in ad-

dition to establishing correct disocclusion guidance. Unfortunately, the upper incisors had to be tipped labially by 15° , from 24° to 39° . The upper molars however were moved mesially, providing normal occlusion according to Andrews' six keys. A slight intrusion of the maxillary incisors and small 4° lower incisor tipping toward labial, from 15.5° to 19° (Fig 10, Table 1) were also performed. Despite these changes, the intermolar and intercanine widths remained stable except for a slight 1 mm decrease in mandibular intermolar width (Table 1). The face exhib-

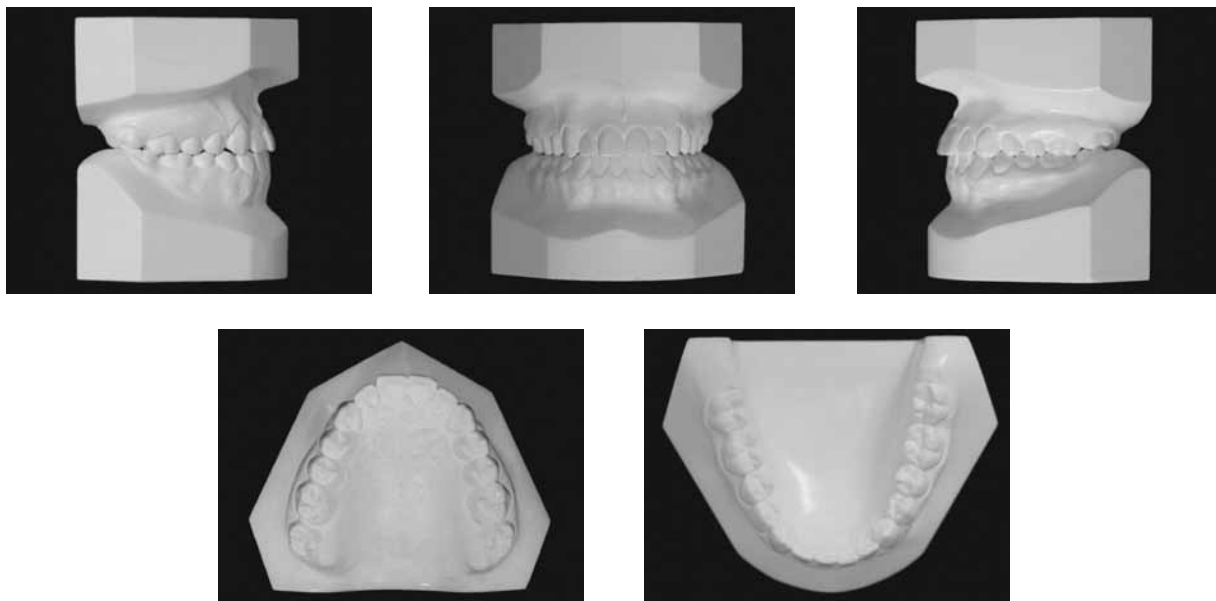


FIGURE 7 - Final models.

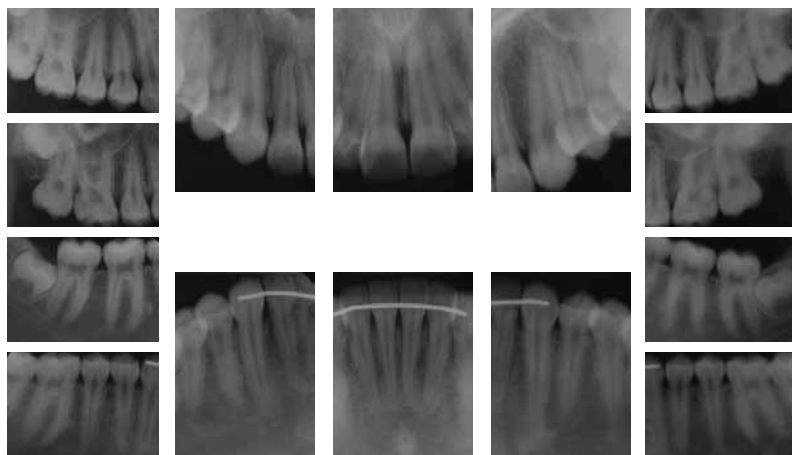


FIGURE 8 - Final periapical radiographs.

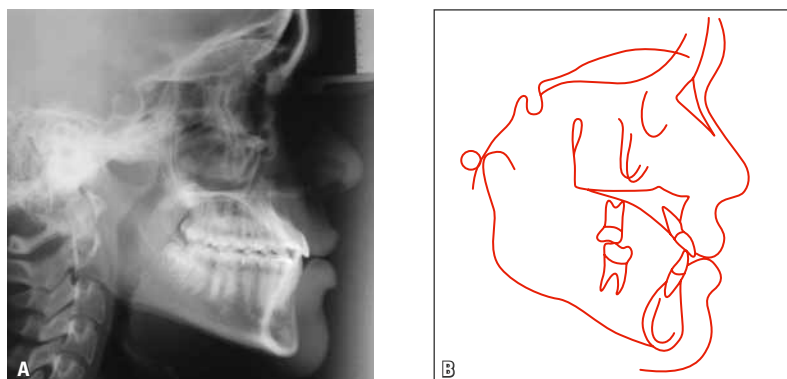


FIGURE 9 - Final lateral cephalogram (A) and cephalometric tracing (B).

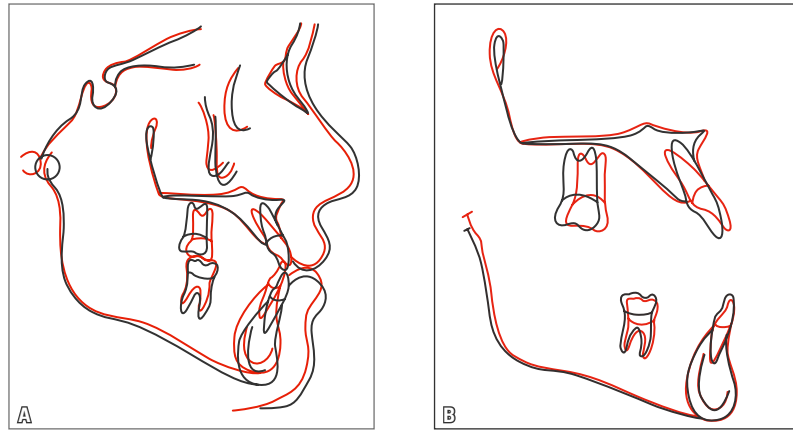


FIGURE 10 - Total (A) and partial (B) superimposition of initial (black) and final (red) cephalometric tracings.

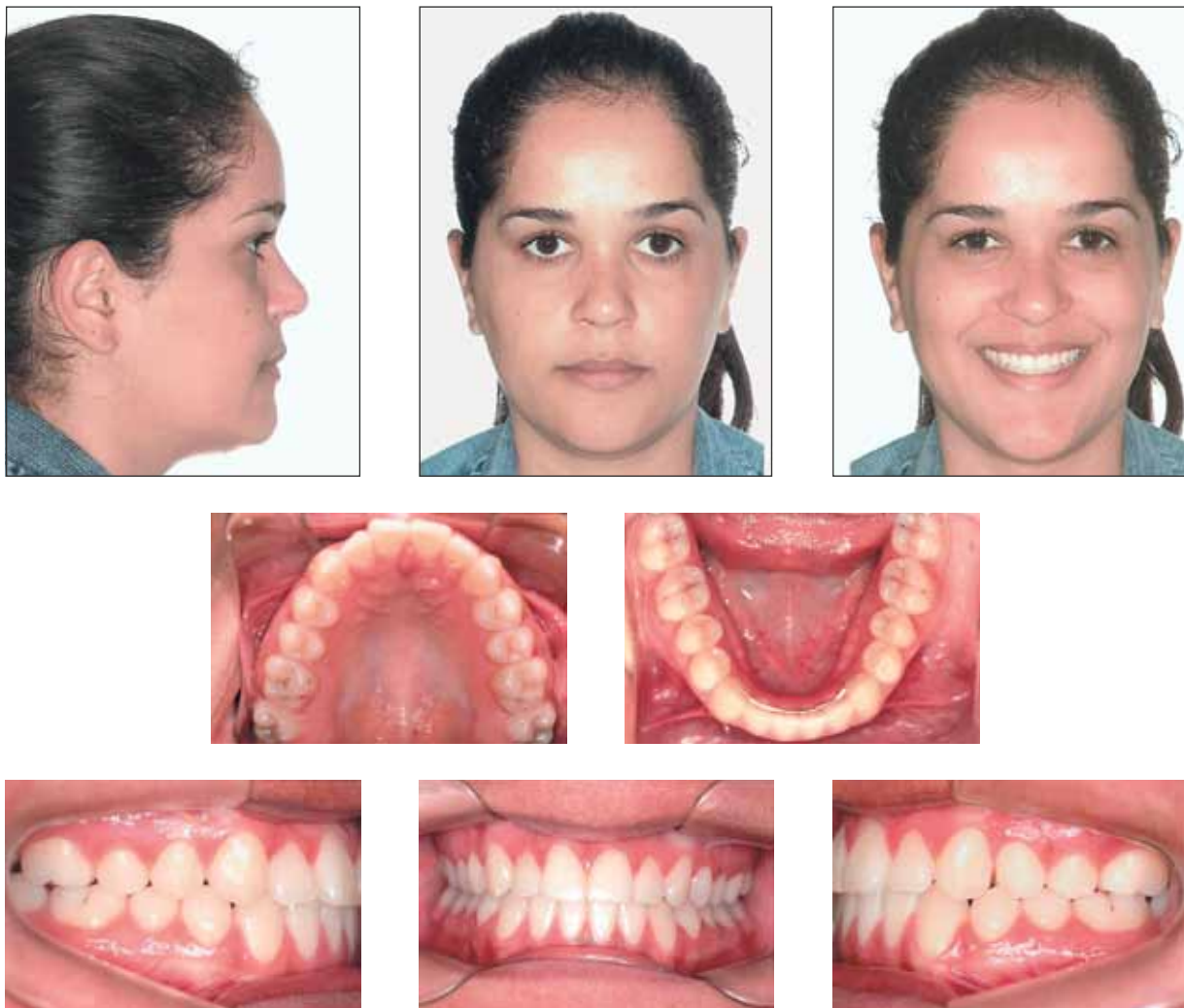

FIGURE 11 - Facial and intraoral follow-up photographs taken six years after treatment.

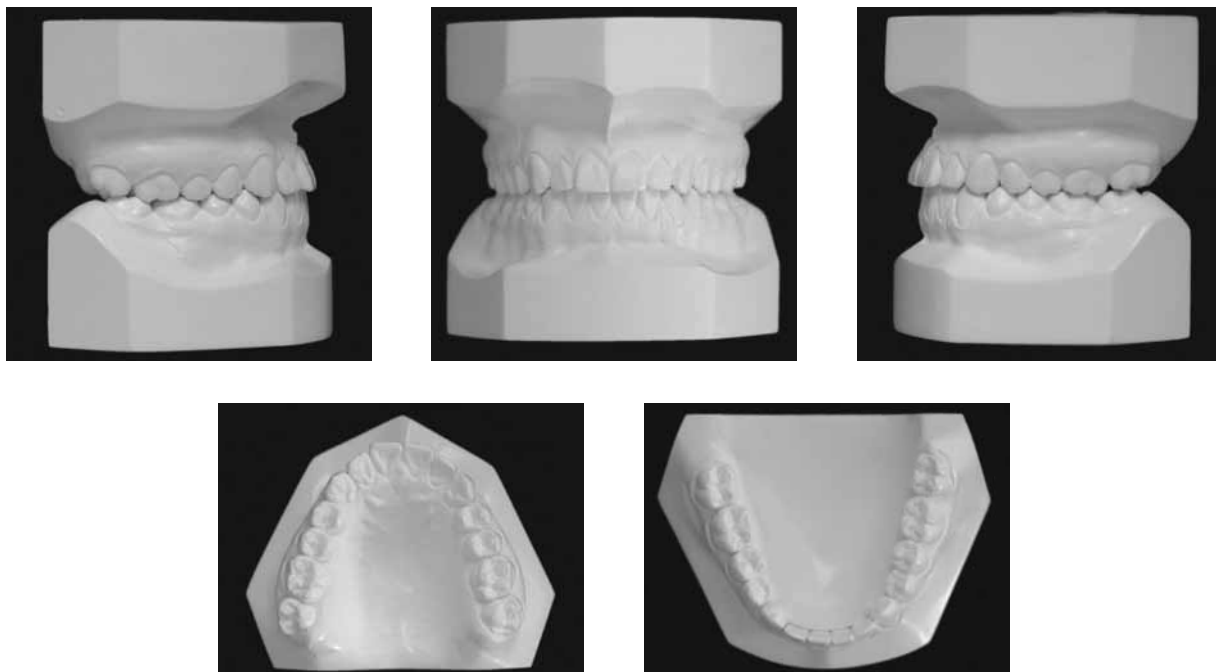


FIGURE 12 - Follow-up models six years after treatment.

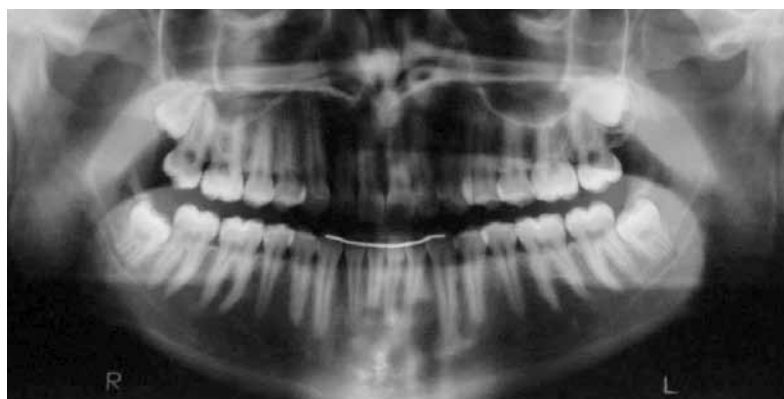

FIGURE 13 - Panoramic radiograph six years after treatment.

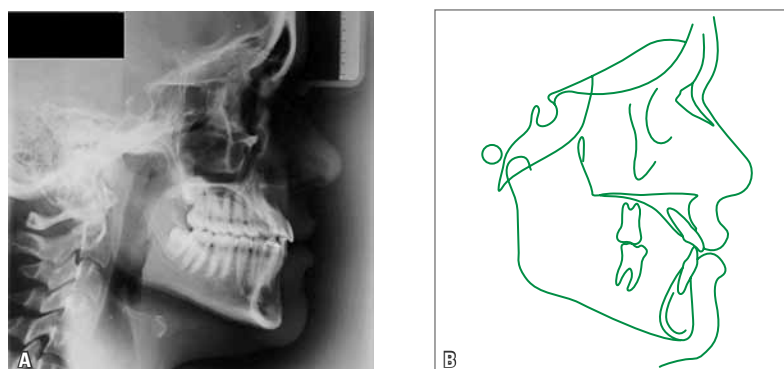


FIGURE 14 - Follow-up profile cephalometric radiograph (A) and cephalometric tracing (B) six years after treatment.

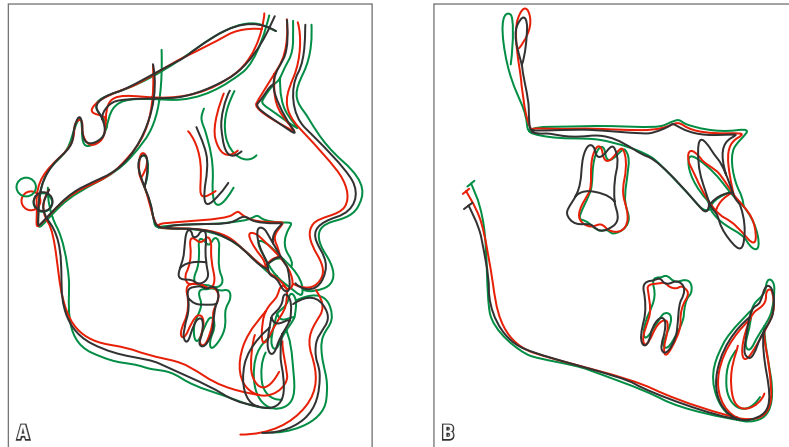


FIGURE 15 - Total (A) and partial (B) superimposition of initial (black), final (red) and follow-up (green) cephalometric tracings six years after treatment.

TABLE 1 - Summary of cephalometric measurements.

	MEASUREMENTS	Normal	A	B	Difference A/B	C
Skeletal Pattern	SNA (Steiner)	82°	75°	77.5°	2.5	77°
	SNB (Steiner)	80°	77°	78.5°	1.5	78°
	ANB (Steiner)	2°	-2°	-1°	1	-1°
	Convexity Angle (Downs)	0°	-4°	-4°	0	-3°
	Y-Axis (Downs)	59°	67°	62°	5	62°
	Facial Angle (Downs)	87°	80°	89°	9	84°
	SN-GoGn (Steiner)	32°	34.5°	31°	3.5	32.5°
	FMA (Tweed)	25°	32°	27°	5	26.5°
	IMPA (Tweed)	90°	84°	89°	5	88°
Dental Pattern	$\underline{1}$ - NA (degrees) (Steiner)	22°	24°	39°	15	40°
	$\underline{1}$ - NA (mm) (Steiner)	4 mm	6.5 mm	8 mm	1.5	7.5 mm
	$\bar{1}$ - NB (degrees) (Steiner)	25°	15.5°	19°	3.5	17.5°
	$\bar{1}$ - NB (mm) (Steiner)	4 mm	4 mm	3 mm	1	3.5 mm
	$\frac{1}{1}$ - Interincisal Angle (Downs)	130°	143°	126°	17	124°
	$\bar{1}$ - APo (mm) (Ricketts)	1 mm	2 mm	2 mm	17	1.5 mm
Profile	Upper Lip - S Line (Steiner)	0 mm	0 mm	0 mm	0	-1 mm
	Lower Lip - S Line (Steiner)	0 mm	1 mm	0.5 mm	3	0 mm
WITS	WITS	0 mm	-7 mm	-4 mm	3	-3 mm
	Intercanine Width	Upper Lower	NE 27 mm	34 mm 27 mm	— 0	34 mm 26.5 mm
	Intermolar Width	Upper Lower	53 mm 46 mm	53 mm 45 mm	0 1	54 mm 46 mm

ited a slight improvement in profile with a slight protrusion of the upper lip while chin position and vertical dimension were preserved. Regarding stability, it was noted that six years after completion of treatment the patient's occlusion was well established with well preserved molar and canine relationships, disocclusion guidance, adequate overbite and overjet, and facial aesthetics (Figs 11 and 12). From a cephalometric standpoint one can note that the measurements relating to the position of the maxilla and mandible underwent minor changes, consistent with the pattern of growth, while the dental measurements remained fairly stable (Fig 15, Table 1).

FINAL CONSIDERATIONS

Angle Class III malocclusion is difficult to plan and control as it may have a powerful genetic component.¹⁻¹⁰ Moreover, there are several other etiological factors to consider, such as poor individual tooth positions, mandibular overgrowth, inadequate maxillary growth, vertical problems or a combination of several of these factors.^{2,3,4,6} Planning should consider all these factors in addition to patient age to try to predict treatment outcome and stability.^{1,8,9} In this particular case, it is important to remember that cephalometric radiographs, photographs and initial models were performed in CR, which may have diminished

mandibular cephalometric measurements in an anteroposterior direction, and augmented them in terms of vertical relations, masking a more severe Class III. In MIC, the patient had a fully functional crossbite with the upper incisors being covered by their lower counterparts. The reason why all records were taken in CR was to show that even in CR the patient had indeed a genuine Angle Class III malocclusion relationship. Therefore, the goals were achieved, i.e. the molar relationship, anterior and posterior crossbites and midline shift were all corrected. The skeletal pattern also improved with greater maxillary growth in relation to the mandible, and although the cephalometric results showed only minor changes, one must remember again that the initial radiograph was performed in CR, which may have minimized the problem presented by the patient. However, in order to establish a correct relationship in the anterior region, the maxillary incisors had to be excessively tipped, in line with the compensatory treatment used for Class III malocclusion, which was intended in this case. Treatment stability, both esthetic and functional, was verified during a six-year follow-up period. There was slight extrusion of incisors and molars but the growth pattern remained fairly stable. It is thus possible to confirm that the mechanics used in this case was effective and well indicated.

REFERENCES

1. Angermann R, Berg R. Evaluation of orthodontic treatment success in patients with pronounced Angle Class III. *J Orofac Orthop.* 1999;60(4):246-58.
2. Brunetto AR. Má oclusão de Classe I de Angle, com tendência à Classe III esquelética, tratada com controle de crescimento. *Rev Dental Press Ortod Ortop Facial.* 2009 set-out;14(5):129-45.
3. Carlini MG, Miguel JAM, Goldner MTA. Tratamento precoce da má-oclusão Classe III de Angle com expansão rápida e uso de máscara facial: relato de um caso clínico. *Rev Dental Press Ortod Ortop Facial.* 2002 mar-abr;7(2):71-5.
4. Consolaro A, Consolaro MF. Expansão rápida da maxila e constrição alternadas (ERMC-ALT) e técnica de protração maxilar efetiva: extrapolação de conhecimentos prévios para fundamentação biológica. *Rev Dental Press Ortod Ortop Facial.* 2008 jan-fev;13(1):18-23.
5. Ferrer KJN, Cardoso GAS, Barone TY. Estudo cefalométrico pós-protração maxilar. *Ortodontia.* 2006 jan-mar;39(1):37-44.
6. Liou EJ, Tsai WC. A new protocol for maxillary protraction in cleft patients: repetitive weekly protocol of alternate rapid maxillary expansions and constrictions. *Cleft Palate Craniofac J.* 2005 mar;42(2):121-7.
7. Moraes ML, Martins LP, Maia LGM, Santos-Pinto A, Amaral RMP. Máscara facial versus aparelho Skyhook: revisão de literatura e relato de casos clínicos. *Ortodontia.* 2009 jul-set;41(3):209-21.
8. Prado E. Pergunte a um Expert. Questionando paradigmas no tratamento da Classe III em adultos. Qual seria o limite das compensações em pacientes adultos? Existe remodelação dentoalveolar ou o problema esquelético seria uma maldição? *Rev Clín Ortod Dental Press.* 2007 jun-jul;6(3):71-5.
9. Trankmann J, Lissou JA, Treutlein C. Different orthodontic treatment effects in Angle Class III patients. *J Orofac Orthop.* 2001 set;62(5):327-36.
10. Zentner A, Doll GM. Size discrepancy of apical bases and treatment success in angle Class III malocclusion. *J Orofac Orthop.* 2001 mar;62(2):97-106.

Submitted: July 2010
Revised and accepted: September 2010

Contact address

Sérgio Henrique Casarim Fernandes
Rua Henrique Surerus Sobrinho, 132
CEP: 36.036-246 – Juiz de Fora – MG, Brazil
E-mail: sergiocasarim@terra.com.br