

Effect of rapid maxillary expansion on the dimension of the nasal cavity and on facial morphology assessed by acoustic rhinometry and rhinomanometry

Carla Enoki Itikawa¹, Fabiana Cardoso Pereira Valera², Mirian Aiko Nakane Matsumoto³, Wilma Terezinha Anselmo Lima⁴

Objective: To assess the effects of rapid maxillary expansion on facial morphology and on nasal cavity dimensions of mouth breathing children by acoustic rhinometry and computed rhinomanometry.

Methods: Cohort; 29 mouth breathing children with posterior crossbite were evaluated. Orthodontic and otorhinolaryngologic documentation were performed at three different times, i.e., before expansion, immediately after and 90 days following expansion.

Results: The expansion was accompanied by an increase of the maxillary and nasal bone transversal width. However, there were no significant differences in relation to mucosal area of the nose. Acoustic rhinometry showed no difference in the minimal cross-sectional area at the level of the valve and inferior turbinate between the periods analyzed, although rhinomanometry showed a statistically significant reduction in nasal resistance right after expansion, but were similar to pre-treatment values 90 days after expansion.

Conclusion: The maxillary expansion increased the maxilla and nasal bony area, but was inefficient to increase the nasal mucosal area, and may lessen the nasal resistance, although there was no difference in nasal geometry. Significance: Nasal bony expansion is followed by a mucosal compensation.

Keywords: Palatal expansion technique. Mouth breathing. Malocclusion. Cephalometry.

¹ Professor of Specialization course in Orthodontics, Ribeirão Preto School of Dentistry, USP.

² Professor, Department of Otorhinolaryngology, Ribeirão Preto School of Medicine, USP.

³ Associate Professor, Department of Children Clinical Preventive Dentistry, Ribeirão Preto School of Dentistry, USP.

⁴ Associate Professor, Department of Otorhinolaryngology, Ribeirão Preto School of Medicine, USP.

How to cite this article: Itikawa CE, Valera FCP, Matsumoto MAN, Lima WTA. Effect of rapid maxillary expansion on the dimension of the nasal cavity and on facial morphology assessed by acoustic rhinometry and rhinomanometry. *Dental Press J Orthod.* 2012 July-Aug;17(4):129-33.

Submitted: March 03, 2010 - **Revised and accepted:** June 20, 2011

» The authors report no commercial, proprietary or financial interest in the products or companies described in this article.

Contact address: Carla Enoki Itikawa
Rua São Sebastião, 1442, apto. 161, Centro – Ribeirão Preto / SP – Brazil
CEP: 14.015-040 – E-mail: fa.ltada@uol.com.br

Efeito da expansão rápida da maxila na dimensão da cavidade nasal e morfologia facial pela rinometria acústica e rinomanometria

Carla Enoki Itikawa¹, Fabiana Cardoso Pereira Valera², Mirian Aiko Nakane Matsumoto³, Wilma Terezinha Anselmo Lima⁴

Objetivo: avaliar o efeito da expansão rápida da maxila na dimensão da cavidade nasal e na morfologia facial através da rinometria acústica e rinomanometria computadorizada.

Métodos: foram avaliadas 29 crianças na fase de dentição mista, portadoras de respiração bucal e mordida cruzada posterior. A documentação ortodôntica e a avaliação otorrinolaringológica foram realizadas em três tempos – antes da expansão rápida da maxila, imediatamente após e 90 dias depois.

Resultados: a expansão promoveu um aumento na dimensão da cavidade nasal e na maxila transversalmente. Contudo, não houve diferenças significativas na área da mucosa nasal. A rinometria acústica mostrou que não houve diferenças na área de secção transversa ao nível da válvula e concha nasal inferior; entretanto, a rinomanometria mostrou diferenças estatisticamente significativas na resistência nasal, que diminuiu após a expansão rápida da maxila.

Conclusões: a expansão maxilar aumenta a área óssea maxilar e nasal; contudo, esse aumento não foi suficiente para aumentar a área da mucosa e diminuir a resistência nasal. Importância: a expansão óssea nasal foi seguida por uma compensação da mucosa.

Palavras-chave: Respiração bucal. Técnica de expansão palatina. Circunferência craniana. Má oclusão.

¹ Professora da Especialização em Ortodontia na Faculdade de Odontologia de Ribeirão Preto – USP.

² Professora do Departamento de Otorrinolaringologia da Faculdade de Medicina de Ribeirão – USP.

³ Professora Associada do Departamento de Clínica Infantil da Faculdade de Odontologia de Ribeirão Preto – USP.

⁴ Professora Associada do Departamento de Otorrinolaringologia, da Faculdade de Medicina de Ribeirão – USP.

Como citar este artigo: Itikawa CE, Valera FCP, Matsumoto MAN, Lima WTA. Effect of rapid maxillary expansion on the dimension of the nasal cavity and on facial morphology assessed by acoustic rhinometry and rhinomanometry. *Dental Press J Orthod.* 2012 July-Aug;17(4):129-33.

Enviado em: 3 de março de 2010 - **Revisado e aceito:** 20 de junho de 2011

» Os autores declaram não ter interesses associativos, comerciais, de propriedade ou financeiros que representem conflito de interesse nos produtos e companhias descritos nesse artigo.

Endereço para correspondência: Carla Enoki Itikawa
Rua São Sebastião, 1442, apto. 161, Centro – Ribeirão Preto / SP
CEP: 14.015-040 – E-mail: fa.ltda@uol.com.br

INTRODUCTION

Mouth breathing alters facial muscles and bones.¹⁶ Mouth breathing children present maxillary atresia and dentoalveolar changes associated to hypotonia in tongue, lips and cheeks. These changes, in turn, lead to: 1) compression of the alveolar processes,¹⁷ 2) retrusion of the nasal cavity and of paranasal sinuses, 3) increase of anterior facial height and of palatal and mandible planes,¹⁵ and 4) maxillary and mandible retrusion.

Rapid maxillary expansion is one of the most frequently used techniques in orthodontics to correct the atresia in superior dental arch and palate, as well as posterior crossbite with normal inclination of the teeth.¹⁴ Its success is mostly affected by the age of activation (best between 7 and 10 years of age),¹¹ and the breathing pattern of the patient.

The objectives of the present study were to determine the morphological pattern of the face and the nasal area, and resistance on mouth breathing children with mixed dentition before and after rapid maxillary expansion by acoustic rhinometry and computed rhinomanometry.

MATERIAL AND METHODS

Twenty-nine mouth breathing patients of both genders, with ages ranging from 7 to 10 years, were studied. The patients were in the mixed dentition phase and had uni- or bilateral posterior crossbite including the deciduous canines and molars and the first permanent molars.

The children were evaluated and diagnosed as mouth breathers by the same otorhinolaryngologist, at the Service of Pediatric Rhinosinusology, Division of Otorhinolaryngology, School of Medicine of Ribeirão Preto, USP.

After the first evaluation, all the children underwent acoustic rhinometry (ARM) and rhinomanometry (RMM). For these exams, the patients remained in an acoustic-treated room, with a constant temperature of 25° C for 15 minutes. Topical vasoconstrictor was not administered previously to these exams, since the objective of these studies was to observe mucosal changes to the bone expansion. SR2000 equipment, Rhinometrics, (Denmark) with nasal adaptors were used to analyze the results.¹⁸

For ARM, the minimal cross-sectional area (MCA) 1 (corresponding to nasal valve) and 2 (corresponding

to inferior turbinate) were examined for each nostril. In RMM, the resistance during both inspiration and expiration was verified for each nostril.

Complete orthodontic documentation (lateral and posteroanterior cephalometric radiographs, study models, extraoral front and profile photographs, and intraoral photographs) was also obtained.

The following measurements were made in the posteroanterior radiographs (Fig 1): NC-NC, which corresponds to the nasal width,^{10,12} JL-JR, which corresponds to the maxillary width,^{10,12} JL-ZAgL, which corresponds to the maxillary-mandibular width left side, and JR-ZAgR which corresponds to the maxillary-mandibular width right side.

After analysis of the initial documentation and planning of orthodontic treatment, tooth- and mucosa-supported orthodontic braces - Haas disjunctor - were placed to correct uni- or bilateral crossbite. The braces were installed and activated according to the principles presented by Haas.⁴ Briefly, patients were instructed to activate their

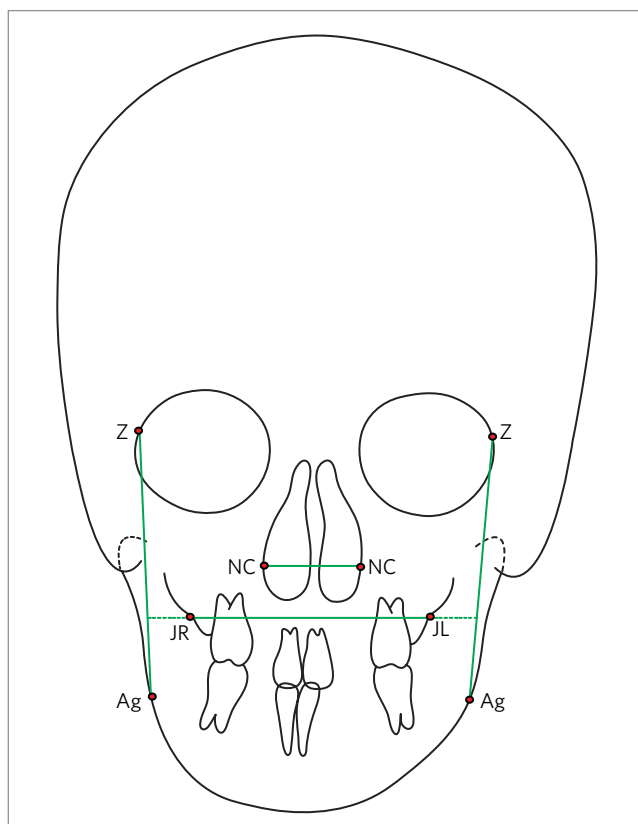


Figure 1 - Cephalometric tracing of the posteroanterior radiography.

RME twice daily until posterior crossbite was corrected (observed when superior first molars were naturally opposed to inferior ones). After retention period (90 days), Haas disjunctor was replaced to a superior functional appliance, stabilizing the occlusion and peri-oral muscles.

The RMM, ARM and cephalometric exams were performed before (T_1), immediately after (T_2) and 90 days after (T_3) rapid maxillary treatment.

The Hottelling T_2 test was used to compare the mean values of each variable at the three time points in the study.

The present study was approved by the Research Ethics Committee of the Dental School of Ribeirão Preto, University of São Paulo (process n° 2003.1.25.58.0), and all the patients' parents gave written informed consent to participate in the study.

RESULTS

The results in ARM and RMM are presented in Tables 1, 2 and 3. There was a reduction in nasal resistance immediately after nasal expansion, which returned to pretreatment levels 90 days after RME. There was no statistical difference between times for MCA 1 and 2.

The results of each cephalometric variable obtained at the three time points in the study are presented in Tables 4 and 5. There was a significant increase in lateral width of nasal bone (NC-NC), maxilla (JL-JR), JL-ZAgL, and JR-ZAgR. Mean NC-NC, JL-JR, JL-ZAgL and JR-ZAgR differed significantly between T_1 and T_2 and between T_1 and T_3 , but not between T_2 and T_3 .

DISCUSSION

Posterior crossbite is considered to be one of the most common malocclusions³ and its prevalence is approximately 8% in the deciduous dentition⁸ and 27%⁹ in mixed dentition. This condition tends to get worse during facial growth, and rapid maxillary expansion should be instituted as early as possible.

In the present study, mouth breathing children were selected after been diagnosed by an otorhinolaryngologist after the clinical examination, including nasoendoscopy. All of them also presented uni- or bilateral posterior crossbite associated to palatal atresia. The use of the Haas disjunctor was

indicated with the specific objective of promoting orthopedic expansion of the maxilla in order to correct the posterior crossbite. Weekly monitoring of the activators was done during this procedure in order to avoid excessive expansion.

Frontal radiographs revealed an skeletal increase in the lateral dimension of the nasal cavity and maxillary bone after palatal disjunction, and this increase was stable 90 days after correction. These results agree with those reported by other authors.^{10,2,6} The bone corrections are more easily achieved if treatment is initiated before complete

Table 1 - Mean values and standard deviations of acoustic MCA 1 and 2 before orthodontic treatment, immediately after and 90 days after treatment, calculated F value and value of the Hotelling T_2 test for equality of the means.

Measure	Time	Mean	Standard deviation	F _{2,27}	Test value
MCA 1	T_1	0.987	0.191	0.596	0.558
	T_2	1.006	0.182		
	T_3	0.973	0.196		
MCA 2	T_1	0.732	0.223	1.025	0.372
	T_2	0.780	0.200		
	T_3	0.763	0.248		

Table 2 - Mean values and standard deviations of resistance during inspiration and expiration before orthodontic treatment, immediately after and 90 days after treatment, calculated F value and value of the Hotelling T_2 test for equality of the means.

Measure	Time	Mean	Standard deviation	F _{2,27}	Test value
Inspiration	T_1	3.368	1.226	11.570	< 0.001
	T_2	2.859	1.460		
	T_3	2.231	0.763		
Expiration	T_1	2.675	0.943	10.064	0.000
	T_2	2.271	1.365		
	T_3	1.828	0.599		

Table 3 - Mean values and standard deviations of differences between respiratory measures in two different moments, and Bonferroni's value for multiple comparisons.

Measure	Time	Mean of Differences	Standard error	Test value
Inspiration	$T_1 - T_2$	-0.509	0.368	0.535
	$T_1 - T_3^*$	-1.136	0.261	< 0.001
	$T_2 - T_3$	-0.628	0.266	0.076
Expiration	$T_1 - T_2$	-0.404	0.310	0.612
	$T_1 - T_3^*$	-0.846	0.201	0.001
	$T_2 - T_3$	-0.442	0.239	0.225

Table 4 - Linear orthodontic measurements (mean and standard deviation) made before, immediately after and 90 days after rapid maxillary expansion, calculated F value and value of the Hotelling T_2 statistical test for equality of the means.

Measure	Period	Mean	Standard deviation	F _{2,27}	Test value
NC-NC	T ₁	24.91	1.88	47.048	< 0.001
	T ₂	26.21	1.68		
	T ₃	26.38	1.93		
JL-JR	T ₁	58.86	2.71	48.190	< 0.001
	T ₂	62.38	2.53		
	T ₃	62.10	2.65		
JL-ZAgL	T ₁	11.24	1.77	13.90	< 0.003
	T ₂	10.28	1.56		
	T ₃	10.17	1.53		
JR-ZAgR	T ₁	11.93	1.73	13.90	< 0.003
	T ₂	11.07	1.79		
	T ₃	10.75	1.90		

Table 5 - Mean values and standard deviations of differences between linear orthodontic measurements between two different moments and Bonferroni's value for multiple comparisons.

Measure	Time	Mean of differences	Standard error	Test value
NC-NC	T ₁ - T ₂ *	1.293	0.218	< 0.001
	T ₁ - T ₃ *	1.466	0.149	< 0.001
	T ₂ - T ₃	0.172	0.165	0.916
JL-JR	T ₁ - T ₂ *	3.517	0.370	< 0.001
	T ₁ - T ₃ *	3.241	0.339	< 0.001
	T ₂ - T ₃	-0.276	0.216	0.635
JL-ZAgL	T ₁ - T ₂ *	-0.860	0.160	< 0.005
	T ₁ - T ₃ *	-1.170	0.160	< 0.039
	T ₂ - T ₃	-0.310	0.080	0.999
JR-ZAgR	T ₁ - T ₂ *	-0.970	0.160	< 0.029
	T ₁ - T ₃ *	-1.070	0.170	< 0.000
	T ₂ - T ₃	-1.030	0.050	0.351

* Significant difference ($p < 0.05$).

permanent dental eruption, when calcification of the craniofacial sutures is not achieved, and maxillary expansion is consequently easier.

The importance of respiratory function for facial and occlusal development has become clear in Orthodontics.⁷ For this reason, quantifying methods for nasal patency are important to better understand its influence on orthodontic measures.

The radiological results showed that rapid maxillary expansion increased the bony nasal cavity

(confirmed by the cephalometric measures NC-NC), and on maxilla, evaluating by JL-ZAgL, and JR-ZAgR. We could observe that, although there was a significant increase in bony width of nasal cavity and maxilla and slight decrease of nasal resistance, there was not an increase in mucosal nasal cavity.

Bicakci et al¹ also evaluated the effects of rapid maxillary expansion on nasal cavity by acoustic rhinometry. Instead of our results, they observed an increase in MCA after rapid maxillary expansion. In the present study we did not detect significant differences in minimal cross-sectional area, neither in the region of the nasal valve nor in the inferior turbinate at the three time points studied.

Our results suggest that there is an increase of transverse width of maxilla and nasal cavity, which leads to lateralization of inferior turbinates. However, differently from other studies, this bony lateralization induced a mucosal compensation, and the improvement in nasal mucosa was not so marked as bony expansion. We believe that is "compensation" could be due to edema or hypertrophy of inferior turbinates, for example.

Hartgerink et al⁵ evaluated a sample of 38 patients aged 7.5 to 22.3 years treated with a Haas disjunctor or an occlusal splint by rhinomanometry at the same time points as used in the present study, but after nasal decongestion. Hershey et al⁶ studied 17 patients aged 11 to 14 years treated with a Haas disjunctor, and Timms¹³ evaluated 26 patients aged 10 to 19, with and without the use of a nasal decongestion and with rhinomanometry before and after expansion in both series. All investigators detected a reduction in nasal resistance after expansion.

In agreement with these authors, the results of the present study showed that mean nasal resistance during inspiration (inspiration at T₃ = 2.231 l m/cm H₂O) and expiration (expiration at T₃ = 1.828 l m/cm H₂O) were significantly lower after treatment than before treatment (inspiration at T₁ = 3.368 l m/cm H₂O and expiration at T₁ = 2.675 l m/cm H₂O).

Our results may differ from others because we opted not to use topical vasoconstrictor while performing the RMM and ARM. As we had already the bony dimension through cephalometry, and we wanted to observe the mucosal response to this bony expansion, we opted not to use vasoconstrictor.

Orthodontists indicate and perform expansion in order to correct uni- or bilateral crossbite, believing that it also relieves the respiratory difficulties in these patients. However, the results of the present study do not support that rapid maxillary expansion could be employed merely in order to improve nasal function of individuals with respiratory difficulties.

The present study detected an increase in the bony dimension of the nasal cavity and a significant decrease in nasal resistance, although there was no significant difference in MCA on nasal valve or inferior turbinate. Even though, the results of the present study do not support the indication of rapid maxillary expansion

merely in order to provide benefits for the nasal function of individuals with respiratory difficulties, since mucosal benefits were much slighter than bony ones.

CONCLUSION

On the basis of the present results, it was possible to conclude that there was a significant increase in nasal and maxillary transversal bony width. These bony changes were followed by discrete alterations in nasal resistance, and no difference in nasal volume was detected, showing that the mucosal changes are slighter than bony ones when maxillary expansion is employed.

REFERENCES

- Bicakci A, Agar U, Sökücü O, Babacan H, Doruk C. Nasal airway changes due to rapid maxillary expansion timing. *Angle Orthod.* 2005;75:1-6.
- Chung C, Font B. Skeletal and dental changes in the sagittal, vertical and transverse dimensions after rapid palatal expansion. *Am J Orthod Dentofacial Orthop.* 2004;126:569-75.
- Erdinç AE, Uğur T, Erba YE. A comparison of different treatment techniques for posterior crossbite in mixed dentition. *Am J Orthod Dentofacial Orthop.* 1999;116:287-300.
- Haas AJ. Palatal expansion: just the beginning of dentofacial orthopedics. *Am J Orthod Dentofacial Orthop.* 1970;57:219-55.
- Hartgerink DV, Vig PS, Abbot DW. The effect of rapid maxillary expansion on nasal airways resistance. *Am J Orthod Dentofacial Orthop.* 1987;92(5):274-84.
- Hershey HG, Stewart BL, Warren DW. Changes in nasal airway resistance associated with rapid maxillary expansion. *Am J Orthod Dentofacial Orthop.* 1976;69:274-84.
- Holmberg H, Linder-Aronson S. Cephalometric radiographs as a means of evaluating the capacity of nasal and nasopharyngeal airway. *Am J Orthod Dentofacial Orthop.* 1979;76:479-90.
- Kutin G, Hawes RR. Posterior crossbites in the deciduous and mixed dentitions. *Am J Orthod.* 1969;56:491-504.
- Sandıkçoglu M, Hazar S. Skeletal and dental changes after maxillary expansion in the mixed dentition. *Am J Orthod Dentofacial Orthop.* 1997;111:321-27.
- Sari Z, Uysal T, Usumez S, Basciftci FA. Rapid maxillary expansion. Is it better in the mixed or in the permanent dentition. *Angle Orthod.* 2003;73:654-61.
- Sfondrini G, Gandini P, Piacentino G, Galio S, Colombo L. Modificazione della ventilazione nasale dopo disgiunzione palatale rapida. *Mondo Ortod.* 1986;11:39-45.
- Silva Filho OM, Montes LAP, Torelly LF. Rapid maxillary expansion in the deciduous and mixed dentition evaluated through posteroanterior cephalometric analysis. *Am J Orthod Dentofacial Orthop.* 1995;107:268-75.
- Timms DJ. The reduction of nasal airway resistance by rapid maxillary expansion and its effect on respiratory disease. *J Laryngol Otol.* 1984;98:357-62.
- Tourne LPM, Schweiger J. Immediate postural responses to total nasal obstruction. *Am J Orthod Dentofacial Orthop.* 1996;110:606-11.
- Trotman CA, McNamara JA, Dibbets JMH, Van Der Weele Lt. Association of lip posture and the dimensions of the tonsils and sagittal airway with facial morphology. *Angle Orthod.* 1997;67:425-32.
- Valera FCP, Trawitzki LVV, Anselmo-Lima WT. Myofunctional evaluation after surgery for tonsils hypertrophy and its correlation to breathing pattern: a 2-year follow up. *Int J Pediatr Otorhinolaryngol.* 2006;70:221-5.
- Woodside DG, Linder-Aronson S, Lundström A, McWilliam J. Mandibular and maxillary growth after changed mode of breathing. *Am J Orthod Dentofacial Orthop.* 1991;100:1-18.
- Zancanella E, Lima WTA. Uso da rinometria acústica como método diagnóstico. *Rev Bras Otorrinolaryngol.* 2004 Jul-Ago;70(4):500-3.