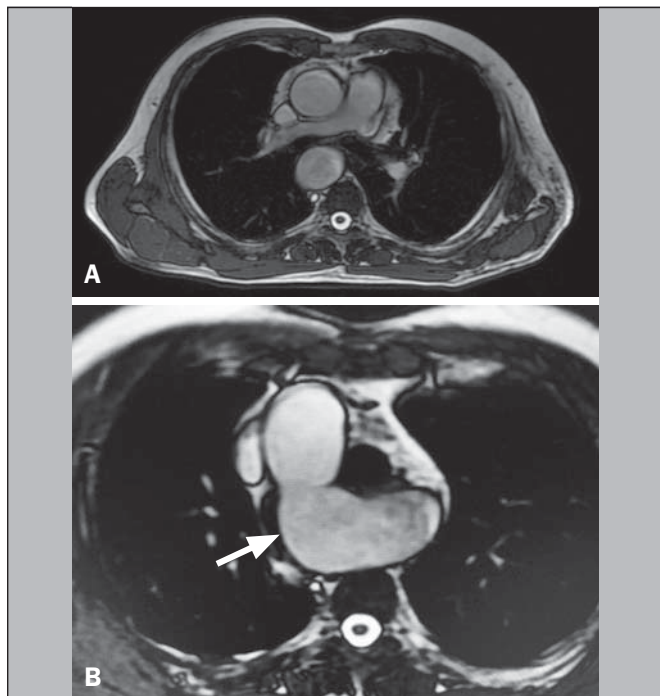
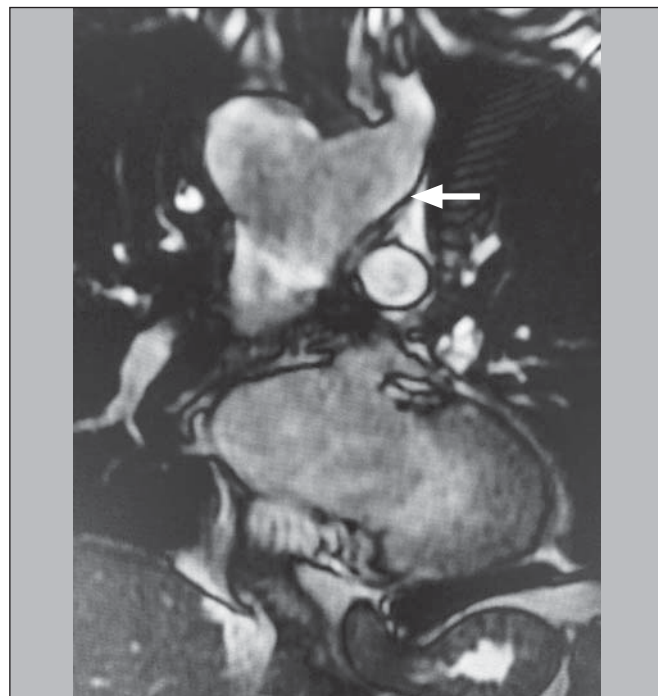
**Figure 1. A,B:** Axial T2-weighted spin-echo magnetic resonance imaging showing right aortic arch (arrow).



**Figure 2.** Coronal T2-weighted spin-echo magnetic resonance imaging showing Kommerell's diverticulum (arrow).

**REFERENCES**

1. Neves PO, Andrade J, Monção H. Coronary anomalies: what the radiologist should know. *Radiol Bras.* 2015;48:233–41.
2. Herrero Lara JA, de Araújo Martins-Romão D, Caparrós Escudero C, et al. Hybrid treatment of penetrating aortic ulcer. *Radiol Bras.* 2015;48:192–4.
3. Batista MN, Barreto MM, Cavaguti RF, et al. Pulmonary artery sarcoma mimicking chronic pulmonary thromboembolism [Letter]. *Radiol Bras.* 2015;48:333–4.
4. Amaral RH, Souza VVS, Nin CS, et al. Aortic lesion simulating pulmonary disease: a case report. *Radiol Bras.* 2014;47:320–2.
5. Araújo Neto CA, Andrade ACO, Badaró R. Intima-media complex in the investigation of atherosclerosis in HIV-infected patients [Letter]. *Radiol Bras.* 2014;47(1):x.
6. Sprong DH, Cutler NL. A case of human right aorta. *Anat Rec.* 1930;45:365–75.
7. Fauz RA, Furlan S, Barros AS, et al. Arco aórtico direito com artéria subclávia esquerda aberrante e divertículo de Kommerell. *Radiol Bras.* 2005;38:381–4.
8. Edwards JE. Anomalies of the derivatives of the aortic arch system. *Med Clin North Am.* 1948;32:925–49.

9. Costa RN, Andrade IS, Reyes RO, et al. Arco aórtico direito com divertículo de Kommerell. *Rev Bras Cardiol Invas.* 2009;17:279–80.
10. Kimura-Hayama ET, Meléndez G, Mendizábal AL, et al. Uncommon congenital and acquired aortic diseases: role of multidetector CT angiography. *Radiographics.* 2010;30:79–98.
11. Tanaka A, Milner R, Ota T. Kommerell's diverticulum in the current era: a comprehensive review. *Gen Thorac Cardiovasc Surg.* 2015;63:245–59.
12. Barranhas AD, Indiani JM, Marchiori E, et al. Atypical presentation of Kommerell's diverticulum. *Arq Bras Cardiol.* 2009;93:e88–90, e101–3.
13. Barranhas AD, Santos AASMD, Coelho-Filho OR, et al. Cardiac magnetic resonance imaging in clinical practice. *Radiol Bras.* 2014;47:1–8.

**Alexandre Ferreira Silva<sup>1</sup>, José Antônio dos Santos<sup>2</sup>**

1. Ecotomo S/C Ltda., Belém, PA, Brazil. 2. Dimagem – Diagnóstico por Imagem, Belém, PA, Brazil. Mailing address: Dr. Alexandre Ferreira Silva. Rua Bernal do Couto, 93/1202, Umarizal. Belém, PA, Brazil, 06055-080. E-mail: alexandreecotomo@oi.com.br.

<http://dx.doi.org/10.1590/0100-3984.2015.0087>

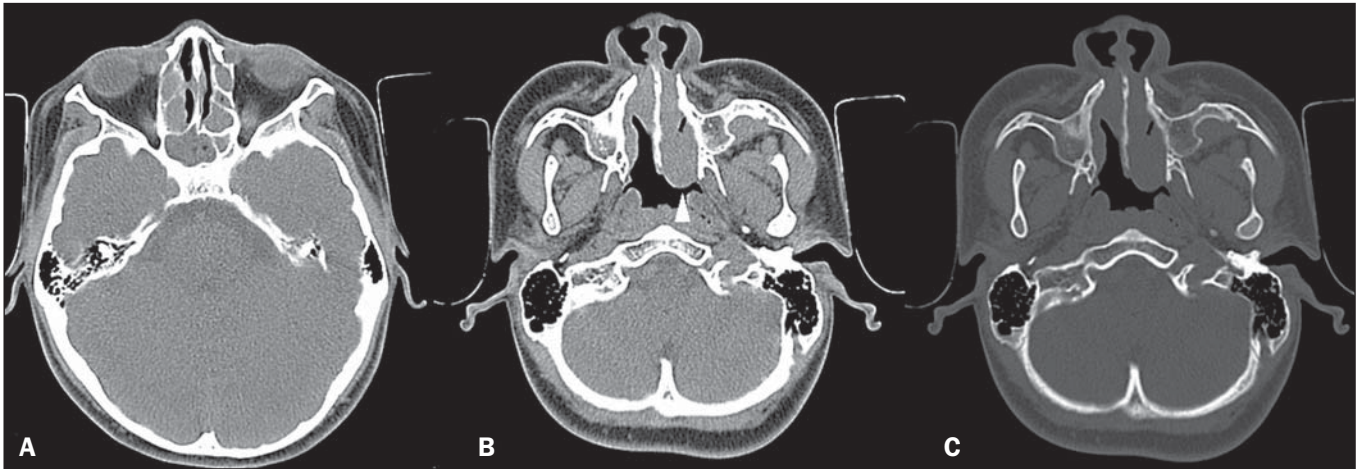
**Rosai-Dorfman disease affecting the nasal cavities and paranasal sinuses**

Dear Editor,

Here, we report the case of a 17-year-old male who presented with a three-month history of nasal obstruction, asthenia, and febrile episodes. Physical examination revealed bilateral enlargement of cervical and axillary lymph nodes, all of which were painless on palpation. Laboratory tests showed mild leukocytosis, an elevated increased C-reactive protein level, and a high erythrocyte sedimentation rate. The venereal disease research laboratory test and monospot test were both negative, as was serology for HIV, toxoplasmosis, and cytomegalovirus. Computed tomography (CT) of the sinuses showed multiple, homogeneous, hypointense, rounded polypoid masses, which effectively narrowed the nasal

passages, together with opacification of the ethmoid cells and sphenoid sinuses, with no evidence of bone erosion (Figure 1). Biopsies of a cervical lymph node and nasal lesions were negative for neoplasia and acid-fast bacilli, showing diffuse lymphoplasmacytic infiltration, foamy histiocytes, and emperipolesis. Immunohistochemistry showed positivity for S-100 protein, positivity for CD68, and negativity for CD1a. A diagnosis of Rosai-Dorfman disease was made, and corticosteroid therapy was started, resulting in slow, progressive improvement.

Recent studies in the radiology literature of Brazil have stressed the importance of CT and magnetic resonance imaging (MRI) in improving the diagnosis of head and neck masses<sup>(1–5)</sup>. Rosai-Dorfman disease, also known as sinus histiocytosis with massive lymphadenopathy, is a rare, benign lymphoproliferative, usually self-limiting, condition characterized by bilateral, painless cervical



**Figure 1.** **A:** Axial CT section without contrast, showing opacification of the sphenoid sinuses and ethmoid cells by hypointense material. **B:** Axial CT section without contrast, showing a homogeneous, hypointense polypoid formation (arrowhead) in the left nasal cavity. **C:** Axial CT section, with a bone window setting, showing that there is no associated bone erosion.

lymphadenopathy<sup>(6–11)</sup>, with spontaneous resolution in approximately half of all cases<sup>(7)</sup>. The disease has a slight predilection for males and primarily affects children, adolescents, and young adults, 80% of cases occurring in individuals under 20 years of age<sup>(6)</sup>. Extranodal involvement occurs in 30–40% of all cases<sup>(6,8,9)</sup>, being most common in immunocompromised individuals and preferentially affecting the skin, respiratory tract, reticuloendothelial system, genitourinary tract, or bones<sup>(6,8,9)</sup>. Although uncommon, enlargement of the mediastinal, hilar, axillary, and inguinal lymph nodes can occur.

The etiology of Rosai-Dorfman disease is unclear, although it could be related to changes in the immune response or to infections caused by agents such as varicella-zoster virus and other herpes viruses, as well as Epstein-Barr virus, cytomegalovirus, *Brucella* spp., and *Klebsiella* spp.<sup>(6,7,9,11)</sup>

Imaging tests such as CT and MRI are useful for evaluating the extent of Rosai-Dorfman disease, although there are no specific characteristics. When it affects the paranasal sinuses, it typically manifests as polypoid masses, mucosal thickening, with or without bone erosion, with preferential involvement of the maxillary sinuses and ethmoid cells<sup>(9,10)</sup>. The diagnosis is established by histopathology<sup>(8)</sup>.

The differential diagnoses include several types of lymphoreticular malignancy, such as lymphoma, malignant histiocytosis, and monocytic leukemia, which have histopathological features similar to those of Rosai-Dorfman disease but present atypia and a rapid, aggressive evolution. Another major differential diagnosis is Kikuchi-Fujimoto disease (histiocytic necrotizing lymphadenitis), the clinical profile of which resembles that of Rosai-Dorfman disease, with cervical lymphadenopathy, although the former predominantly affects females and manifests as necrotizing histiocytosis on histopathology<sup>(12,13)</sup>.

In Rosai-Dorfman disease, the treatment modality of choice and the timing of treatment are controversial. Nevertheless, the choice of treatment strategies depends on the severity of the disease, mild cases being managed with observation only, whereas cases that are more severe are typically managed with corticosteroid therapy, chemotherapy, radiotherapy, or surgery<sup>(6–11)</sup>.

In conclusion, although Rosai-Dorfman disease does not present specific imaging characteristics, it should be considered among the diagnostic possibilities in cases of painless bilateral cervical lymphadenopathy, particularly in children and adolescents.

## REFERENCES

- Niemeyer B, Marchiori E. Giant pilomatrixoma: conventional and diffusion-weighted magnetic resonance imaging findings [Letter]. *Radiol Bras.* 2015;48:63–4.
- Niemeyer B, Salata TM, Antunes LO, et al. Desmoplastic fibroma with perineural spread: conventional and diffusion-weighted magnetic resonance imaging findings [Letter]. *Radiol Bras.* 2015;48:266–7.
- Alfenas R, Niemeyer B, Bahia PRV, et al. Parry-Romberg syndrome: findings in advanced magnetic resonance imaging sequences – case report. *Radiol Bras.* 2014;47:186–8.
- Feres MFN, Hermann JS, Sallum AC, et al. Radiographic adenoid evaluation: proposal of an objective parameter. *Radiol Bras.* 2014;47:79–83.
- Santos D, Monsignore LM, Nakiri LM, et al. Imaging diagnosis of dural and direct cavernous carotid fistulae. *Radiol Bras.* 2014;47:251–5.
- Pinto DCG, Vidigal TA, Castro B, et al. Doença de Rosai-Dorfman como diagnóstico diferencial de linfadenopatia cervical. *Rev Bras Otorrinolaringol.* 2008;74:632–5.
- Oliveira CD, Gonçalves ACP, Moura FC et al. Acometimento orbitário na doença de Rosai-Dorfman. *Rev Bras Oftalmol.* 2011;70:46–50.
- Pradhananga RB, Dangol K, Shrestha A, et al. Sinus histiocytosis with massive lymphadenopathy (Rosai-Dorfman disease): a case report and literature review. *Int Arch Otorhinolaryngol.* 2014;18:406–8.
- Akyigit A, Akyol H, Sakallioğlu O, et al. Rosai-Dorfman disease originating from nasal septal mucosa. *Case Reports in Otolaryngology.* 2015; 2015:232898.
- La Barge DV 3rd, Salzman KL, Harnsberger HR, et al. Sinus histiocytosis with massive lymphadenopathy (Rosai-Dorfman disease): imaging manifestations in the head and neck. *AJR Am J Roentgenol.* 2008;191: W299–306.
- Maia RC, Meis E, Romano S, et al. Rosai-Dorfman disease: a report of eight cases in a tertiary care center and review of the literature. *Braz J Med Biol Res.* 2015;48:6–12.
- Sah RP, Wilson ME, Seningen J, et al. Relapsing fevers and lymphadenopathy in a young woman. *BMJ Case Rep.* 2013;2013. pii: bcr2013200237.
- Ramkumar A. Kikuchi-Fujimoto disease as a differential diagnosis for cervical lymphadenopathy in India: a case report and review of literature. *Indian J Otolaryngol Head Neck Surg.* 2011;63(Suppl 1):110–2.

**Bruno Niemeyer de Freitas Ribeiro<sup>1</sup>, Edson Marchiori<sup>2</sup>**

1. Instituto Estadual do Cérebro Paulo Niemeyer, Rio de Janeiro, RJ, Brazil. 2. Universidade Federal do Rio de Janeiro (UFRJ), Rio de Janeiro, RJ, Brazil. Mailing address: Dr. Bruno Niemeyer de Freitas Ribeiro. Instituto Estadual do Cérebro Paulo Niemeyer – Serviço de Radiologia. Rua do Rezende, 156, Centro. Rio de Janeiro, RJ, Brazil, 20231-092. E-mail: bruno.niemeyer@hotmail.com.

<http://dx.doi.org/10.1590/0100-3984.2015.0167>