

Article

Received 10 May 2010
Accepted 8 Nov 2010
Available online 9 Sep 2011

Keywords:

anti-oxidative activity
electron spin resonance
gastric ulcer
healing
Ipomoea imperati
medicinal plants

ISSN 0102-695X
<http://dx.doi.org/10.1590/S0102-695X2011005000162>

Anti-oxidative and anti-ulcerogenic activity of *Ipomoea imperati*

Maria Regina M. Miyahara,¹ Paulo M. Imamura,^{*2} José C. De Freitas,³ Sérgio J. Leonor,^{4,5} Oswaldo Baffa,⁵ Angela Kinoshita,¹ Ana Claudia B. De Paula-Zurron¹

¹Pró-reitoria de Pesquisa e Pós-graduação, Universidade do Sagrado Coração, Brazil,

²Instituto de Química, Departamento de Produtos Naturais, Universidade Estadual de Campinas, Brazil,

³Departamento de Fisiologia, Instituto de Biociências, Universidade de São Paulo, Brazil,

⁴Universidade Federal do Tocantins Campus de Arraias, Brazil,

⁵Departamento de Física e Matemática, Universidade de São Paulo, Brazil.

Abstract: *Ipomoea imperati* (Vahl) Griseb., Convolvulaceae, is used in traditional medicine for the treatment of inflammation, swelling and wounds, as well as to treat pains and stomach problems. This work evaluates the anti-oxidative activity by ESR (Electron Spin Resonance spectroscopy) and the preventive and curative actions of *I. imperati* in gastric ulcer animal model. *Ipomoea imperati* (200 mg/kg, *p.o.*) prevented the formation of gastric lesions in 78% ($p<0.05$) when compared with the negative control tween 80. Lanzoprazole, prevented in 85% the gastric lesions formation induced by ethanol ($p<0.05$). Therefore, the oral administration of *I. imperati* one hour before the ulcerogenic agent prevented the ulcer formation, conserving the citoprotection characteristics of the gastric mucosa and assuring the integrity of gastric glands and gastric fosses. The healing activity of *I. imperati* (200 mg/kg, *p.o.*) evaluated in chronic ulcer experiments induced by the acetic acid, was 72% ($p<0.05$). The positive control, ranitidine, healed 78% of the gastric lesions ($p<0.05$). The histological analysis confirmed the recovery of the mucosal layer and the muscle mucosal layer harmed by the acetic acid. Experiments *in vitro* with DPPH (2,2-diphenyl-1-picrylhydrazyl) of anti-oxidative activity demonstrated that *I. imperati* presents an IC₅₀ of 0.73 ± 0.01 mg/mL.

Introduction

Many species of *Ipomoea* are still used in folk medicine in different parts of the world (Austin, 1975). *Ipomoea imperati* (Vahl) Griseb., Convolvulaceae, is used in traditional medicine for the treatment of inflammation, swelling and wounds, as well as to treat pains after childbirth and for stomach problems (Fosberg & Sachet, 1977). Pharmacological studies on extracts of many species of *Ipomoea* have reported anti-inflammatory, antimicrobial, analgesic, spasmogenic, anti-spasmodic, hypotensive, psychotomimetic and anticancer effects (MacLeod et al., 1997). Chemical investigations have shown that indole alkaloids and resin glycosides are the most common biologically active constituents in the Convolvulaceae (Noda et al., 1994; Noda et al., 1998). The same authors isolated twelve stoloniferins I (1)-XII (12) ether-soluble resin glycosides from *Ipomoea stolonifera*, related that all resin glycosides previously isolated, are monomers of

a jalapinic acid tetra- or penta-glycoside, in which the sugar moiety is partially acylated by organic acids and also combined with the carboxy group of the aglycone to form a macrocyclic ester structure.

In previous studies, *I. imperati* inhibited the topical and systemic inflammation in a concentration-dependent manner. *I. imperati* had a significant inhibitory activity against phospholipase A2 enzyme from bee venom (Paula et al., 2003). The same authors also demonstrated that in chronic inflammation experiments (cotton pellet granuloma test), no gastric mucosal lesions were observed after 6 days of treatment by oral route in rats. These results indicated a probable action mechanism in ciclooxigenase II (COX-2) enzyme.

Paula-Zurron et al. (2010) recently related that *I. imperati* showed analgesic and antiedematogenic properties. Additionally, the analgesic effect can be related to the opioid system, showing central analgesic property.

According Ene-OjoAtawodi & Onalapo

(2010) other specie of *Ipomoea*, *I. asarifolia* presented antioxidant activity. *I. asarifolia* individually or in combination with other herbs is used for the treatment of gastrointestinal disorders and/or diabetes.

Oxygen-derived free radicals have been postulated to play an important role in the pathogenesis of acute gastric mucosal injury induced by ischemia-reperfusion, stress, ethanol and anti-inflammatory drugs in rats. Furthermore, it has been suggested that free radicals generated by neutrophils may be important factors in delaying the healing of acetic acid-induced chronic gastric ulcers in these animals (Hamaishi et al., 2006). It is well known that medicinal plants act as free radical scavengers, and as antilipoperoxidants and are helpful in protecting collagen from degradation caused by superoxide anion radicals (Chen & Ho, 1997). In the present study we have examined the anti-oxidative and anti-ulcerogenic activity of lipidic fraction of *Ipomoea imperati* in animal model. Because of anti-inflammatory activity, without gastric irritation and of mucosa protection, *I. imperati* may represent an important clinical alternative both in inflammation and in antiulcerogenic therapeutics.

Material and Methods

Chemicals and biochemical

Tween, acetic acid, ethanol solution (Sigma Chemical São Paulo, Brazil), lansoprazole (Medley, Campinas, Brazil), ranitidine (GlaxoSmithKline, Rio de Janeiro, Brazil), xylazine hydrochloride, ketamine (Pfizer, São Paulo, Brazil). DPPH (2,2-diphenyl-1-picryl-hydrazyl) was purchased from Sigma-Aldrich Co. (St. Louis, MO, USA) and have purity of 95%. All other reagents used for experiments were of analytical grade.

Plant

The leaves of *Ipomoea imperati* (Vahl) Griseb., Convolvulaceae, were collected by one of the authors (A.C.B. Paula Zurron) along the seashore of Boraceia, São Paulo State, Brazil, in January and February of 2006 and 2007. The specimens were identified by Rosângela Simão Bianchini and deposited in the Botanical Institute of São Paulo under voucher number SP 351848.

Preparation of the aqueous and lipidic fractions of *I. imperati*

The air-dried powdered plant material (800 g) was extracted at room temperature with ethanol during seven days (repeated three times). After filtration, ethanol was removed under reduced pressure, producing 260 g (7.8%) of dry extract. The ethanolic extract of

Ipomoea imperati (EtOH-Ipi, 21 g) was partitioned with water:dichloromethane (1:1, v/v, 26 g) three times, and provided both lipidic (LpF, 7.78 g) and aqueous fractions (AqF, 11.42 g). The pharmacological analysis was performed using the lipidic fraction.

Animals

All experiments were performed on male Wistar rats (200-250 g) from the Central Animal House of Universidade do Sagrado Coração (USC). The animals were fed a certified Nuvilab CR-a® (Nuvital) diet and had free access to tap water. Mice were kept in the animal house under a standard 12 h light/12 h dark cycle, 50% humidity and temperature of 24±1 °C. Experimental protocols were approved by the Ethics Committee of USC and were conducted according to recommendations of the Canadian Council on Animal Care (Olfert et al., 1993).

All experiments were performed in the morning, according to current guidelines for laboratory animal care and ethical guidelines for the investigation of experimental inflammation in conscious animals (Szelenyi & Thiemer, 1978).

Ethanol induced-ulcer

Wistar rats (200-250 g) were subjected to an Ethanol-induced ulcer assay (Morimoto et al., 1991). Rats were fasted for 24 h (free access to water) before the experiment. The animals then randomly received oral Tween 80® (10 mL/kg, n=7), lansoprazole Prazol® (30 mg/kg, n=7) or *Ipomoea imperati* (200 mg/kg, n=7). One hour after treatment with the Tween, lansoprazole and *I. imperati*, 1 mL of ethanol solution was orally administered to the rats. Thirty minutes later, the animals were killed by cervical dislocation and their stomachs were removed to determine ulcer index (Szelenyi & Thiemer, 1978).

Acetic acid-induced gastric ulcers

Wistar rats (200-250 g) were randomly allocated into one of three treatment groups, in which ulceration was induced by acetic acid (Takagi et al., 1969). Rats were then treated with *I. imperati* (200 mg/kg, n=7), ranitidine (Antak®) (100 mg/kg, n=7) or Tween 80, as a vehicle (10 mL/kg, n=7). Rats were anesthetized with xylazine hydrochloride (50 mg/kg) and ketamine (180 mg/kg) for the application of 50 µL of 30 mL/L acetic acid solution into the subserosal stomach layer of each animal. Two days after surgery, the respective treatment drugs were orally administered once daily for fourteen consecutive days. The animals were sacrificed by cervical dislocation on the day after stopping drug administration. The ulcer area (mm²) and

curative ratio (%) were measured (Szelenyi & Thiemer, 1978).

Histological study

For morphological ulcer analysis, rat stomachs were fixed in Bouin for 24 h, were dehydrated through ascending concentrations of ethyl alcohol, cleared with xylene, embedded in Histosec (Merck-11609), and prepared for microtomy. The 8 μ m-sections were then deparaffinized and rehydrated through descending concentrations of ethyl alcohol. These samples were stained with hematoxylin-eosin for morphological lesion analysis, using hematoxylin for 15 min. The samples were washed in running water for 10 min, with sections changing color from red to blue. Sections were stained with eosin for 10 min and washed in water, dehydrated, placed in 95% alcohol, cleared and mounted in resin (Milani & Calabro, 2001). Photomicrographs were obtained with microscope Nikon H550L.

Free radical scavenging tests

A Varian E-4 X-band spectrometer computer interfaced allowing signal averaging and fast measurements, equipped with a rectangular cavity (TE-102, model E-231) was used for the ESR measurements.

The antioxidant activity of the *I. imperati* against the free radical present in DPPH was studied using ethanolic solutions of the lipid fraction at several concentrations. Aliquots of DPPH solution (1 mM, 40 μ L) and *I. imperati* solution (40 μ L) were mixed, stirred for 10 s and then transferred to a capillary tube. The capillary tube was sealed and placed inside a standard ESR quartz tube (inner diameter 3.00 mm), which was placed in the resonant cavity (Yokozawa et al., 1998). This procedure took three minutes and it was carried out at room temperature. For the reference measurement, the extract solution was replaced by ethanol (40 μ L). Data were reported as the average of three measurements.

Statistical analysis

Anti-ulcerogenic results were expressed as mean \pm S.E. One-way variance analysis was followed by Dunnett's, Scheffe's and Tukey's tests. These tests were run in the Statistical 5.1 software (Stat Soft, Inc). The level of significance was set at $p < 0.05$. The experimental data points of ESR signal intensity were fitted using software Microcal Origin 7.5 (Northampton, USA) for IC50 calculations and were represented by mean \pm SD.

Results

Ethanol ulceration

The effect of *I. imperati* (200 mg/kg) on gastric ulcers induced by ethanol is shown in Figure 1. In this acute experiment, animals undergoing lansoprazole (30 mg/kg) and *I. imperati* (200 mg/kg) treatment showed smaller lesion areas: 4.8 ± 0.97 mm and 7.0 ± 1.2 , respectively ($p < 0.05$) than the negative control tween 80 (32.3 ± 1.4 mm). Thus, lansoprazole and *I. imperati* treatment, reduced the gastric lesion area by 85 and 78%, respectively.

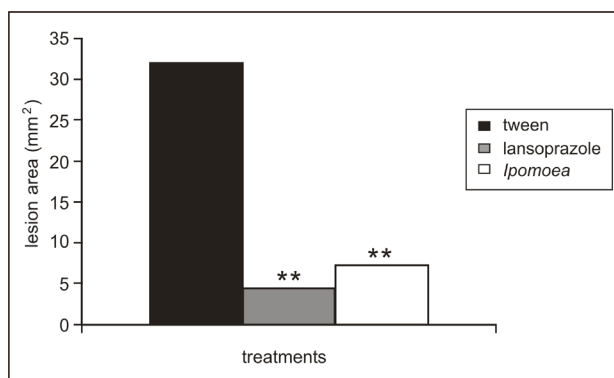


Figure 1. Preventive effect of *Ipomoea imperati* (200 mg/kg) and the positive control lansoprazole in ethanol acute gastric ulcer model. Each value is the mean \pm S.E.M for seven animals. ANOVA $F_{(2, 18)} = 4.60$ for ILU (mm²). Tukey's test: $**p < 0.001$.

Morphological analyses also showed severe lesion of the oxyntic mucosa in negative control group (pre-treated with tween) and subjected to ethanol ulceration, with destruction of the surface epithelium, lack of continuous glandular epithelium and own lamina formed by connective tissue (Figure 2A). *I. imperati* (200 mg/kg, *p.o.*) significantly prevented the lesions formation in the gastric mucosa, showing intact gastric glands and mucosa, with the continuous coating epithelium (Figure 2B).

Acetic acid-induced gastric ulcers

The healing effect of *I. imperati* was demonstrated when the healing of chronic gastric ulcer induced by acetic acid in rats was accelerated. Postoperative treatment with ranitidine (100 mg/kg) and *I. imperati* (200 mg/kg) for fourteen consecutive days accelerated the ulcer healing. On day 14 after surgery, the percentage of rats with cicatrized ulcers in both experimental groups was significantly higher than in the negative control group (Figure 3). In chronic acetic acid-induced ulceration, the lesion area was smaller in animals submitted to *I. imperati* (9.2 ± 0.98

mm²) and ranitidine (7.0±0.92 mm²) treatment than in the tween 80 treatment group (32.3±1.2 mm²). In addition, ranitidine and *I. imperati* significantly healed the chronic gastric ulcer reducing its area in 78 % and 72% (respectively) when compared with the negative control tween 80 ($p < 0.05$).




Figure 2. Photomicrographs of ulcer treatments induced by ethanol solution negative control group (tween), with destruction of the surface epithelium, lack of continuous glandular epithelium and own lamina formed by connective tissue (A). Pre-treatment with *Ipomoea imperati* (200 mg/kg) showing intact muscularis mucosal layer (MML), gastric glands and mucosa glands in the mucosal layer (ML), with the continuous coating epithelium (SE) (B). Magnifications bars: 400 µm to figures 2A e 2B. Haematoxiline & Eosine.

The figure 4A showed animals submitted to acetic acid gastric ulcer and treated with tween 80 by 14 days. In this figure there are an extensive gastric lesion showing that the surface epithelium, mucosal layer and muscularis mucosal layer are destroyed.

The surface epithelium in animals treated with *I. imperati* showed an enhance cell proliferation in the glandular regeneration zone (4C and 4D). There was an early regeneration with formation of inflammatory

infiltrate and angiogenesis (initial healing and mucosal restoration) in animals treated with *I. imperati* (Figure 4D). In the figure 4B, is possible to note capillary, disorganized conjunctive tissue, inflammatory cells, as well as granulation tissue starting the repair. Nevertheless, there was the presence the necrotic tissue, reveal a severe lesion caused by acetic acid. The fibroblast of the conjunctive tissue is secreting collagen.

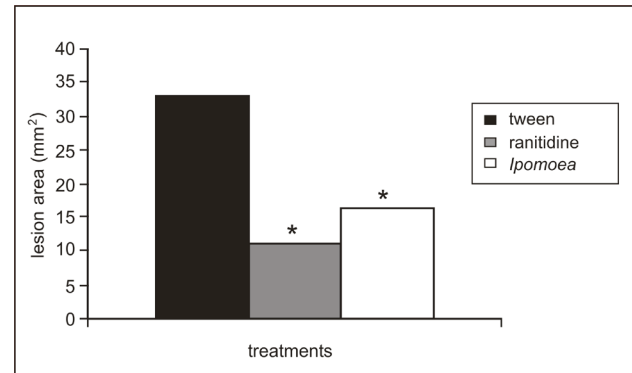


Figure 3. Lesion area due to acetic acid administration in gastric mucous of rats. The animals were treated by fourteen days with tween (negative control), ranitidine (positive control) and *Ipomoea imperati* (200 mg/kg). Each value is the mean±SEM for seven animals. ANOVA $F_{(2, 18)} = 2.84$ for ILU (mm²). Dunnett's test $*p < 0.05$.

The ESR signal intensity of the central line of DPPH was measured and plotted as function of plant extract concentration (Figure 5). Each point represents the average and standard deviation of 3 spectra. The IC₅₀ was determined by graphical analysis, fitting the experimental data with an exponential function. A value of 0.73±0.01 mg/ml was founded.

Discussion

The study shows that *Ipomoea imperati* possesses antiulcerogenic activity in different experimental models of gastric ulcer. The mechanism of this inhibition is not completely understood. In the gastric ulcers induced by ethanol the lesion areas of rats undergoing Tween 80 treatment were bigger than animals undergoing lansoprazole and *I. imperati* treatments ($p < 0.05$). The extent of ethanol-induced gastric mucosal damage in rats correlates with the number of degranulating mast cells since these cells are a source of several neuropeptides and inflammatory mediators, including histamine and leukotrienes (Cutz et al., 1978). The formation of gastric mucosal lesions by necrotic agents such as ethanol involves several gastric mechanisms which reduce the gastric blood flow, thereby contributing to the development of hemorrhage and necrosis and to the solubilization

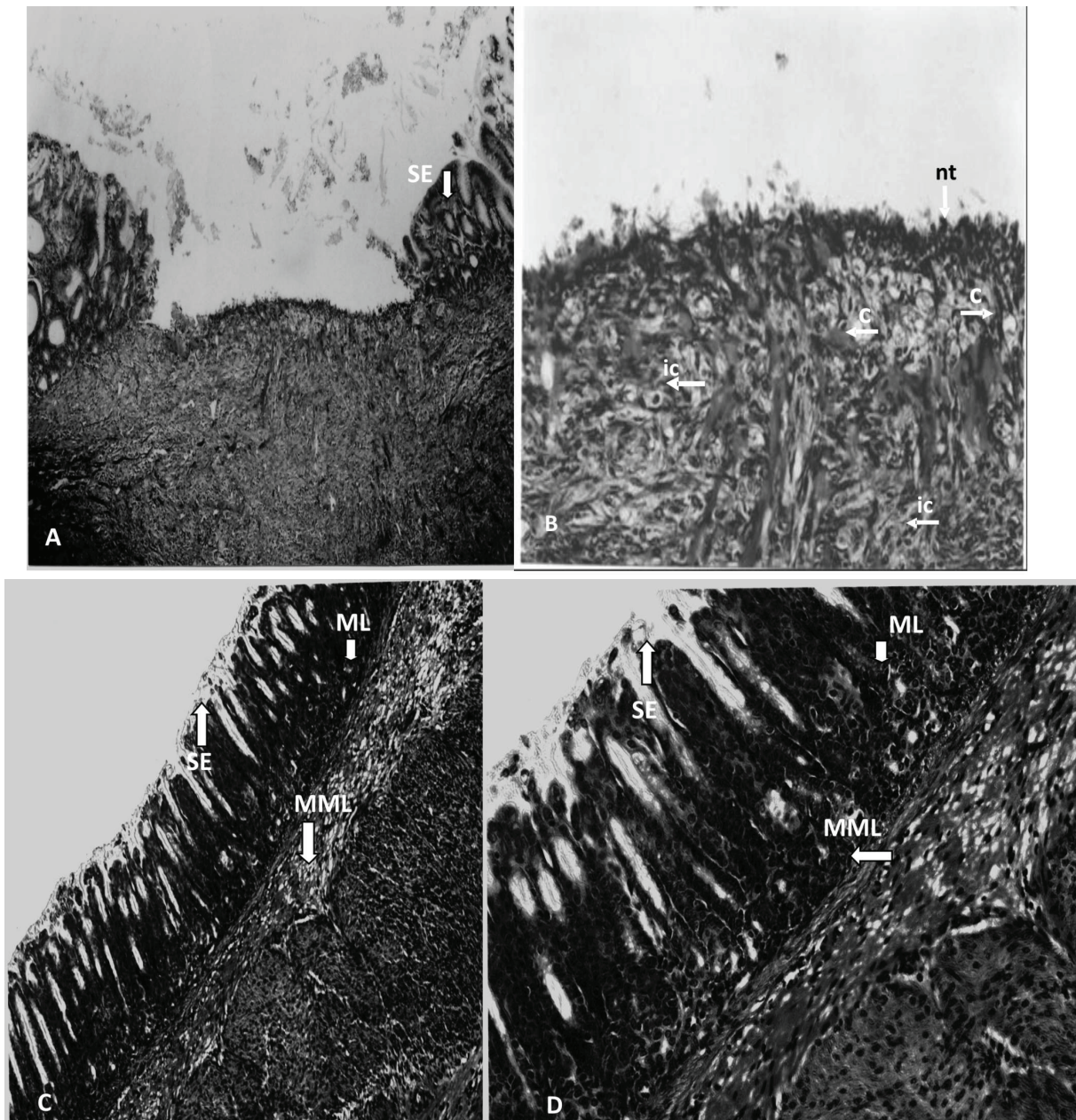


Figure 4. Photomicrographs of the treatments of chronic ulcer induced by acetic acid solution (A, B, C, D). In figure 4A treated with tween, there are an extensive gastric lesion showing that the surface epithelium (SE), mucosal layer (ML) and muscularis mucosal layer (MML) are destroyed. In figure 4B, an early regeneration with formation of inflammatory infiltrate and angiogenesis. Are possible to note capillary (c) disorganized conjunctive tissue (ct), inflammatory cells (ic), as well as granulation tissue starting the repair. The presence the necrotic tissue (nt), reveal a severe lesion caused by acetic acid. The depressed gastric mucosa is regenerated gastric surface epithelium, showing that *I. imperati* enhanced cell proliferation in the glandular regeneration zone, angiogenesis and inflammatory infiltration recovering the surface epithelium (SE), mucosal layer (ML) and muscularis mucosal layer (MML) in C and D. Magnifications bars: 200 μ m to Figure 4B, D and 400 μ m to figure 4A, C Haematoxiline & Eosine.

of mucus constituents in the stomach (Guth et al., 1984). Besides the damaging effect of acid and pepsin, the role of reactive oxygen species (ROS) in the pathophysiology of gastrointestinal injury has been focused (Das & Banerjee, 1993).

Oral administration of ethanol solution in rats clearly produced the expected characteristic zonal necrotizing mucosal lesions, decrease on gastric blood flow, generation of reactive oxygen species and an increase in inflammatory mediators, expressed by an

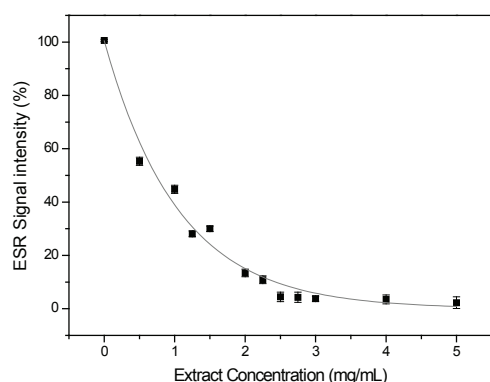


Figure 5. ESR signal intensity of central line of DPPH as function of *Ipomoea imperati* concentrations. IC₅₀ 0.73±0.01 mg/mL.

increase on IL- β and TNF α levels (Kwiecien et al., 2002). This damage may be due to a direct action of the gastric epithelium causing lipid peroxidation. Ethanol treatment induces intracellular oxidative stress and produces mitochondrial permeability transition and mitochondrial depolarization, which precede cell death in gastric mucosal cells (Hirokawa et al., 1998).

Based on this information evaluated the anti-oxidative activity of *I. imperati* by ESR, where in experiments *in vitro* with DPPH was demonstrated that *I. imperati* presents a significative anti-oxidative activity (Figure 6). These results suggest that the protective action of *I. imperati* against the gastric injury may be due in part to the scavenging of free radicals produced in the injured mucosa. Ethanol-induced gastric mucosal injury has also been indicated to be due to impairments in defensive factors such as mucus and mucosal microcirculation (Trier et al., 1987) in addition to free radicals as mentioned above.

It was attributed that the gastroprotective action of plants to an increased production of nitric oxide (Freitas et al., 2004). The controlled production of nitric oxide by constitutive isoforms of nitric oxide synthase in stomach microcirculation has been implicated in both protective and beneficial events during gastric disorders (Wallace & Miller, 2000; Martins et al., 2001).

Ipomoea imperati as well as the similar specie *Ipomoea pes-caprae*, has anti-inflammatory and anti-oxidative activity. These activities detected in *I. pes-caprae* are due four active compounds: 2-hidroxy-4,4,7-trimethyl-1(4H)-naphthalenone, mullein, eugenol and 4-vinylguaiaicol. Eugenol is a well-known inhibitor of prostaglandin synthesis and also possesses anti-inflammatory activity. Eugenol and guaiacol are also reported to inhibit leukocyte chemotaxis and prevent the production of oxygen free-radicals by leukocytes (Pongprayoon et al., 1991a). Others chemical studies related that *I. pes-caprae* contains phenolic and

terpenoid substances that must to assure the anti-oxidative activity (Pongprayoon et al., 1991b). *I. cairica* in its turn, showed that di-*O*-caffeoylquinic acids also present antioxidative effects (Ferreira et al., 2006).

Wound healing is a highly ordered and well coordinated process that involves inflammation, cell proliferation, matrix deposition, tissue remodeling, collagenation and epithelialization (Harish et al., 2008). So *Ipomoea imperati* also showed healing activity in acetic acid gastric ulcer model. In Figure 3, postoperative treatment with ranitidine (100 mg/kg) and *I. imperati* (200 mg/kg) for fourteen consecutive days accelerated the ulcer healing in 78 and 72% (respectively) when compared with the negative control tween 80 ($p < 0.05$). Chronic gastric ulcer is a deep necrotic lesion that involves the entire mucosal depth and penetrates the muscularis mucosa. Ulcer healing is a dynamic process of filling mucosal defects with proliferating and migrating epithelial cells as well as connective tissue, resulting in reconstruction of the mucosal architecture (Sasaki et al., 1998).

Several works focused the antiulcerogenic process related to the healing process and the participation of the protein of epidermal growth factor. Growth factors and their receptors play important roles in cell proliferation and migration, repair of tissue injury and ulcer healing (Konturek et al., 2001).

The EGF act on its target cells after binding to specific tyrosine kinase membrane receptors that been identified in the epithelial cells of the mucosa of the stomach and small intestine (Murphy, 1998). The expression of EGF mRNA was detected using reverse transcriptase polymerase chain reaction in gastric mucosa of the ulcerated group that received treatment with medicinal plants (Toma et al., 2004; Paula et al., 2008).

In chronic acid acetic induced ulcer, morphological analysis showed that the lesion area was bigger in rats treated with tween 80 than in those treated with *I. imperati* (Figure 4A and figure 3, $p < 0.05$). In addition, the surface epithelium in rats treated with *I. imperati* showed an early regeneration (Figure 4B, 4C, 4D). There was formation of inflammatory infiltrate and angiogenesis (initial healing and mucosal restoration) in rats treated with *I. imperati* (Figure 4C, 4D).

The depressed gastric mucosa is covered with initial regenerated gastric surface epithelium, showing that *I. imperati* enhanced cell proliferation in the glandular regeneration zone, angiogenesis and inflammatory infiltration (Figure 4B, 4C, 4D). As already well documented, angiogenesis, the formation of new blood vessels from pre-existing microvasculature, plays an important role in a variety of physiological and pathological states such as embryonic development,

wound repair, inflammatory disorders and tumor growth (You et al., 2003).

Medicinal plants are showing promise for preventive intervention in the pathogenesis of many diseases, as well as in their treatment, especially the ROS-mediated diseases such as cancer, ulcer and others (Ene-Ojoatowodi & Onalapo, 2010). The same authors related that in gastrointestinal disorders such as ulcer, the strong antioxidant potential of *Ipomoea asarifolia* suggest that it is plausible it may exert therapeutic efficacy in oxidative stress related diseases.

Nitric oxide (NO), interactively with prostanoids and sensory neuropeptides, regulates gastric mucosal integrity in rats (Whittle et al., 1990). NO participates in the gastric defenses mechanisms by regulating the gastric mucosal blood flow and gastric mucus secretion (Whittle et al., 1993). This manner in this study was possible to verify that *Ipomoea imperati* showed a preventive and healing activity in gastric ulcer models, due the controlled production of nitric oxide in stomach of rats. This fact has been implicated in both protective and beneficial events during gastric disorders.

References

- Austin DF 1975. Convolvulaceae. In: Woodson RE, Schery RW (Eds.), Flora of Panama, Part IX., *Ann Missouri Bot Gard* 62: 157-224.
- Chen H, Ho CT 1997. Antioxidant activities of caffeic acid and its related hydroxycinnamic acid compounds. *J Agric Food Chem* 45: 2374-2378.
- Cutz E, Chan W, Track NS, Goth A, Said SI 1978. Release of vasoactive intestinal polypeptide in mast cells by histamine liberators. *Nature* 275: 661-662.
- Das D, Banerjee RK 1993. Effect of stress on the antioxidant enzymes and gastric ulceration. *Mol Cell Biochem* 125: 115-125.
- Ene-Ojoatowodi S, Onalapo GS 2010. Comparative *in vitro* antioxidant potential of different parts of *Ipomoea asarifolia* Roemer & Schultes, *Guiera senegalensis*, J.F. Gmel and *Anisopus mannii* N.E. Brown. *Braz J Pharm Sci* 46: 245-250.
- Ferreira AA, Amaral FA, Duarte IDG, Oliveira PM, Alves RB, Silveira D, Azevedo AO, Raslan DS, Castro MSA 2006. Antinociceptive effect from *Ipomoea cairica* extract. *J Ethnopharmacol* 105: 148-153.
- Fosberg FR, Sacht MH 1977. Flora of Micronesia. 3. Convolvulaceae. *Srsmithsonian. Contr Bot* 36: 1-34.
- Freitas CS, Baggio CH, Da- Silva Santos JE, Rieck L, de Moraes Santos CA, Junior CC, Ming LC, Cortez DAG, Marques MC 2004 Involvement of nitric oxide in the gastroprotective effects of an aqueous extract of *Pfaffia glomerata* (Spreng) Pedersen, Amaranthaceae, in rats. *Life Sci* 74: 1167-1179.
- Guth PH, Paulsen G, Nagata H 1984. Histological and microcirculatory changes in alcohol-induced gastric lesions in the rat: Effect of prostaglandin cytoprotection. *Gastroenterology* 87: 1083-1090.
- Hamaishi K, Kojima R, Ito M 2006. Anti-ulcer effect of tea catechin in rats. *Biol Pharm Bull* 29: 2206-2213.
- Harish BG, Krishna V, Kumar HSS, Ahamed BMK, Sharath R, Swamy HMK (2008) Wound healing activity and docking of glycogen-synthase-kinase-3 β -protein with isolated triterpenoid lupeol in rats. *Phytomedicine* 15: 763-767.
- Hirokawa M, Miura S, Yoshida H, Kurose I, Shigematsu T, Hokari R, Higuchi H, Watanabe N, Yokoyama Y, Kimura H, Kato S, Ishii H 1998. Oxidative stress and mitochondrial damage precedes gastric mucosal cell death induced by ethanol administration. *Alcohol Clin Exp Res* 22: 111S-114S.
- Konturek PC, Brzozowski T, Duda A, Kwiecien S, Lober S, Dembinski A, Hagan EG, Konturek SJ 2001. Epidermal growth factor and prostaglandin E(2) accelerate mucosal recovery from stress-induced gastric lesions via inhibition of apoptosis. *J Physiol* 95: 361-367.
- Kwiecien, S, Brzozowski, T., Konturek, SJ 2002. Effects of reactive oxygen species action on gastric mucosa in various models of mucosal injury. *J Physiol Pharmacol* 53: 39-50.
- MacLeod JK, Ward A, Oelrichs, PB 1997. Structural investigation of resin glycosides from *Ipomoea lonchophylla*. *J Nat Prod* 60: 467-471.
- Martin MJ, Jimenez MD, Motilva V 2001. New issues about nitric oxide and its effects on the gastrointestinal tract. *Curr Pharm Des* 7: 881-908.
- Milani S, Calabro A 2001. Role of growth factors and their receptors in gastric ulcer healing. *Microsc Res Tech* 53: 360-371.
- Morimoto Y, Shimohara K, Oshima S, Sukamoto T 1991. Effects of the new anti-ulcer agent KB-5492 on experimental gastric mucosal lesions and gastric mucosal defensive factors, as compared to those of teprenone and cimetidine. *Jpn J Pharmacol* 57: 495-505.
- Murphy MS 1998. Growth factors and the gastrointestinal tract. *Nutri and Gastroint Dis* 14: 771-774.
- Noda N, Takahashi N, Kawasaki T, Miyahara K, Yang CR 1994. Stoloniferins I-VII, resin glycosides from *Ipomoea stolonifera*. *Phytochemistry* 36: 365-371.
- Noda N, Takahashi N, Miyahara K, Yang CR 1998. Stoloniferins VIII-XII, resin glycosides, from *Ipomoea stolonifera*. *Phytochemistry* 48: 837-841.
- Olfert ED, Cross BM, McWilliam AA 1993. Guide to the care and use of experimental animals. Canadian Council on Animal Care, vol. 1, 2nd ed; p. 1-213.
- Paula ACB, Hayashi LSS, Freitas JC 2003. Anti-inflammatory and antispasmodic activity of *Ipomoea imperati* (Vahl) Griseb (Convolvulaceae). *Braz J Med Biol Res* 36: 105-112.
- Paula ACB, Gracioso JS, Toma W, Hiruma-Lima CA, Carneiro EM, Souza Brito ARM 2008. The antiulcer effect of *Croton cajucara* Benth in normoproteic and malnourished rats. *Phytomedicine* 15: 815-825.
- Paula-Zurron, ACB, Petraglia, NMM, Aur, CR, Moura, SHP, Imamura, PM, Freitas, JC, Catanzaro-Guimarães, SA 2010. Antinociceptive activity of *Ipomoea imperati*

- (Vahl) Griseb., Convolvulacea. *Rev Bras Farmacogn* 20: 180-185.
- Pongprayoon U, Bohlin L, Soonthornsaratune P, Wasuwat S 1991a. Anti-inflammatory activity of *Ipomoea pes-caprae* (L.) R. Br. *Phytother Res* 5: 63-66.
- Pongprayoon U, Baeckstrom P, Jacobsson U, Lindstrom M, Bohlin L 1991b. Compounds inhibiting prostaglandin synthesis isolated from *Ipomoea pes-caprae*. *Planta Med* 57: 515-517.
- Sasaki E, Pai R, Halter F, Komurasaki T, Arakawa T, Kobayashi K, Kuroki T, Tarnawski AS 1998. Induction of cyclooxygenase-2 in a rat gastric epithelial cell line by epiregulin and basic fibroblast growth factor. *J Clin Gastroenterol* 27: S21-S27.
- Szelenyi I, Thiemer K 1978. Distention ulcer as a model for testing of drugs for ulcerogenic side effects. *Arch Toxicol* 41: 99-105.
- Takagi K, Okabe S, Saziki R 1969. A new method for the production of chronic gastric ulcer in rats and the effect of several drugs on its healing. *Jpn J Pharmacol* 19: 418-426.
- Trier JS, Szabo S, Allan CH 1987. Ethanol-induced damage to mucosal capillaries of rat stomach. Ultrastructural features and effects of prostaglandin F2 beta and cysteamine. *Gastroenterology* 92: 13-22.
- Toma W, Trigo JR, Bensuaski de Paula AC, Monteiro Souza Brito AR 2004. Modulation of gastrin and epidermal growth factor by pyrrolizidine alkaloids obtained from *Senecio brasiliensis* in acute and chronic induced gastric ulcers. *Can J Physiol Pharmacol* 82: 319-325.
- Wallace JL, Miller MJ 2000 Nitric oxide in mucosal defense: goes a long way. *Gastroenterology* 119: 512-520.
- Whittle, BJ, Lopez-Belmonte, J, Moncada S 1990. Regulation of gastric mucosal integrity by endogenous nitric oxide: interactions with prostanoids and sensory neuropeptides in the rat. *Br J Pharmacol* 99: 607-611.
- Whittle BJ, Lopez-Belmonte J 1993. Actions and interactions of endothelins, prostacyclin and nitric oxide in the gastric mucosa. *J Physiol Pharmacol* 44: 91-107.
- Yokozawa T, Chen CP, Dong E, Tanaka T, Nonaka GI, Nishioka I 1998. Study on the inhibitory effect of tannins and flavonoids against the 1,1-diphenyl-2-picrylhydrazyl radical. *Biochem Pharmacol* 56: 213-222.
- You YJ, Nam HN, Kim Y, Bae KH, Ahn BZ 2003. Antiangiogenic activity of lupeol from *Bombax ceiba*. *Phytother Res* 17: 341-344.

***Correspondence**

Paulo Mitsuo Imamura
Instituto de Química, Universidade Estadual de Campinas,
Caixa Postal 6154, Cidade Universitária
13084-971 Campinas-SP, Brasil
imam@iqm.unicamp.br
Tel.: +55 19 3521 3065
Fax: +55 19 3521 3023