

Pigment deposits in the retrolental space of Berger: a rare feature of pigment dispersion syndrome?

Depósitos de pigmento no espaço de Berger: uma característica rara de síndrome de dispersão pigmentar?

João Ponces Ramalhão¹ , Miguel Afonso¹ , Carolina Abreu¹ , Ana Figueiredo¹ , Rita Reis¹ , Isabel Sampaio¹ , Maria João Menéres¹ 

¹ Serviço de Oftalmologia, Centro Hospitalar Universitário de Santo António, Largo Professor Abel Salazar, Porto, Portugal.

How to cite:

Ramalhão JP, Afonso M, Abreu C, Figueiredo A, Reis R, Sampaio I, et al. Pigment deposits in the retrolental space of Berger: a rare feature of pigment dispersion syndrome? Rev Bras Oftalmol. 2024;83:e0005.

doi:

<https://doi.org/10.37039/1982.8551.20240005>

Keywords:

Glaucoma; Pigment dispersion syndrome; Pigment epithelium of eye; Wieger ligament; Ligaments; Ocular trauma

Descritores:

Glaucoma; Síndrome de dispersão pigmentar; Epitélio pigmentado ocular; Ligamento de Wieger; Ligamentos; Trauma ocular

Received on:
May 19, 2023

Accepted on:
Dec 3, 2023

Corresponding author:

João Ponces Ramalhão
Serviço de Oftalmologia, Centro Hospitalar
Universitário de Santo António
Largo Professor Abel Salazar
4099-001 – Porto, Portugal.
E-mail: jramalhao@campus.ul.pt

Institution:

Serviço de Oftalmologia, Centro Hospitalar
Universitário de Santo António, Largo
Professor Abel Salazar, Porto, Portugal.

Conflict of interest:
no conflict of interest.

Financial support:
no financial support.



Copyright ©2024

ABSTRACT

Pigment dispersion syndrome is associated with clinical features such as Krukenberg's spindles, trabecular pigmentation, Scheie's stripe and Zentmayer's ring. Another less common feature of this syndrome is retrolental pigment deposits due to anterior hyaloid detachment or a defect in the Wieger's ligament. We present two cases of pigment deposits on the posterior lens capsule. In both cases, there is bilateral dispersion of pigment throughout the anterior segment. The retrolental deposits are unilateral in the first case and bilateral in the second. Both patients report a history of ocular trauma. This is a possible important clinical sign of pigment dispersion syndrome, rarely described.

RESUMO

A síndrome de dispersão pigmentar associa-se a sinais clínicos característicos como fuso de Krukenberg, hiperpigmentação da malha trabecular, linha de Scheie e anel de Zentmeyer. Um sinal menos comum dessa síndrome é o depósito de pigmento posterior ao cristalino, que ocorre por um descolamento da hialoide anterior ou um defeito no ligamento de Wieger. Apresentamos dois casos de depósitos de pigmento posterior à cápsula posterior do cristalino. Em ambos os casos, existia dispersão bilateral de pigmento por todo o segmento anterior. No primeiro caso, os depósitos eram unilaterais e, no segundo, estavam presentes em ambos os olhos. Este pode corresponder a um sinal potencialmente importante da síndrome de dispersão pigmentar, raramente descrito.

INTRODUCTION

Pigment dispersion syndrome (PDS) consists of the circulation and deposition of melanin pigment granules.⁽¹⁾ It is more prevalent in Caucasian patients between 20 and 40 years old, and myopia itself is a risk factor for progression to pigmentary glaucoma, the most severe entity within this spectrum of the disease.⁽²⁾ Blunt ocular trauma delivers kinetic energy and an anteroposterior compression to the eye, which is primarily absorbed by the lens-iris diaphragm and the vitreous base. This can result in a detachment of the anterior hyaloid from the posterior lens capsule by rupture of the hyaloideocapsular ligament of Wieger, creating a communication between the posterior chamber and the hyaloideocapsular sinus and Berger space.⁽³⁾ When this happens, pigment may circulate and accumulate in both these potential spaces, creating distinct patterns of pigment accumulation.

This retrospective review of patient data had ethical approval by the Ethical Committee CHUdSA in accordance with local/national guidelines. Written informed consent was obtained by the patients for publication of the details of his medical case and accompanying images.

CASE REPORT

Case 1

An 80 years-old woman presents with a history of loss of vision on both eyes. Past medical history is notable for a blunt trauma to her left eye when she was 40 years old. Her best corrected visual acuity was 20/80 (-2.00 sphere -0.75x90 cylinder) in the right eye and 20/100 in the left eye (-2.50 sphere -0.50x75 cylinder). Ophthalmological examination was notable for pigment dispersion on the cornea's endothelium in both eyes and nuclear cataracts. No iris transillumination defects were noted. Intraocular pressure was 11 and 13mmHg in the right and left eyes, respectively. Gonioscopy revealed a hyperpigmented trabecular meshwork in both eyes. After pupillary dilation, Zentmeyer ring or Scheie line were visible, but the left eye revealed a vertical column of dense pigment accumulated in the posterior lens capsule (Figure 1). The right eye displayed a nuclear cataract but no pigment was visible. Fundus examination displayed a normal optic disc and retina on both eyes. Ocular coherence tomography (OCT) of the optical nerve revealed a normal retinal nerve fiber layer width.

Case 2

A 73 years-old woman presents with a history of loss of vision on both eyes. Past medical history is

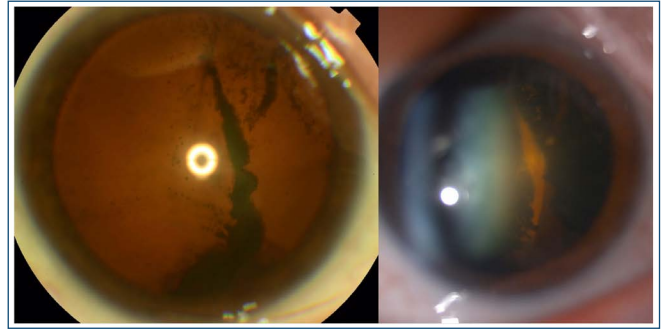


Figure 1. Patient 1, left eye.

notable for a hypertension. Best corrected visual acuity was 20/60 (+1.00 sphere -1.00x75 cylinder) in the right eye and 20/60 in the left eye (+0.25 sphere -0.75x85 cylinder). Ophthalmological examination was notable for a Krukenberg spindle in both eyes and nuclear cataracts with phakodonesis on her left eye. No iris transillumination defects were noted. Intraocular pressure was 14 and 14mmHg in both eyes. Gonioscopy revealed a hyperpigmented trabecular meshwork in both eyes. After pupillary dilation, the right eye revealed a retrolental pigment accumulation, both superior and inferior, in a pattern that resembled a Scheie line (Figure 2). The left eye had even more dense retrolental deposits dispersed throughout the whole posterior capsule in a net like pattern (Figure 3). When asked, she reported a history of ocular trauma of the left eye (she was hit with a fist 10 years earlier). Fundus examination displayed pale optic discs in both eyes with an elevated cup-to-disc ratio of 0.8. There were also multiple small macular drusens in both eyes. Ocular coherence tomography of the optical nerve revealed a globally diminished retinal nerve fiber layer thickness.

DISCUSSION

In PDS, pigmentation of the lens capsule at the level of the ligamentum hyaloideo-capsular of Wieger, is known as Scheie's line or Zentmayer's ring, depending on the pattern of deposition.⁽⁴⁾ These pathognomonic signs persist with ageing while other signs of PDS tend to vanish as the contact between the iris and zonules diminishes, following the changes in lens vault's morphology. The deposition of pigment in PDS is dependent on the routes of aqueous humor flow. Pigment shedding in PDS is thought to occur due to the rubbing of the posterior pigmented layer of the iris against the zonules of the anterior lens.⁽⁵⁾ Normally, the circulating pigment deposits in the different structures of the anterior chamber of the eye, such as the cornea's endothelium, zonules, iridocorneal angle, and trabecular meshwork. In patients

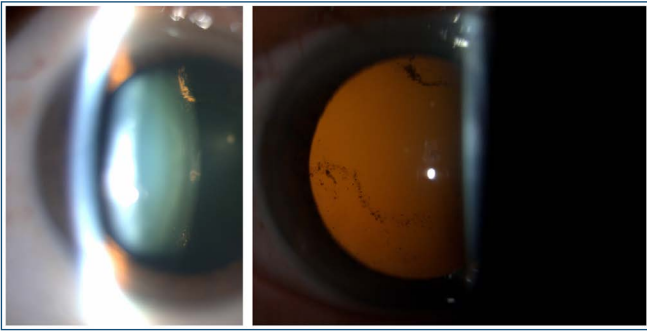


Figure 2. Patient 2, right eye.

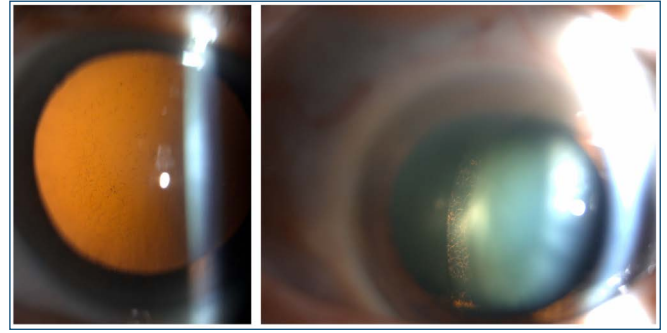


Figure 3. Patient 2, left eye.

with a history of trauma, this pattern of deposition may differ.⁽⁶⁾ In normal cases, the Weiger ligament prevents the communication between the posterior chamber and the potential space of Berger. However, primary or secondary defects of this ligament and anterior hyaloid detachment may allow aqueous humor outflow to the retrolental space and this may constitute a “dead space” in which pigment will remain “trapped”, protected from the action of phagocytic cells and aqueous currents.⁽⁷⁾

Retrolental central pigmentation in patients with PDS is much less common and these cases may include a history of ocular blunt trauma, as in our cases. The diagnosis of PDS in a patient in her 70s or 80s is difficult due to the washout of evident clinical signs throughout the years. Although the first patient presented with bilateral endothelial pigment deposits and hyperpigmented trabecular meshwork, she did not present the pathognomonic signs of PDS. Other causes for the changes in the left eye can be solely the history of previous trauma. Nevertheless, we believe that the amount of pigment deposit and the similarity with cases with retrolental deposits in patients with PDS in the literature may point to this diagnosis. The second case presents a different situation: there is evidence of a bilateral Scheie line and bilateral optic disc excavation, which may point towards the diagnosis of the remnant of a pigmentary glaucoma. The history of ocular trauma on the left side may explain the greater amount of pigment on this side.

There are few reports of central retrolental pigmentation in patients with PDS described in the literature. Roberts et al. was the first to report a case of pigment accumulation central to Weiger's ligament and the Scheie's line.⁽⁸⁾ Al-Mezaine presented the only case to our knowledge of a unilateral retrolental pigment clump in a 55-year-old patient with the history of blunt eye trauma with a football.⁽⁹⁾ Lin et al. described a similar case in a patient with PDS but without trauma history.⁽¹⁰⁾ Turgut et al. reported a case of a 36 year-old patient with annular and

central pigment deposition associated with PDS with no history of trauma. These authors suggested that anterior hyaloid membrane spontaneous detachment may lead to this clinical pattern despite absence of a trauma history.⁽¹¹⁾ Canestrano et al. described a case of bilateral pigment deposits in a patient with PDS with no history of trauma in whom the morphology of the deposits were seen to change over time.⁽¹²⁾ This feature had already been emphasized by Nagarajaiah et al., demonstrating a unilateral case in which the central aspect of the deposit cleared to accumulate more peripherally, after 14 years of follow-up.⁽¹³⁾

The deposition of pigment in the retrolental space may be an important sign of PDS. Other causes include trauma and congenital anomalies.⁽¹⁴⁾ When other signs are subtle, this feature may allow us to diagnose PDS and ensure an appropriate follow-up.

REFERENCES

1. Niyadurupola N, Broadway DC. Pigment dispersion syndrome and pigmentary glaucoma—a major review. *Clin Exp Ophthalmol.* 2008;36:868-82.
2. Farrar SM, Shields MB. Current Concepts in Pigmentary Glaucoma. *Surv Ophthalmol.* 1993;37:233-52.
3. Campanella PC, Aminlari A, DeMaio R. Traumatic cataract and Weiger's ligament. *Ophthalmic Surg Lasers.* 1997;28:422-3.
4. Lichter PR. Pigmentary glaucoma—current concepts. *Tr Am Acad Ophth Otol.* e 78:309–313.
5. Ritch R. A unification hypothesis of pigment dispersion syndrome. *Trans Am Ophthalmol Soc.* 1996;94:381-405.
6. Anand A, Harrison RJ. Annular pigment band on the posterior capsule following blunt ocular trauma: A case report. *BMC Ophthalmol.* 2005;20:5-13.
7. Lin DY, Volpicelli M, Singh K. Dense pigmentation of the posterior lens capsule associated with the pigment dispersion syndrome. *J Glaucoma.* 2003;12(6):491-3.
8. Roberts DK, Miller E, Kim LS. Pigmentation of the posterior lens capsule central to Weiger's ligament and the Scheie line: a possible indication of the pigment dispersion syndrome. *Optom Vis Sci.* 1995;72(10):756-62.
9. Al-Mezaine HS. Central posterior capsule pigmentation in a patient with pigment dispersion and previous ocular trauma: a case report. *Indian J Ophthalmol.* 2010;58(4):336-7.
10. Lin DY, Volpicelli M, Singh K. Dense pigmentation of the posterior lens capsule associated with the pigment dispersion syndrome. *J Glaucoma.* 2003;12(6):491-3.

11. Turgut B, Türkçüo lu P, Deniz N, Catak O. Annular and central heavy pigment deposition on the posterior lens capsule in the pigment dispersion syndrome: pigment deposition on the posterior lens capsule in the pigment dispersion syndrome. *Int Ophthalmol*. 2008;28(6):441-5.
12. Canestraro J, Sherman J. Curvilinear, symmetrical, and profound pigment deposition on the posterior lens capsule in a patient with bilateral pigmentary dispersion syndrome. *Eye Brain*. 2018;10:79-84.
13. Nagarajaiah S, Shun-Shin GA. Pigment deposition on the central aspect of the posterior lens capsule in pigmentary dispersion. *Digit J Ophthalmol*. 2011;17(4):69-71.
14. Buragohain S, Soibam R, Deshmukh S, Hawaibam S, Gupta K, Javeri H. Retrolental pigment clump: A developmental anomaly. *TNOA J Ophthalm Sci Res*. 2020;58(2):125-6.