

Fracture in Humeroradial Synostosis: Description of Two Clinical Cases*

Fratura em sinostose rádio-umeral: Descrição de dois casos clínicos

Ricardo Kaempf de Oliveira^{1,2} João Pedro Farina Brunelli³ Márcio Aurelio Aita⁴ Pedro José Delgado Serrano⁵

¹Hand Surgery Group, Santa Casa de Misericórdia de Porto Alegre, Porto Alegre, RS, Brazil

²Hospital Mãe de Deus de Porto Alegre, Porto Alegre, RS, Brazil

³Hospital Santa Casa de São Paulo, São Paulo, SP, Brasil

⁴Faculdade de Medicina do ABC, Santo André, SP, Brazil

⁵Hand Surgery Unit, Hospital Universitario Madrid Montepríncipe, Universidade CEU San Pablo, Boadilla del Monte, Madrid, Spain

Address for correspondence Ricardo Kaempf de Oliveira, Leopoldo Bier, 825, Conjunto 301, Porto Alegre, RS, 90620-100, Brazil (e-mail: ricardokaempf@gmail.com).

Rev Bras Ortop 2023;58(3):532–537.

Abstract

Synostosis is a generic term to indicate the union of two originally separated bones. At the elbow, humeroradial or longitudinal synostosis causes significant disability, which varies depending on hand function, elbow positioning, adjacent joints mobility and contralateral limb function. It is estimated that, to date, a little more than 150 patients have been described with this deformity, which is more common in subjects with deficient ulnar formation or affected by conditions such as Antley-Bixler and Hermann syndromes. The lack of the elbow joint, with the formation of a longer bone due to humerus-radius fusion, results in stiffness. As such, it is assumed that fractures in this topography are not uncommon. However, since synostosis is rare, this lesion was only described twice in the literature. We report two patients with a fracture of the single bone formed by a humeroradial synostosis and Bayne type-IV ulnar formation failure. Both patients were treated surgically with success. We emphasize the need for adequate treatment to not compromise the daily activities of patients who are adapted to their deformity, thus avoiding worsening the function of a previously affected limb.

Keywords

- ▶ synostosis/surgery
- ▶ radius/abnormalities
- ▶ congenital abnormalities
- ▶ syndrome
- ▶ ulna/abnormalities

Resumo

Sinostose é um termo genérico utilizado para indicar a união de dois ossos originalmente separados. No cotovelo, a sinostose rádio-umeral ou longitudinal causa importante incapacidade, que varia a depender da função da mão, da posição do

* Study developed at Hospital Santa Casa de Porto Alegre and Hospital Mãe de Deus, Porto Alegre, Brazil.

received
April 20, 2020
accepted
July 6, 2020

DOI <https://doi.org/10.1055/s-0040-1716757>.
ISSN 0102-3616.

© 2020. Sociedade Brasileira de Ortopedia e Traumatologia. All rights reserved.

This is an open access article published by Thieme under the terms of the Creative Commons Attribution-NonDerivative-NonCommercial-License, permitting copying and reproduction so long as the original work is given appropriate credit. Contents may not be used for commercial purposes, or adapted, remixed, transformed or built upon. (<https://creativecommons.org/licenses/by-nc-nd/4.0/>)

Thieme Revinter Publicações Ltda., Rua do Matoso 170, Rio de Janeiro, RJ, CEP 20270-135, Brazil

Palavras-chave

- ▶ sinostose/cirurgia
- ▶ rádio/anormalidades
- ▶ anormalidades congênicas
- ▶ síndrome
- ▶ ulna/anormalidades

cotovelo, da mobilidade das articulações adjacentes e da função do membro contralateral. Estima-se que um pouco mais de 150 pacientes foram descritos até hoje com essa deformidade, sendo mais frequente em portadores de deficiência de formação ulnar ou podendo fazer parte de síndromes como de Antley-Bixler e de Hermann. Devido à rigidez causada pela ausência da articulação do cotovelo, que resulta na formação de um osso mais longo com a fusão do úmero no rádio, presume-se que fratura nessa topografia não seja incomum. No entanto, pela raridade dessa patologia, tal lesão apresenta apenas duas descrições prévias na literatura. Relatamos os casos de dois pacientes com fratura do osso único formado pela sinostose entre o úmero e o rádio portadores de falha de formação ulnar do tipo IV de Bayne. Ambos os pacientes foram tratados de forma cirúrgica e evoluíram bem. Salientamos a necessidade do tratamento adequado para não comprometer as atividades da vida de um paciente já adaptado à deformidade, evitando piorar a função de um membro já alterado.

Introduction

Synostosis is a generic term used to indicate the union of two generally separated bones. At the elbow, proximal radioulnar synostosis (PRUS; transverse synostosis) must be differentiated from humeroradial synostosis (HRS; longitudinal synostosis). Proximal radioulnar synostosis is less rare and disabling, and it may occur alone or combined with some syndromes, such as trisomy 13 and 21.¹ Elbow flexion and extension is normal, but pronosupination is blocked. This movement can be compensated by shoulder and wrist rotation and surgical treatment is successful in selected patients.¹

Humeroradial synostosis is rarer, and it occurs in patients with postaxial longitudinal formation failure (PALFF), also called ulnar deficiency. These lesions may also be associated with conditions such as Antley-Bixler and Hermann syndromes.²⁻⁷ This anomaly prevents elbow flexion and extension, resulting in variable disability, depending on hand function, elbow positioning, adjacent joints mobility and contralateral limb function. Ulnar deficiency resulting from HRS is classified as Bayne type IV. Bilateral involvement of upper limbs is not uncommon (20%), as well as other skeletal deformities, including congenital short femur, congenital scoliosis, developmental dysplasia of the hip, phocomelia,

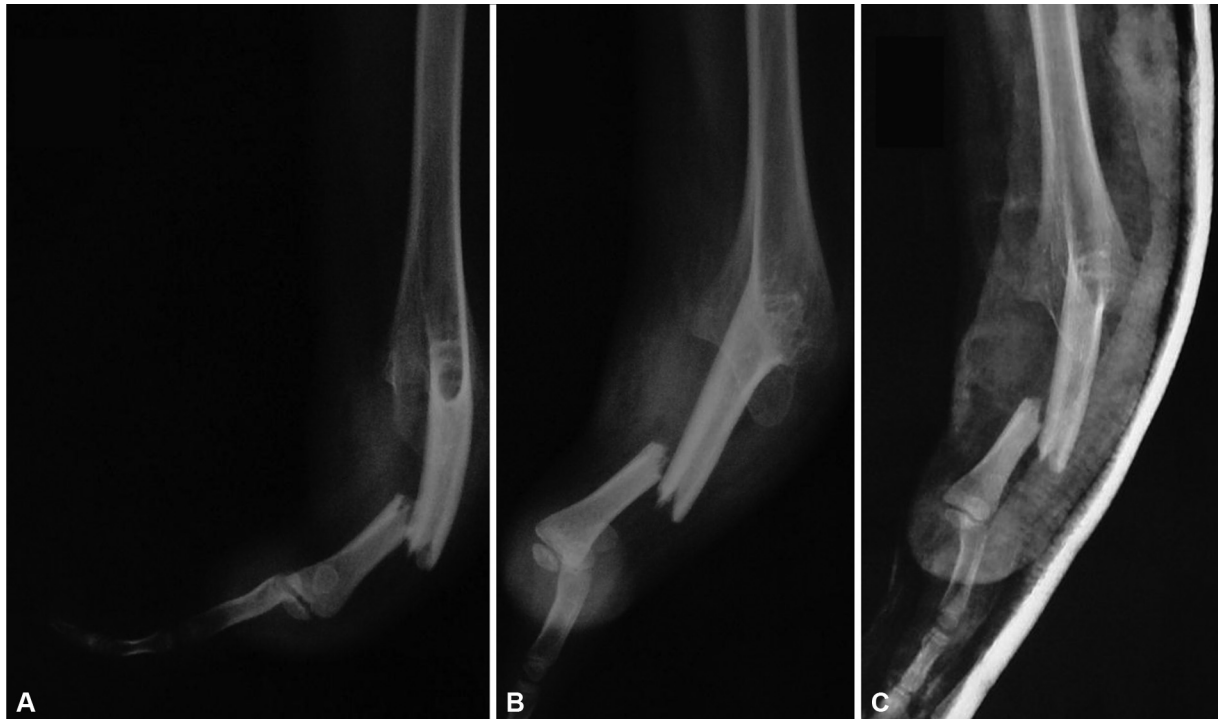


Fig. 1 An 11-year-old boy with humeroradial synostosis fell to the ground and sustained a trauma to the right upper limb. Radiographs revealed a fracture of the single bone formed by a proximal radioulnar synostosis, immediately distal to the synostosis site (A), with angulation and bone shortening even after an attempted reduction (B and C).

fibular hemimelia, and congenital clubfoot.⁸⁻¹⁰ In these patients, treatment aims to improve hand function and positioning, especially for those with the classic “hand on flank” position due to an exaggerated internal rotation of the upper extremity, resulting in hand rotation towards the gluteal region.^{1,8} Surgery for mobility recovery at a synostosis site is often unsuccessful.^{1,4}

The lack of the elbow joint, with the formation of a longer bone due to humerus-radius fusion, results in stiffness. As such, it is assumed that fractures in this topography are not uncommon. However, synostosis is rare, and this lesion was only described twice in the literature.^{2,3}

We report two patients with a fracture at the single bone formed by a humeroradial synostosis and Bayne type-IV ulnar formation failure. Both patients were treated surgically

with success. We emphasize the need for adequate treatment to not compromise the daily activities of patients who are adapted to their deformity, thus avoiding worsening of the function of a previously affected limb.

Case reports

We treated an 11-year-old boy with a severe, isolated congenital malformation in the upper limbs. The boy is the only child of a family with no history of congenital disorders. His mother said that she had no complications during pregnancy, such as illness or exposure to radiation, medications, alcohol, or drugs. She also said that there is no history of consanguineous marriages in the family. The patient had been followed up since birth at our pediatric hand surgery service. He

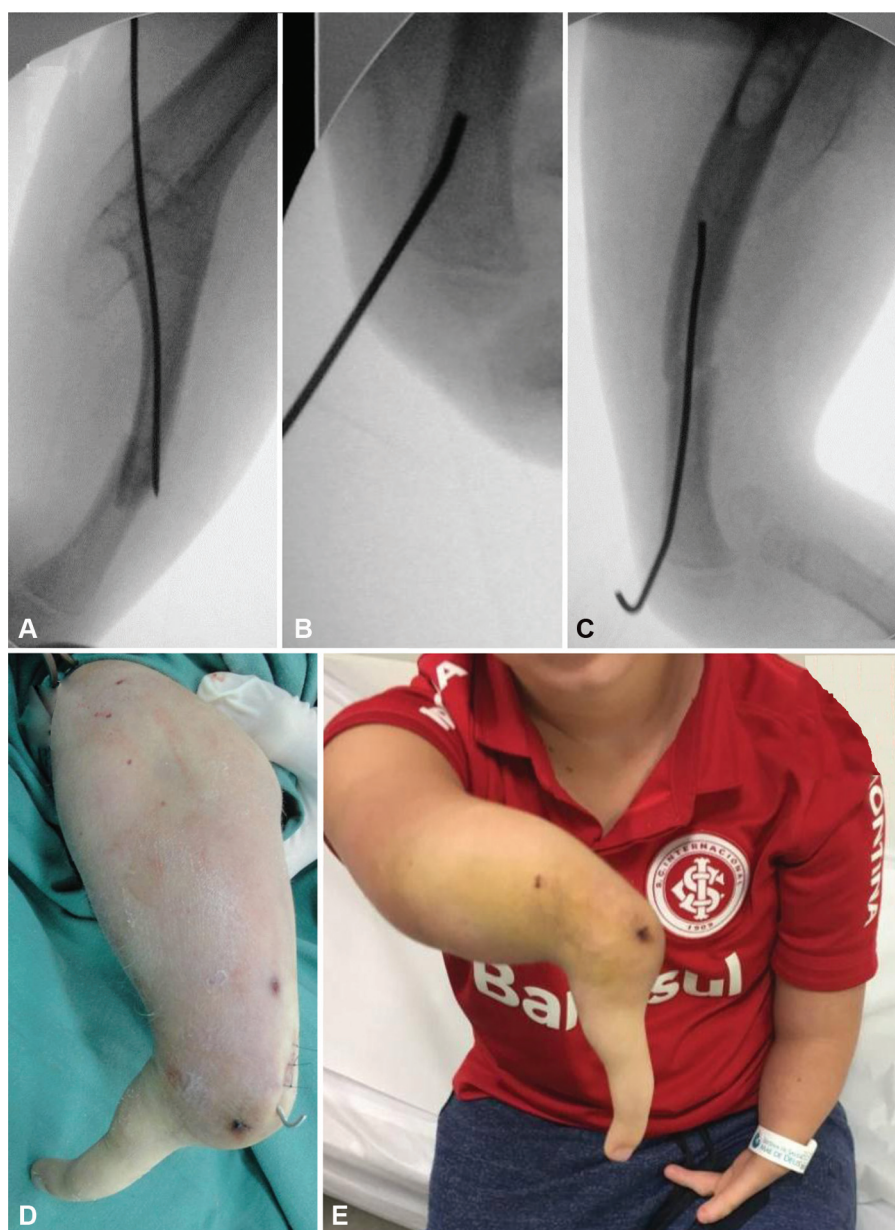


Fig. 2 Initial, unsuccessful attempt of fracture fixation with anterograde intramedullary wire through the synostosis site (A). A retrograde, percutaneous intramedullary fixation was performed (B, C, and D). The patient was followed up once a month for the first 6 months and, 3 years after the surgery, he had no pain and reported preinjury functional levels (E).

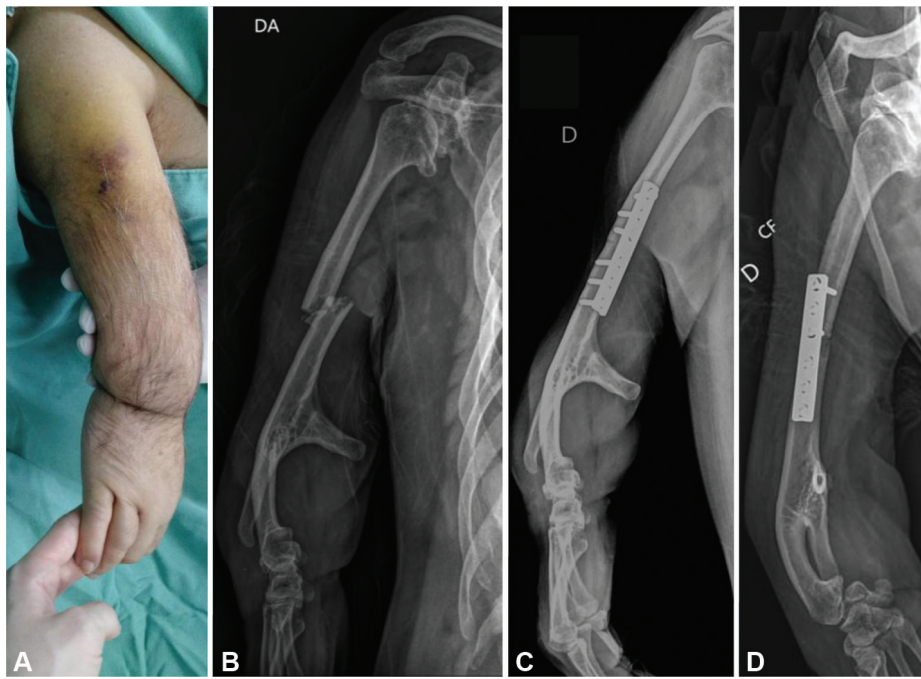


Fig. 3 A 62-year-old patient with humeroradial synostosis fell from a ladder and sustained right upper limb trauma, with local deformity and pain (A). Radiographs show a fracture proximal to synostosis and degenerative shoulder and wrist arthrosis (B). As definitive treatment, fracture was fixed using a plate and screws (C and D).

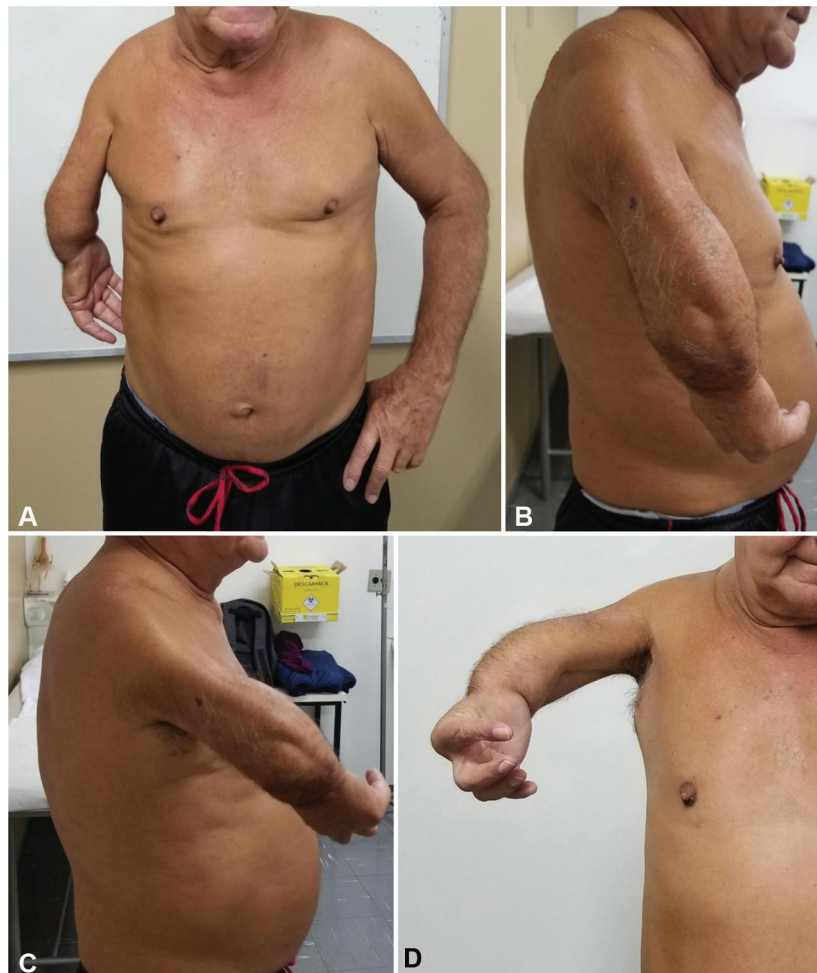

Fig. 4 Two years after the surgery, the patient had a stable limb, with no pain, and reported preinjury functional levels (A, B, C, and D).

presents bilateral PALFF, with humero-radial synostosis (Bayne type IV), only one finger in the right hand, and finger agenesis with syndactyly of the second and third fingers of the left hand (Bayne type III), previously submitted to surgical correction. We were called to the emergency room to assess the patient, who presented with pain and deformity in his right arm after falling from a bicycle. The physical exam revealed deformity and angulation in the lower third of the upper limb, with no vascular or neurological deficit, in addition to the congenital condition. Initial radiographs showed a fracture of the single bone formed by HRS, immediately distal to the synostosis site (►Fig. 1). An axillar-palmar plastered splint was placed in an attempt of fracture reduction. Surgical treatment was indicated due to the considerable fracture deviation and performed under general anesthesia. Initially, the fracture was fixed using an anterograde intramedullary wire. However, local anatomical changes prevented medullary channeling, so we decided for a percutaneous retrograde intramedullary fixation. After radioscopic confirmation of fracture reduction, the patient was immobilized with a plaster cast. In the following days, the patient did not present any procedure-related complications, such as nerve or vascular injury (►Fig. 2). Radiographic control and plaster splint change were performed at weekly visits. Twenty days after surgery, the plaster cast was removed, a sling was indicated, and light wrist and shoulder movements were encouraged. The wires were removed 8 weeks after the surgery, when radiographs revealed signs of fracture consolidation. The patient was followed up in monthly visits for the first 6 months, and then evaluated every 6 months. Physical activities and contact sports were allowed 4 months after the surgery. In a late evaluation, 3 years after the surgery, the patient did not present pain or functional deficits. Radiographs showed complete fracture healing, with no interurrences.

The second patient treated by our team was a 62-year-old man with right-sided, isolated PALFF, HRS (Bayne type IV), and thumb agenesis. He is the second child in a family with no history of congenital changes, and his mother (who is deceased) had no complications during pregnancy. He arrived at our hospital with right upper limb trauma after falling from a ladder. On examination, he presented deformity and angulation in the upper third of the upper limb, with no vascular or neurological deficits. Radiographs showed a fracture on the single bone formed by the HRS, proximal to the synostosis. There was also evidence of shoulder and wrist osteoarthritis (►Fig. 3). At the first visit, a provisional axillar-palmar plastered splint was provided for fracture alignment. Definitive treatment was plate fixation under brachial plexus block, in an approach equivalent to the standard anterolateral approach for anatomically normal humerus. The only relevant anatomical change in this procedure was humeral size, which was considerably hypoplastic. The patient had no early or late procedure-related complications. He was not immobilized after surgery, opting for a sling. Prior to the procedure, we offered the patient the possibility of elbow extension and extreme internal rotation correction, but he declined it

because he considered himself well-adapted to his condition, with a functional limb. The patient was followed-up in weekly visits, and radiographs revealed signs of fracture consolidation at 6 weeks. Next, the patient was followed-up once a month for the first 6 months, and then every 6 months. Daily life activities and sports were allowed 4 months after the surgery. In a late evaluation, 2 years after the surgery, the patient had no pain or functional deficits (►Fig. 4).

Discussion

Fractures on the single bone formed by HRS are probably not rare. The longer bone resulting from the lack of the elbow joint mechanically predisposes the limb to this injury. However, since patients with HRS are scarce, there are only two cases of abnormal limb fractures described in the literature. Both reports focus much more on the patient's underlying condition, the context of the syndrome and facial changes, with little regard for bone damage and treatment.

Elbow deformities in patients with PALFF are so characteristic that one of the first classifications¹⁰ was based on elbow synostosis and radial head dislocation. Further classification systems, including Ogden, Riordan, Swanson and Miller apud Cole and Manske, focused more on ulna and hand deformities.¹⁰ Currently, the most accepted system is the modified Bayne classification, based on Ogden,¹⁰ which divides changes into four types and includes elbow and forearm deformities.^{1,10} (►Table 1).

The incidence of HRS is unknown. In 1955, Card and Strachman¹¹ reported the 35th case in the literature. Years later, Swanson et al.⁹ and Buck-Gramcko apud McIntyre et al.⁵ published two series with 47 and 20 subjects, respectively. It is estimated that 150 cases were described in the literature.⁶ In the PALFF series, the incidence of HRS ranges from 20 to 53%, and it is worth noting that the incidence of PALFF is 4 to 10 times lower compared to its preaxial (radial) counterpart.^{1,10} No surgery is indicated for patients with good hand positioning and semiflexed elbow. Surgical attempts to obtain movement at a synostosis site are invariably unsuccessful.^{1,4} Tabrizi et al.⁴ reported complete recurrence of synostosis after an attempt of bone bar resection and fat interposition to improve hand positioning. In some patients with HRS, the upper limb is in an exaggerated

Table 1 Bayne classification, based on Ogden, dividing longitudinal postaxial formation failures of the upper limb into four types, according to severity and elbow involvement

Bayne classification for postaxial longitudinal formation failures.
Type I. Hypoplastic ulna, with proximal and distal epiphyses.
Type II. Partial absence of the ulna, with failure in the distal region (most frequent type).
Type III. Total absence of the ulna.
Type IV. Absence of the ulna with humero-radial synostosis (rarer type).

internal rotation, with the hand turned to the back, the so-called “hand on flank” posture. This is extremely disabling, and Miller and James recommended external rotary osteotomy of the humerus for these patients.^{1,8}

McIntyre et al.⁵ classified HRSs into two types. Type I is the most common HRS, with a three-times higher frequency; it is a sporadic deformity, associated with PALFF, digital hypoplasia and extended elbow. In type II, synostosis has a familial character, and it is associated with syndromic conditions; the elbow is fixed in flexion and there are no hand changes. Our two patients present type-I HRS, and we believe the extended elbow increased the risk of injury and fractures due to a greater susceptibility to trauma and the increased lever arm generated by a long, straight bone.

We believe that other congenital skeletal changes associated with HRS, such as double or bifid scapula, may be an attempt to increase limb mobility, compensating for the stiffed elbow. These patients would present a lower risk of fracture at the synostosis site. As such, we think that one of the factors resulting in the fracture sustained by our second patient, in addition to the severity of the trauma, is wrist and shoulder arthrosis, leading to greater rigidity of the entire upper limb.

Patients with HRS usually present other skeletal changes and, like most subjects with congenital deformities, have some degree of adaptation.¹ Therefore, any change in limb anatomy and positioning, especially in adults, may hinder their daily life activities. In both our patients, we preferred surgical treatment to restore the original anatomy and avoid further limb deformity and shortening, also with less immobilization time. For patients with severe internal rotation of the limb and a fracture, surgical treatment can be a good opportunity to correct a rotational deformity.

Financial Support

The present study did not receive any financial support from either public, commercial or not-for-profit sources.

Conflict of Interests

The authors have no conflict of interests to declare.

Referências

- 1 Kozin SH. Congenital differences about the elbow. *Hand Clin* 2009; 25(02):277–291
- 2 McCall AA, Kirsch CF, Ishiyama G, Ishiyama A. Otologic findings in Antley-Bixler syndrome: a clinical and radiologic case report. *Int J Pediatr Otorhinolaryngol* 2007;71(07):1139–1143
- 3 Hosalkar HS, Shah HS, Gujar PS, Shaw BA. The Antley-Bixler syndrome: two new cases. *J Postgrad Med* 2001;47(04): 252–255
- 4 Tabrizi A, Afshar A, Aidenlou A. A case of failure to correct humerus-radius synostosis and thumb hypoplasia. *J Hand Surg Eur Vol* 2018;43(02):211–213
- 5 McIntyre JD, Brooks A, Benson MK. Humeroradial synostosis and the multiple synostosis syndrome: case report. *J Pediatr Orthop B* 2003;12(03):192–196
- 6 Nema S, Vyas G, Sirsikar A, Bhoj PK. Congenital humeroradial synostosis: a case report. *Malays Orthop J* 2012;6(SupplA):41–42. Doi: 10.5704/MOJ.1211.010
- 7 Pfeiffer RA, Braun-Quentin C. Genetic nosology and counseling of humeroradial synostosis. *Genet Couns* 1994;5(03):269–274
- 8 Miller JK, Wenner SM, Kruger LM. Ulnar deficiency. *J Hand Surg Am* 1986;11(06):822–829
- 9 Swanson AB, Tada K, Yonenobu K. Ulnar ray deficiency: its various manifestations. *J Hand Surg Am* 1984;9(05):658–664
- 10 Cole RJ, Manske PR. Classification of ulnar deficiency according to the thumb and first web. *J Hand Surg Am* 1997;22(03):479–488
- 11 Card RY, Strachman J. Congenital ankylosis of the elbow. *J Pediatr* 1955;46(01):81–85