

Parasites of Psittaciformes and Accipitriformes in Paraíba state, northeastern Brazil

Parasitas de Psittaciformes e Accipitriformes no estado da Paraíba, Brasil

Cristiane Maria Fernandes de Melo¹; Jaqueline Bianque Oliveira²;
 Thais Ferreira Feitosa^{1*}; Vinícius Longo Ribeiro Vilela¹; Ana Célia Rodrigues Athayde¹;
 Antônio Flávio Medeiros Dantas¹; Paulo Guilherme Carniel Wagner³; Andrei Brum Febrônio¹

¹Programa de Pós-graduação em Medicina Veterinária, Universidade Federal de Campina Grande – UFCG, Patos, PB, Brasil

²Laboratório de Parasitologia Animal, Departamento de Biologia, Universidade Federal Rural de Pernambuco – UFRPE, Recife, PE, Brasil

³Centro de Triagem de Animais Selvagens – CETAS, Instituto Brasileiro do Meio Ambiente e dos Recursos Naturais Renováveis – IBAMA, Cabedelo, PB, Brasil

Received November 27, 2012

Accepted May 17, 2013

Abstract

In this study, we investigated the presence of gastrointestinal helminths in 97 captive birds (Psittaciformes and Accipitriformes) necropsied between June and December 2011 in the state of Paraíba, Brazil. Forty-three birds were infected. Psittaciformes were infected by nematode *Ascaridia hermaphrodita* (97.6%) and cestode *Raillietina* sp. (2.4%). *A. hermaphrodita* was found in all species of parrots and *Raillietina* sp. was found only in *Amazona aestiva*. *A. hermaphrodita* was the cause of death, by intestinal obstruction, in 14 of the 40 birds investigated. Accipitriformes were infected by nematode *Synhimantus (Synhimantus) rectus* (100%) and acanthocephalan *Centrorhynchus tumidulus* (50%). In Brazil, *Diopsittaca nobilis* and *A. aestiva* are reported for the first time as hosts of *A. hermaphrodita* and *Raillietina* sp., respectively. We concluded that Psittaciformes and Accipitriformes in captivity are affected by nematodes, cestodes and acanthocephalans and that implementation of control measures is essential.

Keywords: Acanthocephalans, accipitriformes, cestodes, nematodes, psittaciformes.

Resumo

Este estudo objetivou-se investigar a presença de parasitos gastrointestinais em aves de cativeiro da Ordem Psittaciformes e Accipitriformes no estado da Paraíba-Brasil. Foram necropsiadas 97 aves durante o período de junho a dezembro de 2011. Em 43 (44.3%) aves, foi detectada a presença de nematóides, cestóides e/ou acantocéfalos. A prevalência de parasitos gastrointestinais em Psittaciformes foi de 45.6% (41/88) e os helmintos identificados foram *Ascaridia hermaphrodita* (Ascaridoidea, Ascarididae) (40/41, 97.6%) e *Raillietina* sp. (Cyclophyllidea, Davaineidae) (1/41, 2.4%). *A. hermaphrodita* foi encontrada em todas as espécies de papagaios e *Raillietina* sp. foi encontrada apenas na *Amazona aestiva*. Em aves Accipitriformes, a prevalência foi de 22.2% (2/9) e os helmintos identificados foram *Synhimantus (Synhimantus) rectus* (Spirurida, Acuariidae) (2/2, 100%) e *Centrorhynchus tumidulus* (Acanthocephala, Centrorhynchidae) (1/2, 50%). Todos os parasitos encontrados neste estudo são relatados pela primeira vez em aves Psittaciformes e Accipitriformes no estado da Paraíba. No Brasil, *Diopsittaca nobilis* e *A. aestiva* são apresentados pela primeira vez como hospedeiros da *A. hermaphrodita* e *Raillietina* sp., respectivamente. Concluiu-se que aves Psittaciformes e Accipitriformes de cativeiro são afetadas por nematóides, cestóides e acantocéfalos, e que a implementação de medidas de controle é imprescindível.

Palavras-chave: Acantocéfalos, accipitriformes, cestóides, nematóides psittaciformes.

Parasitic infections are one of the major health problems of wild birds kept in captivity (RITCHIE et al., 1994; GÓMEZ-PUERTA et al., 2008; OLIVEIRA et al., 2011). Damage to the host and symptoms depend on the pathogenicity and intensity

of infection and general condition of the animal (immune competence) (GODOY, 2007). Microorganisms of low pathogenicity can ultimately cause severe clinical disease in birds that are immunosuppressed, stressed, or present concomitant diseases (OLIVEIRA et al., 2011; SANTOS et al., 2011).

Parrots occur from tropical areas to cold regions (GODOY, 2007). Several diseases including endoparasitoses affect these birds (GONZÁLEZ-ACUÑA et al., 2007; SANTOS et al., 2011). In

*Corresponding author: Thais Ferreira Feitosa

Programa de Pós-graduação em Medicina Veterinária, Universidade Federal de Campina Grande – UFCG, CEP 58108-110, Patos, PB, Brasil

e-mail: feitosa_tf@yahoo.com.br

Brazil, helminths of parrots are well known, especially nematodes of the genus *Ascaridia* (GODOY, 2007). Intestinal obstruction due to high parasite loads of *Ascaridia* sp. is relatively common, causing intussusception and death (GODOY, 2007; GONZÁLEZ-ACUÑA et al., 2007).

Birds of prey are at the top of food chain and are divided in two groups: diurnal (Accipitriformes, Falconiformes) and owls (Strigiformes) (SANMARTÍN et al., 2004; PEREIRA, 2007). Infections caused by endoparasites with no manifestation of clinical signs are common in these birds (PEREIRA, 2007; SANTOS et al., 2011). However, presence of parasites may become apparent in conditions of stress common in captivity, and gastrointestinal infections may be exacerbated by parasites causing diarrhea, anorexia, weight loss, and death (SANTOS et al., 2011).

Parasite identification is important for the knowledge of the most common species infecting wild birds in captivity, in addition to aid in the promotion of quick and efficient implementation of control measures (OLIVEIRA et al., 2011; SANTOS et al., 2011). In this study, we aimed to identify parasites of captive birds (Psittaciformes and Accipitriformes) in the state of Paraíba, Brazil.

The birds analyzed were from the Center for Wildlife Screening (Centro de Triagem de Animais Silvestres - CETAS) of the Brazilian Institute of Environment and Renewable Natural Resources (Instituto Brasileiro de Meio Ambiente e Recursos Naturais Renováveis - IBAMA). The CETAS is an agency responsible for receiving animals handed by the population and/or seized from animal trafficking. These animals are taken to these centers with a recovery purpose and are later sent to zoos that receive particular species or freed in nature. All animals were analyzed on the premises of CETAS located in the municipality of Cabedelo, Paraíba state.

A total of 97 birds necropsied between June and December 2011 were examined for gastrointestinal helminths. The following bird species were evaluated: 54 blue fronted Amazon (*Amazona aestiva*), 26 orange-winged Amazon (*A. amazonica*), four red-shouldered macaw (*Diopsittacus nobilis*), three Caatinga parakeet (*Aratinga cactorum*), and one scarlet macaw (*Ara macao*). Psittaciformes came from both trafficking and domestic captivity. Besides the Psittaciformes, nine Accipitriformes *Rupornis magnirostris* (syn. *Buteo magnirostris*) (Aves, Accipitriformes) from trafficking were also studied.

Some specimens were necropsied immediately after death while others were kept frozen (-10 ° C). During necropsy, helminths were collected solely from the gastrointestinal tract, processed and fixed following the methodology adapted by Hoffmann (1987) and Amato et al. (1991). Parasites were identified according to the following keys: Yamaguti (1963), Petrochenko (1971), Khalil et al. (1994), Vicente et al. (1995) and Anderson et al. (2009).

Of the 97 birds examined, 43 (44.3%) presented nematodes, cestodes and/or acanthocephalans. Prevalence of helminths in Psittaciformes was 45.6% (41/88). Parasites were found in 1/1 (100%) *Ara macao*, 24/26 (92.3%) *A. amazonica*, 1/3 (33.3%) *A. cactorum*, 14/54 (25.9%) *A. aestiva*, and 1/4 (25%) *D. nobilis*.

Helminths identified were nematode *A. hermaphrodita* (Ascaridoidea, Ascarididae) (40/41, 97.6%) (Figure 1) and cestode *Raillietina* sp. (Cyclophyllidea, Davaineidae) (1/41, 2.4%). *A. hermaphrodita* was found in the small intestine of all species studied, while *Raillietina* sp. was found only in the small intestine

of *A. aestiva*. Intensity of infection by *A. hermaphrodita* was in average 253.5 (ranging from 4 to 503). Intestinal obstruction caused by nematode *A. hermaphrodita* was the cause of death in 14 of the 40 birds parasitized.

In birds of prey, nematode *Synhimantus* (*Synhimantus*) *rectus* (Spirurida, Acuariidae) (2/9, 22.2%) (Figure 2) was found in the ventricle and proventriculus, while acanthocephalan *Centrorhynchus tumidulus* (Acanthocephala, Centrorhynchidae) (1/9, 11.1%) was collected in the small intestine. Prevalence of helminths was 33.3% (3/9). Intensity of infection was low: *S. rectus* with two and four specimens and *C. tumidulus* with two specimens per animal. In this study, we found prevalence of 45.6%, similar to what was observed (48%) by Freitas et al. (2002) for parrots in captivity from the state of Pernambuco, Brazil.

A. hermaphrodita was the most frequent parasite. Hodová et al. (2008) reported that five species of *Ascaridia* are frequent in Psittaciformes; *A. platyceri* and *A. hermaphrodita* are the most common. In Brazil, Pinto et al. (1993) reported *A. hermaphrodita* as specific of psittacines of genera *Amazona*, *Anodorhynchus*, *Ara*, *Aratinga*, *Brotogeris*, *Conurus*, *Pyrrhura*, *Pittacus* and *Pionus*; this fact corroborates studies on psittacines in Argentina, Chile and Peru (MARTÍNEZ et al., 2003; MASELLO et al., 2006; GONZÁLEZ-ACUÑA et al., 2007; GÓMEZ-PUERTA et al., 2008).

In this study, 14 birds parasitized by *A. hermaphrodita* died due to parasite infection intensity. Ritchie et al. (1994) reported that ascariasis stands out as one of the most common gastrointestinal parasitic infections in psittacines and is associated with clinical signs such as weight loss, anorexia and, in severe cases, death. González-Acuña et al. (2007) and Hodová et al. (2008) reported intestinal obstruction by *A. hermaphrodita* as a cause of death in parrots. Hodová et al. (2008) obtained 242 specimens of helminths in necropsied psittacines. González-Acuña et al. (2007) observed severe lesions, with congestion of the intestinal mucosa and increased mucus production.

The prevalence of helminths in birds of prey (22.2%) in this survey was lower than that found in Italy by Santoro et al. (2010), who, through necropsy, reported prevalence of 95% in free-living rapine birds. On the other hand, by fecal examination,

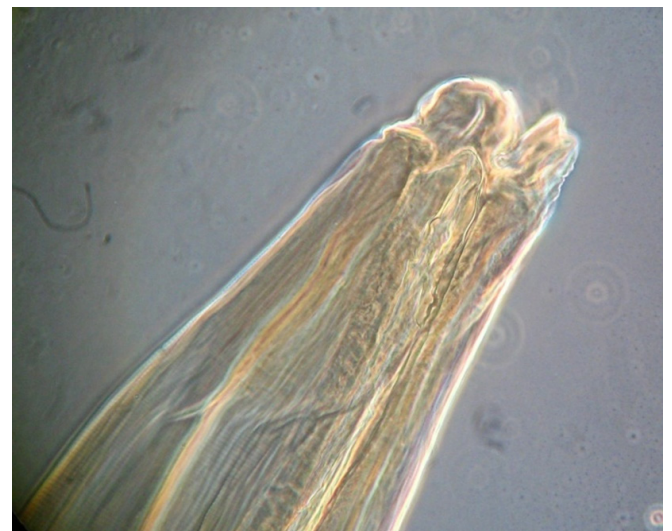

Figure 1. Anterior part of *Ascaridia hermaphrodita*.

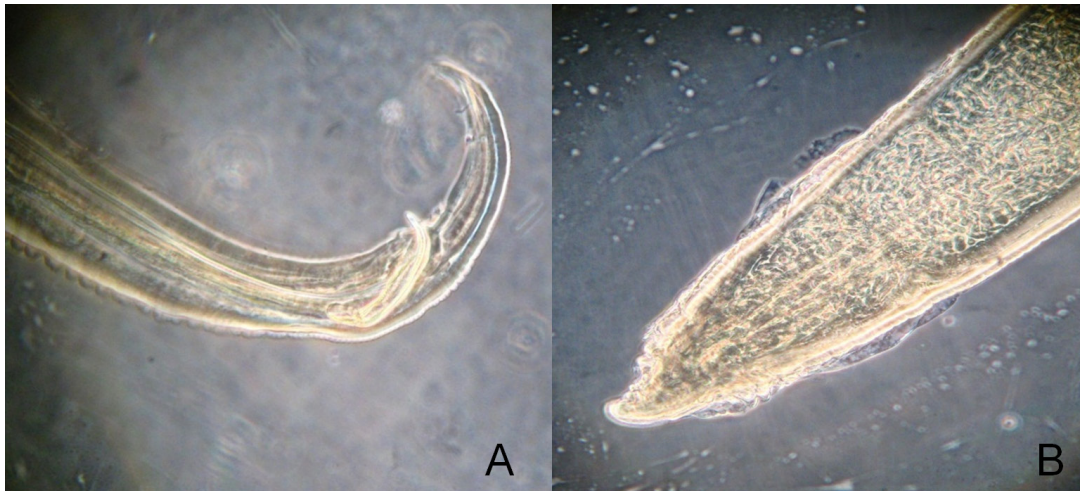


Figure 2. A) Spicule from male *Synhimantus(S) rectus*; B) Posterior part from female *Synhimantus(S) rectus*.

Santos et al. (2011) determined prevalence of 13.5% in birds of prey in captivity in Mexico.

In Europe, prevalence of 22.2% was observed for *C. tumidulus*. *Centrorhynchus* are considered common helminths in birds of prey, with prevalence ranging from 1.1% in Germany (KRONE, 2000) to 63.6% in Spain (SANMARTÍN et al., 2004) and 100% in Italy (SANTORO et al., 2010).

In the current study, the intensity of infection by *S. rectus* was low. Santoro et al. (2010) considered intestinal obstruction as a cause of death in the birds studied, which differs from this study. According to these authors, *Synhimantus* spp. and *S. laticeps* were associated with erosion and ulcers in the gastric mucosa, whereas infections with more than 100 specimens of *Centrorhynchus* spp. were associated with enteritis, diarrhea, cachexia, intussusception, and death. On the other hand, Kinsella et al. (1995) reported no injuries related to the presence of *Synhimantus* sp., *S. hamatus*, and *C. kuntz* in birds of prey in the United States, but called attention to the potential pathogenicity of *C. kuntz*, especially in young birds.

Little is known about the pathogenic effects of parasites in birds of prey (SANTORO et al., 2010). Although clinical signs of parasitism are infrequent, they may become evident under conditions of stress associated with high parasite loads (FREITAS et al., 2002; SANTORO et al., 2010; SANTOS et al., 2011). In this respect, diagnosis and treatment of parasitic diseases should be part of the routine health care of birds in captivity (SANTOS et al., 2011).

All parasites identified in this study were the first record in Psittaciformes and Accipitriformes in captivity in the state of Paraíba. In Brazil, *D. nobilis* and *A. aestiva* are presented for the first time as hosts of *A. hermaphrodita* and *Raillietina* sp., respectively. Helminth infections in wild birds kept in captivity should be prevented because, in great quantities, they can be lethal to these animals.

Acknowledgments

The authors are grateful to CNPq for the financial support. This study was approved by the System of Authorization and

Information on Biodiversity - SISBIO/Chico Mendes Institute for Biodiversity Conservation - ICMBio (No. 29661-1).

References

- Amato JFR, Böeger WA, Amato, SB. *Protocolos para laboratório: coleta e processamento de parasitos de pescado*. Seropédica: Gráfica da Universidade Federal Rural do Rio de Janeiro; 1991. 81 p.
- Anderson RC, Chabaud AG, Willmott S. *Keys to the nematode parasites of vertebrates*. Wallingford: CABI International; 2009. Archival volume.
- Freitas MFL, Oliveira JB, Cavalcanti MBD, Leite AD, Magalhães VS, Oliveira RA, et al. Parasitos gastrointestinais de aves silvestres em cautiverio en el estado de Pernambuco, Brasil. *Parasitol Latinoam* 2002; 57(1-2): 50-54.
- Godoy SN. Psittaciformes (Arara, Papagaio, Periquito). In: Cubas ZS, Silva JCR, Catão-Dias JL. *Tratado de Animais Selvagens*. Roca: São Paulo; 2007. p. 222-251.
- Gómez-Puerta LA, López-Urbina MT, González AE. Ocurrencia de *Ascaridia hermaphrodita* (Nematode: Ascaridiidae) en el loro de Cabeza Azul (*Pionus menstruus*) en Perú. *Rev Peru Biol* 2008; 15(2): 133-135.
- González-Acuña D, Fabry M, Nascimento AA, Tebaldi JH. Death of two slender-billed parakeet (King) (*Enicognathus leptorhynchus*) (Aves, Psittacidae) by *Ascaridia hermaphrodita* (Froelich, 1789, Railliet & Henry, 1914) at the National Zoo of Santiago, Chile. *Arq Bras Med Vet Zootec* 2007; 59(2): 539-540. <http://dx.doi.org/10.1590/S0102-09352007000200044>
- Hodová I, Barus V, Tukac V. Note on morphology of two nematode species *Ascaridia hermaphrodita* and *Ascaridia platyceri* (Nematoda): scanning electron microscope study. *Helminthologia* 2008; 45(3): 109-113. <http://dx.doi.org/10.2478/s11687-008-0021-4>
- Hoffmann RP. *Diagnóstico de Parasitismo Veterinário*. Sulina: Porto Alegre; 1987. p. 156.
- Khalil LF, Jones A, Bray RA. *Keys to the Cestode Parasites of Vertebrates*. Wallingford: CABI International; 1994. p. 257-293.
- Kinsella JM, Foster GW, Forrester DJ. Parasitic helminthes of six species of hawks and falcons in Florida. *J Raptor Res* 1995; 29(2): 117-122.

- Krone O. Endoparasites in free-ranging birds of prey in Germany. In: Lumeij JT, Remple JD, Redig PT, Lierz M, Cooper JE. *Raptor Biomedicine III: Including bibliography of birds of prey*. Lake Worth: Zoological Education Network; 2000. p. 101-116.
- Masello JF, Choconi RG, Sehgal RNM, Tell L, Quillfeldt P. Blood and intestinal parasites in wild Psittaciformes: a case study of burrowing parrots (*Cyanoliseus patagonus*). *Ornitol Neotrop* 2006; 17: 515-529.
- Martínez FA, Troyano JC, Ledesma S, Antonchuk LA, Fescina N. Presencia de *Ascaridia hermaphrodita* (Froelich, 1789) en *Ara chloroptera* (Aves, Psittaciformes) en Argentina. *Rev Salud Anim* 2003; 25(3): 212-214.
- Oliveira JB, Santos T, Vaughan C, Santiago H. External parasites of raptors (Falconiformes and Strigiformes): identification in an *ex situ* population from Mexico. *Rev Biol Trop* 2011; 59(3): 1257-1264. PMID:22017130.
- Pereira RJC. Falconiformes e Strigiformes (Águia, Gavião, Falcão, Abutre, Coruja). In: Cubas ZS, Silva JCR, Dias JLC. *Tratado de Animais Selvagens*. 2. ed. Roca: São Paulo; 2007. p. 252-267.
- Petrochenko VI. Acanthocephala of domestic and wild animals. In: Skrjabin KI. *Israel Program for Scientific Translations*. Jerusalem, Washington: U.S. Department of Agriculture and National Science Foundation; 1971. p. 430-435.
- Pinto RM, Vicente JJ, Noronha D. Nematode parasites of Brazilian Psittacid birds, with emphasis on the genus *Pelecitus* Railliet & Henry, 1910. *Mem Inst Oswaldo Cruz* 1993; 88(2): 279-284. <http://dx.doi.org/10.1590/S0074-02761993000200016>
- Ritchie BW, Harrison GJ, Harrison LR. Parasites. In: Greiner EC, Ritchie BW. *Avian Medicine: Principles and Application*. Wingers Publishing: Flórida; 1994. p. 1007-1009.
- Sanmartín ML, Álvarez F, Barreiro G, Leiro J. Helminth fauna of Falconiform and Strigiform birds of prey in Galicia, Northwest Spain. *Parasitol Res* 2004; 92(2): 255-263. PMID:14714181. <http://dx.doi.org/10.1007/s00436-003-1042-z>
- Santoro M, Tripepi M, Kinsella JM, Panebianco A, Mattiucci S. Helminth infestation in birds of prey (Accipitriformes and Falconiformes) in Southern Italy. *Vet J* 2010; 186(1): 119-122. PMID:19713134. <http://dx.doi.org/10.1016/j.tvjl.2009.07.001>
- Santos T, Oliveira JB, Vaughann C, Santiago H. Health of an *ex situ* population of raptors (Falconiformes and Strigiformes) in Mexico: diagnosis of internal parasites. *Rev Biol Trop* 2011; 59(3): 1265-1274. PMID:22017131.
- Vicente JJ, Rodrigues HO, Gomes DC, Pinto RM. Nematóides do Brasil, Parte IV: Nematóides de aves. *Rev Bras Zool* 1995; 12(S1): 1-273. <http://dx.doi.org/10.1590/S0101-81751995000500001>
- Yamaguti S. *Systema Helminthum*. Vol. V. *The Acanthocephala of vertebrates*. Interscience Publishers: New York; 1963.