

MYCOBACTERIAL SUBCUTANEOUS ARTERITIS

Consuelo Junqueira RODRIGUES, Fernando Peixoto Ferraz de CAMPOS, Lais Lage FURTADO-MENDONÇA, Rosa Maria Rodrigues PEREIRA, Berilo LANGER, Jayme DIAMENT, Ricardo Manoel de OLIVEIRA & Wilson COSSERMELLI

SUMMARY

The authors report three patients with subcutaneous erythematous nodules in different phases of development, inespecific systemic symptoms, positive PPD test, and normal chest X-rays. The histopathological study of the older nodules showed a granulomatous arteritis with a few acid-fast bacilli in the vascular wall. The nodules at an early phase showed an inespecific panniculitis with some acid-fast bacilli in apparently normal cutaneous vessels. These findings suggest that the mycobacterium has a vascular tropism and may cause a primary granulomatous arteritis.

KEY WORDS: Erythema induratum Bazin; Erythema nodosum; Vasculitis.

INTRODUCTION

There is a group of subcutaneous nodose lesions which involve primarily the legs, although they may affect the calves, thighs and forearms. These lesions are generally chronic, sometimes ulcerate and are associated with varying degrees of involvement of the blood vessels. Two of them, the erythema nodosum (EN) and the erythema induratum Bazin (EIB), may accompany tuberculosis. However, the tubercle bacilli are generally not found in these lesions^{4, 12, 13}.

In the present report we describe three cases with clinical manifestations of subcutaneous erythematous nodules in which mycobacterium was identified in the wall of vessels with granulomatous lesion and in apparently normal cutaneous vessels.

REPORT OF CASES

CASE 1 — A 19 year-old white female was admitted to the General Hospital of the University of São Paulo School of Medicine (HC-FMUSP) with a two month history of weight loss, arthralgia and some painful nodules in the legs which were followed by other nodules in the limbs within the next seven days. Physical examination showed subcutaneous nodules with 3-5 mm in diameter over the vascular line of the calves and wrists. One calf nodule was biopsied (nodule 1). Twenty days after admission new erythematous painful nodules appeared in the anterior surface of the legs and the upper limbs. One of the upper extremities nodule was also biopsied (nodule 2). The histopathological examina-

From the Laboratory of Investigation in Experimental Therapeutics and Laboratory of Investigation in Rheumatology, University of São Paulo, School of Medicine, São Paulo, BRASIL.

Address for correspondence: Dra. Consuelo Junqueira Rodrigues, Faculdade de Medicina da Universidade de São Paulo, Laboratório de Reumatologia, Av. Dr. Arnaldo, 455, CEP 01246 São Paulo, SP, Brasil.

tion showed granulomatous arteritis with caseous necrosis and giant cells in nodule 1 (fig. 1). The Ziehl-Nielsen stain disclosed a few acid-fast bacilli in the vascular wall (fig. 2). Nodule 2 showed inespecific panniculitis with some acid-fast bacilli in the wall of the apparently normal cutaneous arteries (fig. 3). The clinical evolution was favorable after the use of antituberculous drugs.

CASE 2 — A 26 year-old white male was admitted to HC-FMUSP with a one week complain of arthralgia, ankle tenderness and erythematous nodules with 5 mm in diameter, mainly over the vascular line of the lower and upper extremities. Biopsy of one of the upper limbs nodules showed a medium size artery with a granulomatous process with caseous necrosis and giant cells. Few acid-fast bacilli were visualized in the vascular wall (fig. 4). Antituberculous drugs led

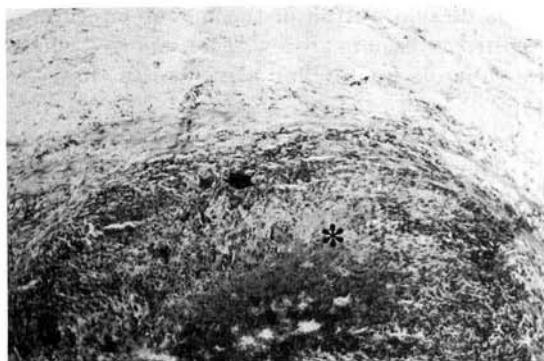

Fig. 1 — Granulomatous arteritis with giant cells (arrow) and caseous necrosis (*). X60.

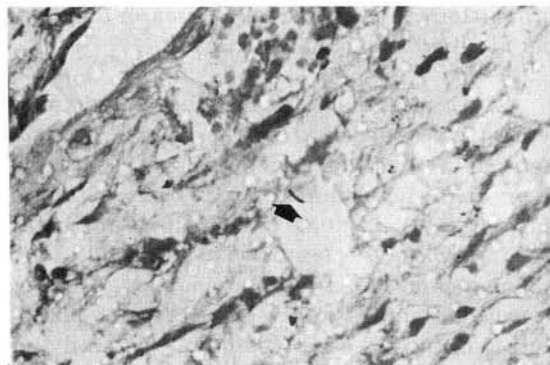


Fig. 2 — Acid-fast bacillus (arrow) in the wall of medium size vessel with granulomatous process. X600.

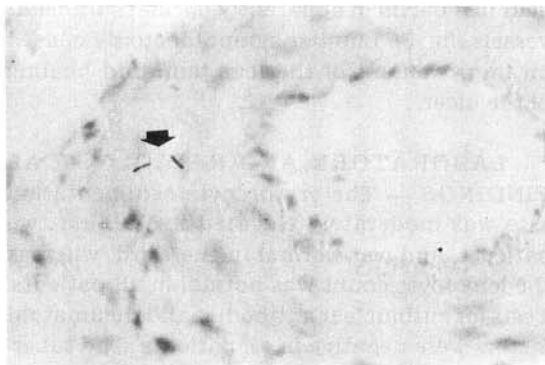


Fig. 3 — Acid-fast bacilli (arrow) in the wall of cutaneous vessel. X600.

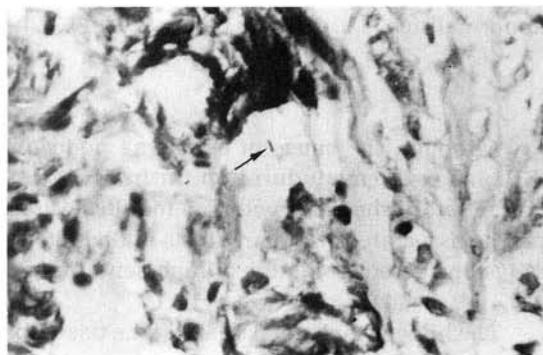


Fig. 4 — Granulomatous arteritis with acid-fast bacillus (arrow). X600.

to improvement of the clinical manifestations in a few weeks.

CASE 3 — A 37 year-old white female was admitted to HC-FMUSP with a ten year history of Raynaud's phenomenon and showing erythematous painful nodules in the lower extremities that had appeared two months before. One nodule from the calf was biopsied and a granulomatous arteritis with rare acid-fast bacilli in the vascular wall was found. She received antituberculous drugs for six months. After two years she was admitted to the Vascular Surgery Division of the HC-FMUSP because for the three latter months she had cyanosis of the toes and ulcerous lesion in one toe, which was found to be due to a femoral-popliteal obstruction. Two months later new erythematous subcutaneous nodules in the leg had appeared. One nodule was biopsied revealing inespecific panniculitis with a few

acid-fast bacilli in apparently normal cutaneous vessels (fig. 5). Lumbar sympathectomy caused an improvement of the legs pain and healing of the ulcer.

LABORATORY AND RADIOLOGICAL FINDINGS — The erythrocyte sedimentation rate was moderately elevated in the first two patients, and was normal in the third, whereas the leukocyte count was normal in all patients. Tests for antinuclear antibodies and rheumatoid factors were negative in all patients. The tuberculin test (PPD) elicited a high response in patient 2 showing even vesicles, but was only moderately altered in the two others. X-ray examination of hands, feet and lungs did not show abnormalities in any of the patients.

DISCUSSION

Although the cause of erythema nodosum (EN) and erythema induratum Bazin (EIB) cannot be established, both clinical manifestations can be associated to tuberculosis and are generally considered a reaction of hypersensitivity¹.

The histopathological study of the tissue excised from nodules of EN usually shows a lymphohistiocytic infiltrate of the subcutaneous tissue and septal blood vessels^{5, 18}. However a granulomatous panniculitis has been described⁷. Tubercle bacilli had never been demonstrated in these lesions. All these changes associated with the fact that the patients showed positive tuberculin test suggest that an immunological mechanism is implicated in EN.

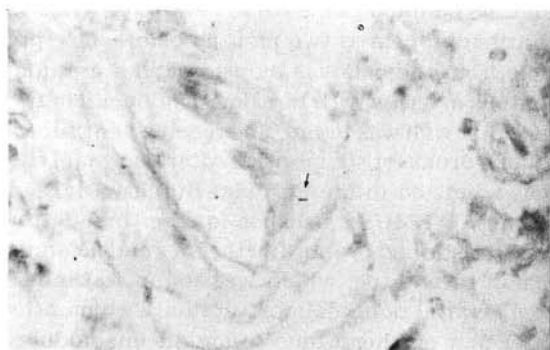


Fig. 5 — Apparently normal cutaneous vessel with acid-fast bacillus (arrow). X600.

In the EIB the subcutaneous tissue shows a granulomatous tuberculoid infiltrate with areas of caseous necrosis. Small and medium size arteries and veins may show invasion of their walls by a granulomatous infiltrate^{3, 13, 15}. The EIB has been considered by many authors as a form of tuberculosis, because most of these patients had a positive tuberculin test; they also may develop ganglionar tuberculosis and have a favorable response to the antituberculous treatment^{1, 6}. Against this assumption is the absence of the mycobacterium in the excised tissue by histological examination¹², by animal inoculation¹⁶ or culture^{1, 3}; in addition some patients have a good response to corticosteroids and the active tuberculosis occurs in a low frequency, no greater than in general population³.

Several authors have expressed that the primary event in EIB is a vasculitis of subcutaneous arteries and veins^{3, 15, 16}. Others believe that EIB is a tuberculous lesion induced by hematogenous dissemination of the mycobacterium¹³. Furthermore there are few cases reported where the tubercle bacilli was identified in these lesions^{9, 13}.

The present report demonstrates some mycobacteries in the wall of apparently normal cutaneous vessels from early subcutaneous nodules that resemble EN; and a few acid-fast bacilli at the wall of granulomatous arteritis from older nodules, that resemble EIB. These findings reveal that EN and EIB can be induced by mycobacterium. These facts are in accordance with the proposition that the first phase of the EIB is an acute inespecific inflammatory reaction enriched by numerous tubercle bacilli and as the proportion of epithelioid cells increases the number of tubercle bacilli decreases⁸.

Differential diagnosis have been made with leprosy where vascular changes may be prominent, as well as the leukocytoclastic vasculitis in erythema nodosum leprosum, or the endothelial proliferation, and thrombosis in the medium-sized vessels of the derm and subcutis in Lucio's phenomenon. These vascular changes generally are accompanied by aggregates of foamy histiocyte containing acid-fast bacilli around the blood vessels or dense acid fast-bacilli in the walls and the endothelial of normal-appearing

vessels as well as in vessels with proliferative changes^{10, 14}.

Vascular tropism of the mycobacterium has been observed in untreated lepromatous leprosy in which endothelial cells of cutaneous blood vessels are massively infected by *Mycobacterium leprae*². This occurrence is believed to follow the breakdown of the endothelial cell barrier¹¹.

The injury of the endothelial cells seems to be an important factor which predisposes the vessels to an invasion by microorganisms. Recently, the first case report of mycobacterial arteritis restricted to the coronary of a chronically rejected transplanted heart was described¹⁷. Suggesting that the rejection reaction contributes to the increased susceptibility of the transplanted vessels to blood-borne infectious agents.

The present report shows that the mycobacterium in the blood stream reaches the wall of blood vessels probably through a defective intima altered by a hypersensitivity reaction or some immunological disfunction. The microorganism in the tissue may cause an inespecific reaction such as EN or a specific reaction such as granulomatous arteritis.

In conclusion, the mycobacterium seems to have a vascular tropism and may cause a primary granulomatous cutaneous arteritis.

RESUMO

Arterite subcutânea por micobactéria.

Os autores descrevem três casos de pacientes com nódulos subcutâneos em diferentes fases de evolução, com sintomas sistêmicos inespecíficos, PPD positivo e raio-X de tórax normal. O estudo anátomo-patológico dos nódulos antigos mostrou arterite granulomatosa e com raros bacilos álcool-ácido resistentes na parede vascular; os nódulos recentes mostraram paniculite inespecífica com alguns bacilos álcool-ácido resistentes na parede de vasos cutâneos aparentemente normais. Esses achados sugerem que a micobactéria tem um tropismo vascular e pode causar arterite granulomatosa.

ACKNOWLEDGEMENTS

Maria de Fátima de Almeida and Noemi Nosomi Taniwaki are acknowledged for technical assistance and Yukie Umeki for typing this manuscript.

REFERENCES

1. ANDERSEN, S. C. — Erythema induratum Bazin treated with isoniazid. *Acta Derm.-vener. (Stockh.)*, 50: 65-68, 1970.
2. CORUH, G. & MACDOUGALL, A. C. — Untreated lepromatous leprosy: histopathological findings in cutaneous blood vessels. *Int. J. Leprosy*, 47: 500-511, 1979.
3. EBERHARTINGER, C. — Das Problem des Erythema induratum Bazin. *Arch. klin. exp. Derm.*, 217: 196-254, 1963.
4. FAN, P. T.; DAVIS, J. A.; SOMER, T.; KAPLAN, L. & BLUESTONE, R. — A clinical approach to systemic vasculitis. *Semin. Arthr. Rheum.*, 9: 248-304, 1980.
5. FINE, R. M. & MELTZER, H. D. — Chronic erythema nodosum. *Arch. Derm.*, 100: 33-38, 1969.
6. FORSTROM, L. & HANNUKSELA, M. — Antituberculous treatment of erythema induratum Bazin. *Acta Derm.-vener. (Stockh.)*, 50: 143-147, 1970.
7. FORSTROM, L. & WINKELMANN, R. K. — Granulomatous panniculitis in erythema nodosum. *Arch. Derm.*, 111: 335-340, 1975.
8. GOETLE, D. K.; JACOBSON, K. W. & DOTY, R. D. — Primary inoculation tuberculosis of the skin. *Arch. Derm.*, 114: 567-569, 1978.
9. ITO, K. — Reconsidering the classical entity of erythema induratum in the age of modern therapy. *Bull. pharm. Res. Inst.*, 34: 24-28, 1961.
10. JOLLIFFE, D. S. — Leprosy reactional states and their treatment. (Review). *Brit. J. Derm.*, 97: 345-352, 1977.
11. KATO, L. & GOZSY, B. — Studies on the physiopathology of experimental murine leprosy. Reticuloendothelial, capillary and mast cell response A review. *Rev. canad. Biol.*, 23: 217-226, 1964.
12. LEVER, W. F. & SCHAUMBURG-LEVER, G. — *Histopathology of the skin*. 8th ed. Philadelphia, JB Lippincott Company, 1983. p. 245-250.
13. MONTGOMERY, H.; O'LEARY, P. A. & BARKER, N. W. — Nodular vascular diseases of the legs. *J. Amer. med. Ass.*, 128: 335-341, 1945.
14. REA, T. H. & LEVAN, N. E. — Lucio's phenomenon and diffuse nonnodular lepromatous leprosy. *Arch. Derm.*, 114: 1023-1028, 1978.

15. SCHNEIDER, W. & UNDEUTSCH, W. — Vasculitides des subcutaneum Feltgewebes. *Arch. klin. exp. Derm.*, 221: 600-610, 1965.
16. TELFORD, E. D. — Lesions of the skin and subcutaneous tissue in diseases of the peripheral circulation. *Arch. Derm. Syph. (Chic.)*, 36: 952-963, 1937.
17. TUNDER, R. M.; RENYA, G. S. & BENSCH, K. — Mycobacterial coronary arteritis in a heart transplant recipient. *Hum. Path.*, 17: 1072-1074, 1986.
18. VILANOVA, X. & PINOL AGUADE, J. — Subacute nodular migratory panniculitis. *Brit. J. Derm.*, 71: 45-50, 1959.

Recebido para publicação em 16/2/1990.