

The importance of nursing care in managing complications related to fully-implantable catheters

IMPORTÂNCIA DA ASSISTÊNCIA DE ENFERMAGEM NO MANEJO DE COMPLICAÇÃO RELACIONADA AO CATETER TOTALMENTE IMPLANTÁVEL

IMPORTANCIA DE LA ATENCIÓN DE ENFERMERÍA EN EL MANEJO DE COMPLICACIÓN RELACIONADA AL CATÉTER TOTALMENTE IMPLANTABLE

Luciana Mendes Bruzi¹, Danielle Cabral Mendes²

ABSTRACT

This is an experience report of a thirty-year-old female patient, diagnosed with recurrence of Acute Myeloid Leukemia, submitted to catheter implantation and presenting surgical wound necrosis. The following were used with success: collagenase, calcium alginate and oil lotion with essential fatty acids. It was found that the complications related to catheters are a great challenge in oncology nursing besides implying a delay in the oncological treatment. Making a correct decision as soon as possible is extremely important and avoids removing the catheter too soon.

DESCRIPTORS

Oncologic nursing
Catheters, indwelling
Wound healing

RESUMO

Trata-se de relato de experiência com paciente do sexo feminino, 30 anos, com diagnóstico de recaída de Leucemia Mielóide Aguda, submetida à implantação de cateter e que apresentou necrose na ferida cirúrgica. Foram utilizados com sucesso: colagenase, alginato de cálcio e loção oleosa à base de ácidos graxos essenciais. Ficou claro que as complicações relacionadas a cateteres conferem um grande desafio à enfermagem oncológica além de determinarem atraso no tratamento oncológico. A correta tomada de decisão o quanto antes é de extrema importância e evita a retirada precoce do cateter.

DESCRIPTORIOS

Enfermagem oncológica
Cateteres de demora
Cicatrização de feridas

RESUMEN

Se trata de un relato de experiencia con paciente de sexo femenino, treinta años, con diagnóstico de recaída de Leucemia Mielóide Aguda, sometida a la implantación de catéter, que presentó necrosis en la herida quirúrgica. Fueron utilizados con éxito: colagenasa, alginato de calcio y loción oleosa a base de ácidos grasos esenciales. Quedó claro que las complicaciones relacionadas a catéteres representan un gran desafío para la enfermería oncológica, además de determinar atraso en el tratamiento oncológico. La correcta toma de decisión y la inmediatez son de extrema importancia y evitan el retirado precoz del catéter.

DESCRIPTORIOS

Enfermería oncológica
Catéteres de permanência
Cicatrización de heridas

¹ Master's student, Health Management, *Universidad Del Mar do Chile*. Specialist in Oncology, *Sociedade Brasileira de Enfermagem Oncológica*. Specialist in Health Systems Auditing, *Faculdade São Camilo*. MBA in Human Resource Management, *Escola Superior Aberta do Brasil*. Nurse, *Centro de Quimioterapia Antineoplásica e Imunoterapia Ltda*. Belo Horizonte, MG, Brazil. lubruzi@gmail.com ² RN, Specialist in Oncology, *Sociedade Brasileira de Enfermagem Oncológica*. Specialist in Health Management, *Instituto de Educação Continuada, Pontifícia Universidade Católica de Minas Gerais*. Nurse, *Centro de Quimioterapia Antineoplásica e Imunoterapia Ltda*. Santa Luzia, MG, Brazil. daniellemendes2004@hotmail.com

INTRODUCTION

For some patients, totally implanted catheters represent an essential part of oncology treatment, as it is often the only access route of chemotherapy medication into the organism. The entire process, ranging from the choice of the most adequate catheter for the patient's anatomy to preoperative exams, the surgical act itself and, finally, the postoperative phase, should be surrounded with care to restrict the aggressiveness of this moment to a minimum.

Catheters are devices for central venous access, developed to permit repeated access to the vascular system for the administration of medication, intravenous fluids, parenteral nutrition solution and blood substances, as well as for blood sample collection⁽¹⁾.

Access to the reservoir is obtained by inserting an exclusive percutaneous Huber needle for punctures in port reservoirs. The format of its tip impedes the removal of silicon fragments from the dome. Conventional needles or scalpels are not recommended for port puncture because they damage it and decrease its useful life, besides the risk of drug extravasation during the infusion and the risk of embolization when fragments are dislocated⁽²⁾.

The surgical techniques used for catheter implantation are: puncture, Seldinger technique, or dissection through the Heimbach and Ivey method. The Seldinger technique (in its original or modified version) is the most used⁽³⁻⁴⁾. The subclavian vein is the first choice when a central venous access is indicated, as it is the place with the smallest risk of catheter-related thrombosis and infection in comparison with the femoral and internal jugular vein⁽⁵⁾.

The normal postoperative healing process should follow the habitual steps of a perfect and coordinated chain of cell events that can be defined as follows: coagulation, inflammation, proliferation, contraction and remodeling⁽⁶⁾. But there are constant interferences in the healing process: anatomic location, skin type, race and surgical technique used. The stitching of the wound is one of the most important steps for safe and efficient healing. When this step occurs inadequately, however, this process is broken and healing is compromised⁽⁷⁾. The mechanic action that is exercised on the tissue during the stitching should permit adequate means to revitalize the wound but, when the strength of the wire's traction interferes in the circulatory process, local ischemia occurs, followed by tissue necrosis. Necrosis is characterized by accidental cell death of part of an organism that is still alive⁽⁸⁾.

In a wound affected by a necrosis area, the first step is to try and remove the dead tissue – this process is called debridement. The goal of debridement is to enhance clean-

ing of the region affected by necrosis. The following debridement methods are used: the autolytic, when enzymes from the same organism are used, which dissolves the necrosis when occlusive dressings are used; the enzymatic, which uses chemical agents that act by selecting the necrotic tissue, causing minimal damage to adjacent tissues; the mechanic, when physical force, such as friction and clamping, is used to remove the dead tissue; and surgical debridement when, as the name itself characterizes, excision of the necrosis is accomplished surgically⁽⁸⁻⁹⁾.

Today, wound treatment is based on a multidisciplinary activity, but which, for nursing, added decision-making power in conducts and a large range of means to demonstrate knowledge. It should be highlighted that treatment success depends, among other factors, on judicious selection and adequate use of the selected products⁽¹⁰⁾. Today, there are various types of dressings in the market that act like the enzymatic debridement method. For the case reported below, three types of dressings were used: collagenase, calcium alginate and oily lotions based on essential fatty acids⁽⁹⁾.

Today, wound treatment is based on a multidisciplinary activity, but which, for nursing, added decision-making power in conducts and a large range of means to demonstrate knowledge.

Collagenase: is an enzymatic dressing based on native and denatured collagen. Its commercial form is in ointments or creams, which serve to remove cell rests from necrotic tissue, that is, it performs chemical debridement through the indirect stimulation of granulation tissue formation and, later, reepithelization⁽¹⁰⁾. Its recommendation is restricted to small wounds.

Calcium Alginate: salts of alginic acid extracted from large brown seaweeds, called laminaria, composed of guluronic and manuronic acids, with incorporated calcium and sodium ions, are industrialized and used for dentistry molds and as absorbent material for surgical dressings. The sodium present in exudate and blood interacts with the calcium in the alginate dressing. Ion exchange helps in autolytic debridement, with high absorption capacity, and results in the formation of a gel that maintains the site moist for healing and induces hemostasis.

Oily lotion: contains caprylic acid, capric acid, lauric acid, soy lecithin, vitamin A, vitamin E, caproic acid and sunflower oil (linoleic acid). It can modify inflammatory and immunological reactions, accelerating the tissue granulation process⁽¹⁰⁾.

EXPERIENCE REPORT

Patient FSM, female, 30 years old, submitted to treatment for Acute Myeloid Leukemia (AML) between April 1998 and April 2001. In October 2008, late relapse of the disease was diagnosed. The patient was immediately hospitalized to start induction chemotherapy, using a second-

line regimen with a hyper-dose (HD) of cytarabine (Ara-c), etoposide (VP-16) and mitoxantrone, administered through a peripheral venous access that was difficult to puncture. During this hospitalization, the patient evolved with phlebitis, oral candidiasis and diarrhea, demanding systemic antibiotics (vancomycin, metronidazole, meropenem) and antifungal therapy (amphotericin B), which provoked even greater exhaustion of the venous network. After bone marrow recovery, the implantation of an indwelling catheter was requested and done on November 13th 2008, followed by hospital discharge one day later. The patient returned for an outpatient consultation on November 24th 2008 when, during the inspection of the catheter implantation scar, tissue necrosis of approximately 2cm was visualized, located at the end of the stitch and at 1 cm above the port. The surgeon responsible for the catheter implantation was contacted, who authorized catheter puncture and suggested daily dressings with saline solution. After discussing the case among the outpatient nursing team and the oncologist responsible for the patient, the decision was made to postpone the catheter use and try and recover the injured area. The nursing team received full autonomy to conduct the case. The patient was informed about the situation and agreed with the conduct the nurses proposed.

The first measure, taken already on November 24th 2008, was the mechanical debridement of the largest possible part of necrotic tissue (Figure 1). The wound still had a region with adhering necrotic tissue. The only coverage the institution had at its disposal was used: collagenesis, in order to start chemical debridement.

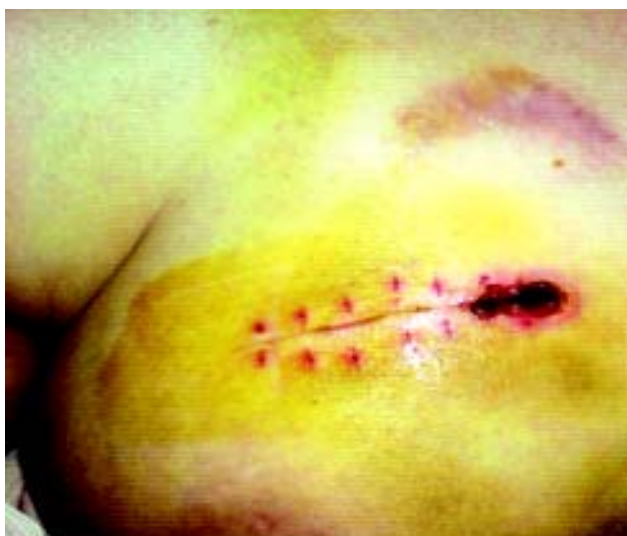

Figure 1 - Tissue necrosis

Dressings were changed daily and included the same conduct until November 28th 2011, when mechanical debridement had to be repeated due to the macerated area (Figure 2).

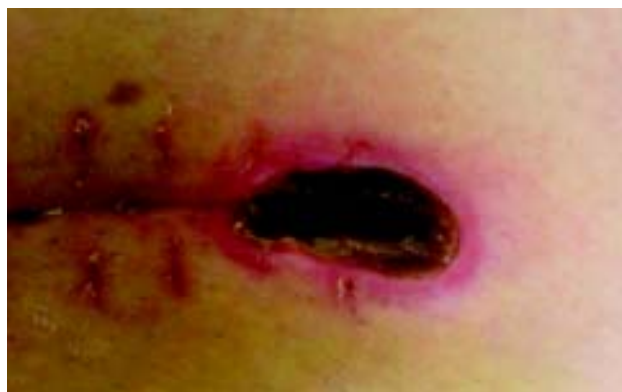

Figure 2 - Presence of macerated tissue

On November 29th 2008, the collagenase coverage was replaced by calcium alginate due to the former's lack of efficiency. On November 30th 2008, the efficiency of the new coverage was perceived, when a large part of the necrosis was removed (Figure 3).

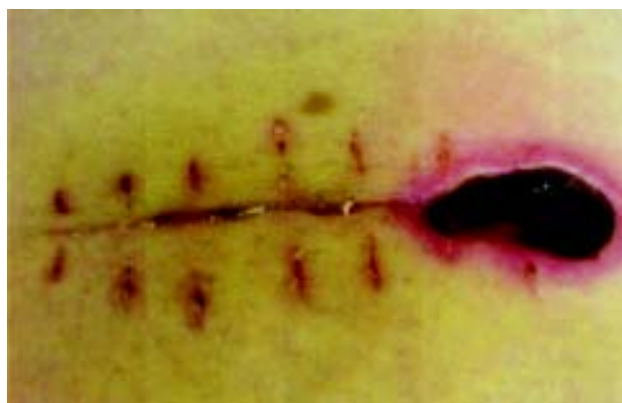

Figure 3 - Slow chemical debridement

On December 03rd 2008, it was assessed that all necrotic tissue had been removed and that only 1/3 of the area continued with fibrin. Calcium alginate dressings were maintained to remove the fibrin. As from that data, linoleic acid (Dersani[®]) started to be applied on the wound edges to protect and recover the area (Figure 4).

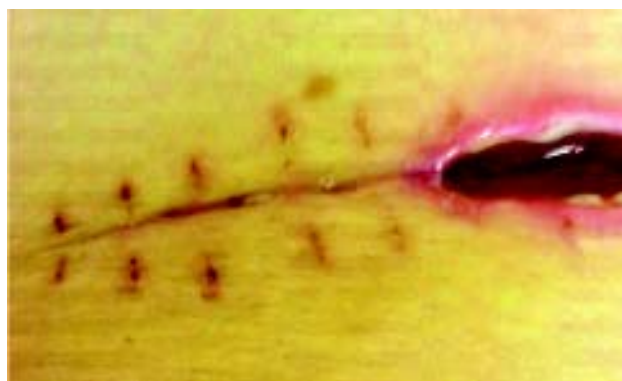


Figure 4 - Absence of necrosis

Although the wound bed had not fully recovered, the nursing team and oncologist decided that the catheter could be used, but with continued daily follow-up. The patient was hospitalized on December 5th 2008 for the second chemotherapy cycle, including five days of cytarabine and two days of mitoxantrone. Due to the proximity between the catheter and the injury, professionals decided to apply two independent dressings, although this was difficult, thus avoiding that contact with the wound dressing or secretion would contaminate the catheter. The nurse at the hospitalization unit was informed about the patient's case and it was agreed upon that the patient would be forwarded to the chemotherapy outpatient clinic daily to receive the dressings. Dressings with calcium alginate in the wound bed, as well as the application of Dersani® on the edges, continued until December 7th 2008. From that date onwards, it was decided to apply only Dersani® to accelerate the epithelization process.

On December 11th 2008, the patient was discharged from hospital, but reaffirmed the commitment to return to the outpatient clinic daily to change the dressing. The nursing team decided to keep up strict wound monitoring as, after the chemotherapy sessions, the patient's immunity would be jeopardized and the risk of local and systemic infection was high. The wound showed a clear granulation process (Figure 5).

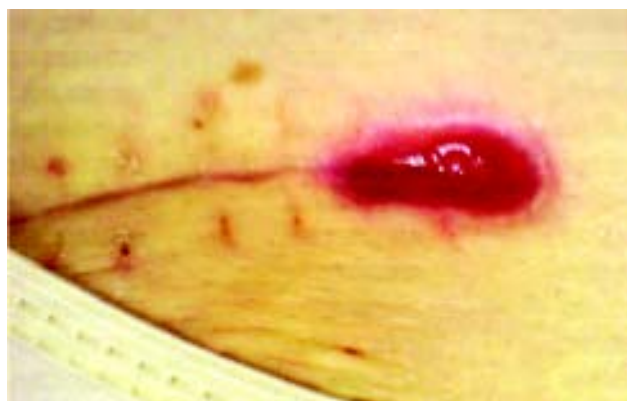

Figure 5 - Clear granulation process

The patient was hospitalized between December 19th and 27th 2008 due to feverish neutropenia. The catheter was again punctured, in this case for antibiotics therapy, following the same previously used conducts: two independent dressings, but this time using only Dersani® for dressing.

As from December 28th 2008, the patient was advised to use Dersani® daily, but at home until the date of the return appointment on January 07th 2009. She was advised to return to the service at the slightest sign of fever or change in the wound's appearance.

Upon her return on January 07th 2009, the patient was hospitalized for the third chemotherapy cycle: cytarabine and etoposide for five days. Once again, the conduct of at-

tending the outpatient clinic daily for dressing changes was maintained, as well as two independent dressings: one for the catheter and another for the wound, which was already going through epithelization in this period. The patient was discharged on January 12th 2009.

DISCUSSION

To conduct this case, some aspects were relevant in the nurses' decision making. One of them is the fact that, according to COREN-MG Deliberation 65/00, nurses should act in the prevention and treatment of cutaneous lesions through consultations, prescribing and orienting treatment but, therefore, they need specific knowledge on the nature of the injury and feasibility of treatment, following the Ethics Code of Nursing Professionals, which according to COFEN Resolution 311/2007 establishes the following responsibilities and Duties:

Art. 5 - Practice the profession with justice, commitment, equity, problem-solving ability, dignity, competence, responsibility, honesty and loyalty.

Art. 12 - Guarantee Nursing care to individuals, families and groups, free from damage deriving from lack of expertise, negligence or imprudence.

Art. 13 - Judiciously assess their technical, scientific, ethical and legal competency and only accept charges or attributions when they are capable of safe performance for themselves and others.

As this is an oncology clinic and an unedited case, the availability of material resources for wound treatment was restricted. Hence, to put the interventions in practice, judicious assessment was needed, of these resources as well as the ontological aspect, with thorough knowledge on the being the care was aimed at⁽¹¹⁻¹²⁾.

Treatment started with the collagenase, as that was the only properly available dressing for chemical debridement. It was immediately replaced by calcium alginate though, due to its characteristic of favoring wound treatment in moist midst, preserving the healing fluid, acting to support autolytic debridement and inducing hemostasis. Another crucial point was the patient's treatment adherence, with daily visits for dressing change. The treatment mixed hospitalization with outpatient consultations and domestic treatment. During hospitalizations, contact with the nurse responsible for the unit was open and, in a consensus between nurses and the patient, it was decided that the nurses from the chemotherapy outpatient clinic would be fully accountable for the wound treatment. For the patient to change the dressings, each day, the team from the hospitalization unit forwarded the patient to the chemotherapy outpatient clinic (which also open daily). During the outpatient treatment phases, the patient received the responsibility for daily returns, including at weekends, after an analysis of her history, social, family, cultural, psychological and spiritual context. After establishing mutual confidence and after the educative process during which the

technique to be used was explained step by step, the patient gained autonomy to change the dressing at home as soon as the wound had reached the epithelization phase. Then, the use of Dersani[®] was established, which revitalizes and preserves the skin's hydric balance, improving elasticity, contributing to reestablish skin integrity. Returns for nursing assessment were of course periodic, until the end of the treatment was successfully determined.

CONCLUSION

Nowadays, a wide range of dressings and topic agents exist in the market. Nurses should critically analyze the cost/

benefit of their actions with a view to treatment success. For wound treatment in the reported case, the agents Calcium Alginate and Dersani[®] were selected based on the assessment of wound characteristics and scientific evidence regarding the products, presented in literature, in combination with a relatively low cost. As treatment involved a team of three nurses, communication was quite effective. The case was discussed among these team members and with the patient, started with the choice of treatment and continued during the entire process, until discharge. Daily nursing evolutions, together with photographic records of the process, offered extremely valuable support to monitor wound evolution and later develop this paper.

REFERENCES

1. Niederhuber JE, Ensminger W, Gyves JW, Liepman M, Doan K, Cozzi E. Totally implanted venous and arterial access system to replace external catheter in cancer treatment. *Surgery*. 1982;92(4):706-12.
2. Wolosker N, Yazbek G, Nishinari K, Malavolta LC, Munia MA, Langer M, et al. Totally implantable venous catheters for chemotherapy: experience in 500 patients. *Sao Paulo Med J*. 2004;122(4):147-51.
3. Pinto RD, Lissa FCT, Covatti E, Scheffer LG, Junqueira Júnior G, Sampaio JA. Alternativa técnica para a colocação de cateter totalmente implantável para quimioterapia. *Acta Oncol Bras*. 1997; 17(1):33-6.
4. Kock HJ, Pietsch M, Krause U, Wilke H, Eigler FW. Implantable vascular access systems: experience in 1500 patients with totally implanted central venous port systems. *World J Surg*. 1998; 22(1):12-6.
5. Godoy JL, Otta EK, Miyazaki RA, Bitencourt MA, Pasquini R. Central venous access through the external jugular vein in children submitted to bone marrow transplantation. *Braz Arch Biol Technol*. 2005;48(1):41-4.
6. Mandelbaum SH, Di Santis EP, Mandelbaum MHS. Cicatrizaçãõ: conceitos atuais e recursos auxiliares. *An Bras Dermatol*. 2003;78(5):525-40.
7. Dantas SRPE. Aspectos históricos do tratamento de feridas. In: Jorge SA. *Abordagem multiprofissional do tratamento de feridas*. São Paulo: Atheneu; 2003. p. 3-6.
8. Guidugli-Neto J. *Elementos de patologia geral*. São Paulo: Grupo GEN; 1997.
9. Dealey C. *Cuidando de feridas: um guia para as enfermeiras*. São Paulo: Atheneu; 2001. p. 49-65.
10. Ferreira E, Lucas R, Rossi LA, Andrade D. Curativo do paciente queimado: uma revisão de literatura. *Rev Esc Enferm USP*. 2003;37(1):44-51.
11. Conselho Regional de Enfermagem de Minas Gerais (COREN-MG). Deliberação 65/00. Dispõe sobre as competências dos profissionais de enfermagem na prevenção e tratamento das lesões cutâneas [Internet]. Belo Horizonte; 2000 [citado 2009 nov. 22]. Disponível em: <http://www.corenmg.gov.br/sistemas/app/web200812/interna.php?menu=0&subMenu=2&prefixos=65>
12. Conselho Federal de Enfermagem (COFEN). Resolução COFEN 311/2007. Código de Ética dos Profissionais de Enfermagem [Internet]. Brasília; 2007 [citado 2009 nov. 22]. Disponível em: <http://www.portalcofen.gov.br/sitenovo/node/4394>