

## Topical treatment of actinic keratosis with imiquimod 5% cream

[Tratamento tóxico de ceratose actínica com imiquimod creme 5%]

T.N.A. Garcez<sup>1</sup>, D.G. Gerardi<sup>2</sup>, K.C. Ferreira<sup>2</sup>, C.S. Cardoso<sup>2</sup>,  
P.D. Möschbacher<sup>1</sup>, E.A. Contesini<sup>2</sup>

<sup>1</sup>Aluno de pós-graduação – Universidade Federal do Rio Grande do Sul – UFRGS – Porto Alegre, RS

<sup>2</sup>Universidade Federal do Rio Grande do Sul – UFRGS – Porto Alegre, RS

### ABSTRACT

The viability and the efficiency of imiquimod 5% cream in a cat which suffered from nasal actinic keratosis were evaluated. The procedures were carried out at home by the owners themselves. Six packets of the cream were used, one per week, in three consecutive daily applications, with a four-day interval (without treatment). The cytological results were negative for neoplastic cells 30 days after the end of the treatment. A clinical revision was conducted 18 months later and the animal showed no signs of recurrence. The cream proved to be safe and efficient. There are no reports regarding efficiency in animals concerning the treatment with imiquimod 5% cream and also regarding other effects related to this treatment. A case report presenting a positive response can reveal with therapeutic possibilities that it would be easily available and applicable for all professionals. In the future it would be a new alternative to avoid progressions of this kind of neoplasia which is often observed in the small animal clinic.

Keywords: cat, oncology, actinic dermatitis, immunomodulators

### RESUMO

*Avaliaram-se a viabilidade e a eficácia da utilização do imiquimod creme 5% em um gato portador de ceratose actínica nasal. As aplicações foram realizadas no domicílio, pelos proprietários, sendo utilizados seis sachês do creme, um por semana, em protocolo de três aplicações diárias consecutivas e quatro dias de descanso (sem tratamento). Após 30 dias do término do tratamento, obteve-se citologia negativa para células neoplásicas. Em revisão clínica 18 meses após o tratamento, o paciente apresentava-se sem sinais de recidiva. O protocolo mostrou-se seguro e eficaz. Em animais não há relatos sobre a eficácia da terapia com imiquimod, bem como sobre efeitos adversos decorrentes deste tratamento. A apresentação de um caso em que se observou resposta positiva pode descartar uma nova possibilidade terapêutica, acessível a todo clínico, que poderá evitar a progressão destas neoplasias que são frequentemente observadas na clínica de pequenos animais.*

*Palavras-chave: gato, oncologia, dermatite actínica, imunomoduladores*

### INTRODUCTION

Cancer is one of the main causes of death in pets (Bentubo *et al.*, 2007). Squamous cell carcinoma (SCC) is one of the most common skin tumors in cats (Altamira and Vilafranca, 1998). It usually occurs in regions of lower fur density and lesser pigmentation such as the nose, pinnae and periocular region (Rodaski and Werner, 2009). In mammals, the causes and pathogenetic

mechanisms of the disease are very similar to others involved in actinic keratosis (Festa-Neto, 2002), a dysplasia of keratinocytes (Kagy and Amonette, 2000) that is usually a consequence of solar dermatitis (Festa-Neto, 2002; Grupta *et al.*, 2002).

Although they grow slowly and rarely are metastatic, these injuries can be profoundly invasive and destructive. A number of

---

Recebido em 12 de setembro de 2011

Aceito em 10 de setembro de 2012

E-mail: tuane.garcez@gmail.com

therapeutic procedures (including surgery, radiotherapy, photodynamics, cryosurgery and chemotherapy) have been used to treat SCC (Cutler *et al.*, 2000; Bentubo *et al.*, 2007).

Topical immunomodulators are a new alternative for clinical treatment. Imiquimod 5% cream is an imidazoquinoline amine with the property of modifying the immune response (Altamira and Vilafranca, 1998). The exact action mechanism is yet unknown; nevertheless, this drug seems to show antiviral and antitumoral effects by inducing cytokines and increasing cell-mediated cytolytic activity (Sauder, 2000; Suzuki *et al.*, 2000).

In humans, this medicine is approved for the treatment of actinic keratosis and genital injuries caused by the papillomavirus. It is also used with variable success in basal cell carcinoma, Bowen's disease (squamous cell carcinoma in situ), squamous cell carcinoma, epitheliotropic lymphoma and keratoacanthoma (Smith *et al.*, 2004). The adverse effects that are considered possible or are probably related to the use of the drug include disorders at the application site (red skin, scaling skin, skin erosion, excoriation, edema, hypopigmentation, pain, burning, itch); reactions in some remote areas of the skin (bleeding, tenderness, pain, burning, itch) and systemic reactions (fatigue, fever, symptoms similar to those of flu, disorders of the central and peripheral nervous system – headache, gastrointestinal signs and myalgia) (Grupta *et al.*, 2002).

The purpose of this study was to evaluate the viability and efficiency of the use of Imiquimod 5% cream (Ixium<sup>®</sup>, Imiquimod, Farmoquímica S/A, Brazil) in a cat which suffered from nasal actinic keratosis.

### **CASE REPORT**

A 9-year-old semi-domiciled male cat without definite breed was evaluated by the ONCOVET-UFRGS service. The animal showed a slow-

growing non-itchy, crusty and erythematous lesion, with nasal localization on the right side measuring 1 centimeter in diameter. After the clinical exam and evaluation of the swab collected, a cytopathological result suggestive of actinic keratosis was obtained. Complementary exams such as a complete blood count, biochemical profile and chest radiography did not show other changes.

Considering that surgery was refused by the owners, the decision was made to adopt a treatment with Imiquimod 5% cream because it was a less invasive alternative compared to the procedures. The owners were informed that this was an experimental treatment for the species with very little scientific data on its efficiency and side effects.

The procedures were carried out at home by the owners themselves. Six packets of the cream were used, one per week, in three consecutive applications everyday, with a four-day interval (without treatment). Before the application, the injured site was cleaned with glycerine soap. The medicine was applied with the use of adequate gloves in enough quantity so as to cover the entire lesion area. After eight hours, the drug was removed with glycerine soap and copious water, as recommended by the manufacturer.

During the treatment period, exposure to the sun was avoided and the use of an Elisabethan collar was recommended. In the beginning an intense local reaction was noted, which indicated an active inflammatory process (Figure 1). All injuries healed, leaving the site with a mild erythematous macule which disappeared progressively. Hyperchromia and mild residual alopecia were also observed on the treated site (Figure 2). As a side effect, the animal showed intense sialorrhoea upon some applications, which, according to the owners' report, coincided with moments when the animal took the drug by licking it, although the owners were advised that the animal should continuously wear the collar.

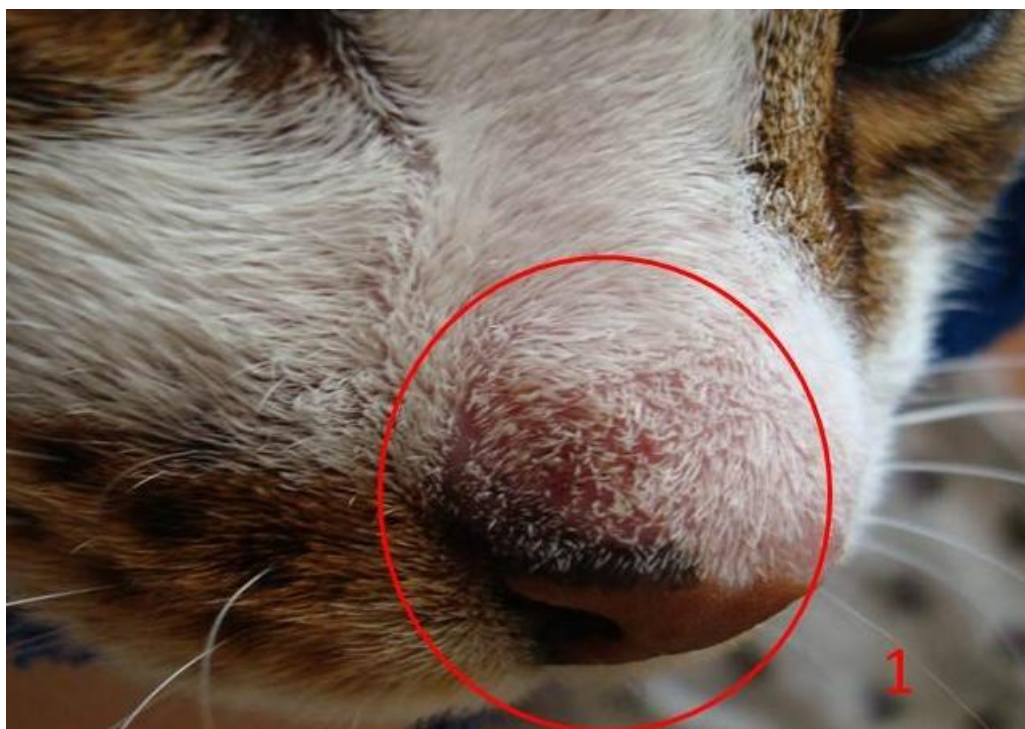

Figure 1. A 9-year-old male cat without definite breed, semi-domiciled, showing local reaction indicative of an active inflammatory process during treatment with Imiquimod 5% cream.

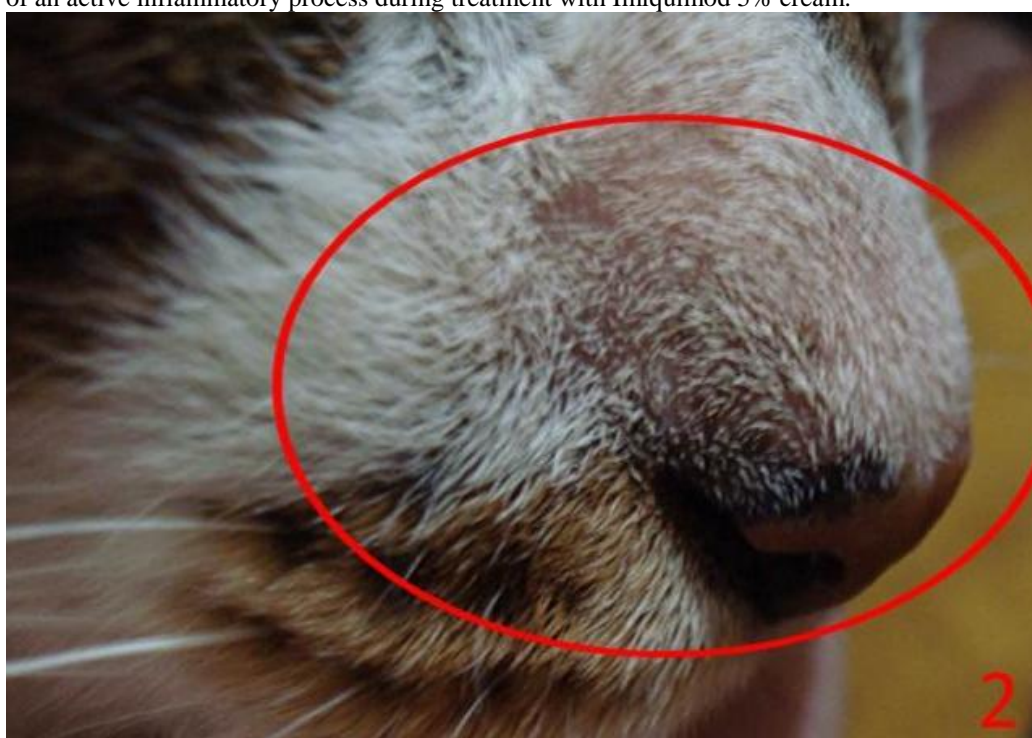


Figure 2. A 9-year-old male cat without definite breed, semi-domiciled, showing hyperchromia and local residual alopecia after treatment with Imiquimod 5% cream.

A new injury swab was collected 30 days after the end of the applications. According to the second cytopathological report, no tumoral cells were observed in the sample. In the clinical follow-up – about 18 months after the treatment – the animal was healthy and without any signs of tumor recurrence.

## DISCUSSION

The fact that the animal showed a slow-growing injury, which was erythematous, crusty and non-itchy, in a region of lesser fur density and poorly pigmented skin, and also considering that it was kept under a semi-domiciled regime with free access to the street, may indicate that it was a case of actinic keratosis resulting from exposure to the ultraviolet radiation of the sun, considering that high exposure to sunlight in cats can cause preneoplastic changes in keratinocytes and, in this stage, clinical signs are already present, with formation of crusts and ulcerations in less protected areas, as the nasal one, eyelids, and auricular region (Altamira and Vilafranca, 1998).

A cytopathological exam reinforced the clinical suspicion, indicating actinic keratosis. The histopathological evaluation was not done due to refusal by the owner.

The best method for applying Imiquimod still remains unclear (Rinne *et al.*, 2000). However, most authors agree that the scheme must be kept until the injury disappears completely or for a maximum treatment period of 16 weeks (Cutler *et al.*, 2000; Grupta *et al.*, 2002). In the case presented here, it was decided that Imiquimod 5% cream should be used in a regimen of three consecutive applications everyday with a four-day interval, according to the protocol adopted by Peters-Kennedy *et al.* (2008) in the same species. The protocol was followed for 6 weeks, when the clinical aspect indicated that the injury had completely disappeared.

Despite the adverse effects reported (Grupta *et al.*, 2002) during the use of the medicine in this case, significant side effects have not been observed. The intensification of the inflammatory reaction in the beginning is plausible, considering the action mechanism of the medicine. This reaction, nevertheless, was transitory and concentrated in a small alopecic, hyperchromic residual area. Regarding the

sialorrhoea that was seen in some episodes, it coincided with moments when the animal took the medicine by licking. Other changes were not observed.

The individuality of the animal and the will of its owners were strong determinant factors for the decision regarding the treatment to be adopted. Although more studies are needed about the use of Imiquimod in animals which suffer from skin neoplasia, this cream proved to be safe and efficient. It can be an interesting alternative in cases of surgery refusal for aesthetic reasons or clinical advice.

## ACKNOWLEDGMENTS

Thanks to the HCV-UFRGS and ONCOVET-UFRGS team.

## REFERENCES

- ALTAMIRA, J.; VILAFRANCA, M. Estúdio retrospectivo de tumores cutâneos en el perro y el gato. In: ALTAMIRA, J. E VILAFRANCA, M. *Oncología Cutanea. Canis et felis*, v.32, p.57-67, 1998.
- BENTUBO, H.D.L.; TOMAZ, T.A.; BONDAN, E.F. *et al.* Expectativa de vida e causas de morte em cães na área metropolitana de São Paulo (Brasil). *Cienc. Rural*, v.37, p.1021-1026, 2007.
- CUTLER, K.; KAGEN, M.H.; DON, P.C. *et al.* Treatment of facial verrucae with topical Imiquimod cream in a patient with human immunodeficiency virus. *Acta Derm. Venereol.*, v.80, p.134-135, 2000.
- FESTA-NETO, C. Tratamento tópico do carcinoma basocelular superficial e nodular pelo Imiquimode creme a 5%: observação de 10 casos. *An. Bras. Dermatol.*, v.77, p.693-698, 2002.
- GRUPTA, A.; BROWNE, M.; BLUHM, R. Imiquimod: A review. *J. Cutan. Med. Surg.*, v.6, p.554-560, 2002.
- KAGY, M.K.; AMONETTE, R. The use of Imiquimod 5% cream for the treatment of superficial basal cell carcinomas in a basal cell nevus syndrome patient. *Dermatol. Surg.*, v.26, p.577-579, 2000.

PETERS-KENNEDY, J.; SCOTT, D.W.; MILLER, W.H. Apparent clinical resolution of pinnal actinic keratosis and squamous cell carcinoma in a cat using topical Imiquimod 5% cream. *J. Feline Med. Surg.*, v.10, p.593-599, 2008.

RINNE, D.; LINHART, C.; SCHOFER, H. Lip papillomatosis in immunodeficiency: therapy with Imiquimod. *Br. J. Dermatol.*, v.142, p.196-197, 2000.

RODASKI, S.; WERNER, J. Neoplasias de pele. In: DALECK, C.R. *et al. Oncologia em cães e gatos*. São Paulo: ROCA, 2009. p.254-279.

SAUDER, D.N. Immunomodulatory and pharmacologic properties of Imiquimod. *J. Am. Acad. Dermatol.*, v.43, p.6-11, 2000.

SMITH, K.J.; HAMZA, S.; SKELTON, H. Topical imidazoquinoline therapy of cutaneous squamous cell carcinoma polarizes lymphoid and monocyte/ macrophage populations to a Th1 and M1 cytokine pattern. *Clin. Exper. Dermatol.*, v.29, p.505-512, 2004.

SUZUKI, H.; WANG, B.; SHIVJI, G.M. *et al.* Imiquimod, a novel topical immune response modifier, induces migration of Langerhans' cells. *J. Invest. Dermatol.*, v.114, p.135-141, 2000.