



*Arq. Bras. Med. Vet. Zootec.*, v.72, n.6, p.2266-2270, 2020

## Aberrant right subclavian artery in a dog – case report

[*Ectopia de artéria subclávia direita em cão - relato de caso*]

T.G. Tavares<sup>1</sup>, C.V.B. Lima<sup>2</sup>, L.P. Romão<sup>1</sup>, J.F.V. Marin<sup>3</sup>,  
D.S. Silveira<sup>4</sup>, L.C. Nunes<sup>4</sup>, J.N. Boeloni<sup>4\*</sup>

<sup>1</sup>Aluno de graduação - Centro de Ciências Agrárias e Engenharias - Universidade Federal do Espírito Santo - Alegre, ES

<sup>2</sup>Aluno de residência - Hospital Veterinário - Universidade Federal do Espírito Santo - Alegre, ES

<sup>3</sup>Apoio técnico - Centro de Ciências Agrárias e Engenharias - Universidade Federal do Espírito Santo - Alegre, ES

<sup>4</sup>Centro de Ciências Agrárias e Engenharias - Universidade Federal do Espírito Santo - Alegre, ES

### ABSTRACT

The brachiocephalic trunk and the left subclavian artery originate from the aortic arch, and both supply blood to the head, neck, and thoracic limbs. Anatomical variations, such as an aberrant right subclavian artery, are congenital conditions rarely observed in dogs. Thus, the objective of the present report was to describe a case of aberrant right subclavian artery in a 9-year-old Dalmatian. However, this anomaly was a finding in which the patient was asymptomatic during its 9 years of life and only at this age did he exhibit signs including sialorrhea, vomiting, hyporexia, and noisy deglutition. Blood count, biochemical profile, and thoracic radiography led to a diagnosis of megaesophagus and aspiration pneumonia. Despite the recommended treatment, the patient did not respond well; as such, the owner elected to euthanize the animal. On necropsy, the right subclavian artery originated directly from the aortic arch, followed a route from left to right dorsally to the esophagus, and then formed an impression of the vascular path over the muscular wall of the esophagus. The esophagus, in turn, exhibited a flaccid wall and dilation in the caudal portion to the vascular path made by the ectopic position of the right subclavian artery.

Keywords: vascular anomaly, aortic arch, esophageal dilation, canine

### RESUMO

*O tronco braquiocéfálico e a artéria subclávia esquerda emergem do arco aórtico e são responsáveis por fazerem o suprimento sanguíneo para cabeça, pescoço e membros torácicos. Variações anatômicas, como a ectopia da artéria subclávia direita, são alterações congênitas raramente encontradas em cães, cujas alterações do sistema digestivo acontecem em pacientes recém-desmamados e não em adultos. Assim, o objetivo deste relato é descrever um caso de ectopia da artéria subclávia direita em uma cadela, Dálmata, de nove anos de idade. No entanto, essa anomalia foi um achado do qual o paciente foi assintomático durante os nove anos de vida e somente com essa idade apresentou sinais como sialorreia, vômito, hiporexia e deglutição ruidosa. O hemograma e os perfis bioquímicos, associados à radiografia torácica, levaram a um diagnóstico de megaesôfago e pneumonia aspirativa. Mesmo seguindo o tratamento recomendado, houve piora clínica do quadro e o animal foi submetido à eutanásia. À macroscopia, a artéria subclávia direita originava-se direto do arco aórtico, fazia um percurso da esquerda para a direita dorsalmente ao esôfago e, então, formava uma impressão do trajeto vascular sobre a parede muscular do esôfago. O esôfago, por sua vez, apresentava parede flácida e dilatação na porção caudal ao trajeto vascular feito pela posição ectópica da artéria subclávia direita.*

*Palavras-chave: anomalia vascular, arco aórtico, dilatação esofágica, canino*

### INTRODUCTION

In dogs, the aortic arch originates from the brachiocephalic trunk and the left subclavian artery, supplying blood to the head, neck, thorax, and thoracic limbs. The brachiocephalic trunk is

located ventral to the esophagus and trachea. It branches into the left and right common carotid arteries and into the left subclavian artery, which gradually diverts to the right before going around the first rib to enter the thoracic limb (König and Liebich, 2016).

Recebido em 6 de junho de 2020

Aceito em 25 de agosto de 2020

\*Autor para correspondência (*corresponding author*)

E-mail: jankerle@gmail.com

Although rare, anatomical variations, such as aberrant right subclavian artery (ARSA), can occur in animals including cats (Cinti *et al.*, 2018), camelids (Shojaei *et al.*, 2011), and dogs (Culau *et al.*, 2004; Christiansen *et al.*, 2007). For example, Paiva (1948) described the occurrence of this anomaly in two bitches without esophageal stenosis. DeKleer (1970) reported this vascular condition in a male dog with an increased lumen of the esophagus, but also without clinical changes. Tsukise *et al.* (1972) cited the presence of this anomaly in two dogs with no clinical signs. Bezuidenhout (1989) described a case of ARSA in one bitch, but without obstruction or dysphagia. Oliveira *et al.* (2001) cited the occurrence in one bitch during the practice of dissecting. Finally, Culau *et al.* (2004) identified this anomaly in eight dogs (five males, three females) with no structural changes in the esophagus or trachea.

In this context, aside from ARSA being rarely encountered in dogs, when it does occur, changes in the digestive system are observed in newly weaned animals (Yoon and Jeong, 2011) but not in adult individuals. Thus, the objective of this report is to describe a case of ARSA in a 9-year-old female Dalmatian presenting with megaesophagus, sialorrhea, vomiting, hyporexia, and noisy deglutition.

### CASE REPORT

A 9-year-old female Dalmatian was admitted to the Veterinary Hospital of the Federal University of *Espírito Santo* (HOVET-UFES), exhibiting drooling, vomiting, a two-month history of hyporexia, and noisy deglutition. On physical examination, the patient was apathetic, exhibiting frequent swallowing movements and breathlessness. In addition, auscultation of the left caudal pulmonary lobe topography revealed “pulmonary silence.” After clinical evaluation, the following complementary tests were requested: blood count; renal profile (urea and creatinine); and liver profile (alanine aminotransferase, alkaline phosphatase, total protein, and albumin), in addition to serum calcium. Chest radiography was also requested to investigate possible pneumopathy associated with the clinical picture.

Results of the biochemical profile and serum calcium levels were within the normal ranges. However, the blood count revealed leukocytosis

with neutrophilia and monocytosis, normocytic normochromic anemia, hyperproteinemia, and thrombocytosis. In addition, chest radiography revealed dilation of the caudal segment of the esophagus (Figure 1), as well as important changes in the pulmonary pattern consistent with pneumonia. Based on these results, the patient was diagnosed with megaesophagus associated with aspiration pneumonia.

Dietary management using a high-calorie paste should be administered with the animal in a bipedal position to facilitate food transit to the stomach. Feeding should be performed in small portions and at a higher daily frequency to avoid gastric overload and distension. Gastric protectors (omeprazole and ranitidine), an antiemetic (ondansetron), and a prokinetic (metoclopramide) are often added to the prescription. For the treatment of pneumonia in this case, antibiotic therapy (amoxicillin with potassium clavulanate) was also prescribed all at therapeutic doses and frequencies recommended for dogs.

Three days later, however, the patient was admitted to hospital in critical clinical condition. The dog underwent intravenous fluid therapy with Ringer’s lactate, antiemetic (maropitant), superficial sedation (butorphanol), antipyretic (dipyrone), and antibiotics (ceftriaxone and metronidazole). In addition, temporary fasting was implemented to reduce regurgitation and prevent recurrent aspiration pneumonia. Unfortunately, the patient did not respond, and the owner elected to euthanize the animal.

The animal was transferred to the Animal Pathology Laboratory at HOVET-UFES for autopsy. During macroscopic examination of the thoracic organs, the right subclavian artery originated straight from the aortic arch, traversing over the esophagus from the left to the right side, which generated a pressure mark on the dorsal esophageal wall. Moreover, the esophagus exhibited a flaccid wall and dilation of the segment caudal to the ARSA (Figure 2), and the cranial lobes of the lungs had a firm and “crackly” consistency. The cranial portions of the caudal lobes were hypocrepitant, with firm areas featuring pneumonia. In addition, the animal exhibited moderate hydropericardium and a turbid-white liquid within the urinary bladder associated with the presence of microcalculi.

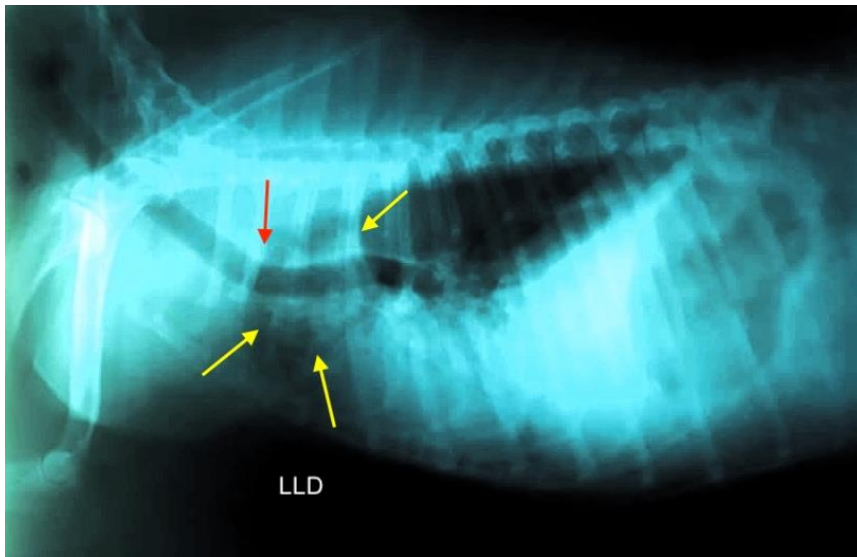


Figure 1. A 9-year-old female Dalmatian with a vascular anomaly. Thoracic radiography revealing megaesophagus and aspiration pneumonia. Right lateral-lateral projection revealing ventralization of the trachea (red arrow) and esophageal dilation with retention of food content (yellow arrows). Lung areas with a marked bronchoalveolar pattern.

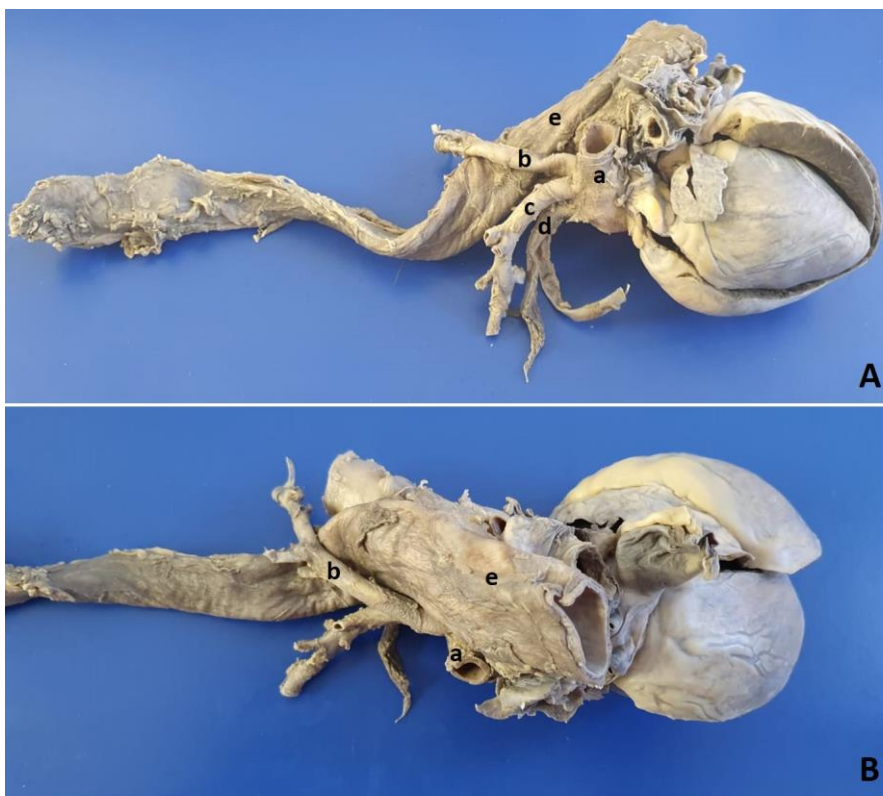

Figure 2. A 9-year-old female Dalmatian with a vascular anomaly. A) Aberrant right subclavian artery originating straight from the aortic arch (a) traversing over the esophagus (e). B) Aberrant right subclavian artery (a) and dilation of the caudal esophageal segment (e) confirming megaesophagus. (a) aortic arch; (b) right subclavian artery; (c) left subclavian artery; (d) brachiocephalic trunk; and (e) esophagus.

## DISCUSSION

In the present case, the right subclavian artery was considered to be anatomically atypical, given that it arose straight from the aortic arch and generated a pressure mark on the dorsal esophageal wall. Under normal conditions, this artery arises from the brachiocephalic trunk (König and Liebich, 2016).

Anomalies of the aortic arch—such as ARSA—are the most common congenital aortic arch anomalies described in humans (Natsis *et al.*, 2017; Jan *et al.*, 2018; Krupiński *et al.*, 2019) but rarely in veterinary medicine (Culau *et al.*, 2004; McKenzie *et al.*, 2010; Shojaei *et al.*, 2011; Cinti *et al.*, 2018). This congenital vascular condition occurs as a result of atypical fetal development. Paiva (1948) described the complete atrophy of the right fourth aortic arch as the reason for the anomaly during fetal development, in which there is a persistence of the right root of the primitive dorsal aorta arising from the aberrant right subclavian artery. According to Vitums (1962), this anomaly can have two origins. The first is the union of the distal part of the right dorsal aortic root—which is normally reduced—with the sixth right cervical intersegmental artery. The second reason is that only the distal segment of the right subclavian artery remains persistent (the right cervical intersegmental artery).

Anomalies of the right subclavian artery or other vessels of the aortic arch in dogs are incidental findings during chest imaging, postmortem examinations, and dissections, often without association with other clinical conditions (Paiva, 1948; Vitums, 1962; DeKleer, 1970; Tsukise *et al.*, 1972; Bezuidenhout, 1989; Culau *et al.*, 2004). In addition, this anomaly can be observed in association with changes and clinical signs in the gastrointestinal tract; however, these manifestations occur in newly weaned individuals (Christiansen *et al.*, 2007; McKenzie *et al.*, 2010; Shojaei *et al.*, 2011; Yoon and Jeong, 2011) and not in adult individuals, as described in the present report, in which the Dalmatian manifested changes in the digestive and respiratory system only after 9 years of age. The animal exhibited megaesophagus and clinical signs, including

sialorrhoea, vomiting, hypoxia, noisy deglutition, and aspiration pneumonia.

Megaesophagus is a dilation of the esophageal lumen due to hypomotility, which can be classified as acquired or congenital; it can be caused by a wall or extraluminal obstruction, or by a dysfunction in esophageal musculature innervation, respectively. It is important to highlight that esophageal dilation, in the animal described in the present study, was located caudally to the vascular path taken by the aberrant position of the right subclavian artery. This demonstrates that the megaesophagus was not caused by this anomaly but by another etiology because a megaesophagus is usually cranial to the obstruction (Guedes *et al.*, 2016), thus further confirming that the clinical changes exhibited by the animal were not due to ARSA.

Despite implementation of the correct protocol, the patient evolved to a worse clinical condition. Overall, the management of megaesophagus varies according to etiology. For example, pasty food and bipedal feeding position management should be introduced (Muldoon *et al.*, 1997). The use of a gastric or nasogastric feeding tube should be considered when the patient continues to exhibit regurgitation. It helps to recover the esophageal mucosa and prevent malnutrition (Shojaei *et al.*, 2011; Cinti *et al.*, 2018). Similar to what was done for the referred patient, animals with aspiration pneumonia should also undergo antibiotic therapy (Tanaka *et al.*, 2010). Once the patient's nutritional status recovers, the best surgical approach is recommended (McKenzie *et al.*, 2010; Cinti *et al.*, 2018). Imaging tools are useful and can help in choosing the best surgical access and preventing complications (Cinti *et al.*, 2018).

## CONCLUSION

Based on the animal's medical history and the results of complementary examinations and autopsy findings, this particular case of ARSA occurred in a 9-year-old Dalmatian that manifested changes in the digestive and respiratory system only in adulthood.

## REFERENCES

- BEZUIDENHOUT, A.J. Anomalous origins of the right subclavian and common carotid arteries in the dog. *J. S. Afr. Vet. Assoc.*, v.60, p.215-218, 1989.
- CHRISTIANSEN, K.J.; SNYDER, D.; BUCHANAN, J.W.; HOLT, D.E. Multiple vascular anomalies in a regurgitating German shepherd puppy. *J. Small Anim. Pract.*, v.48, p.32-35, 2007.
- CINTI, F.; DELLA SANTA, D.; BORGONOVO, S. *et al.* Aberrant right subclavian artery causing megaesophagus in three cats. *J. Small Anim. Pract.*, v.60, p.571-574, 2018.
- CULAU, P.O.V.; OLIVEIRA, J.C.D.; RECKZIEGEL, S.H.; LINDEMANN, T. Origem ectópica da artéria subclávia direita e do tronco bicarotídeo no cão. *Cienc. Rural*, v.34, p.1615-1618, 2004.
- DeKLEER, V.S. An anomalous origin of the right subclavian artery in the dog. *Br. Vet. J.*, v.127, p.76-82, 1970.
- GUEDES, R.M.C.; BROWN, C.C.; SEQUEIRA, J.L.; REIS Jr, J.L. Sistema digestório. In: SANTOS, R.L.; ALESSI, A.C. *Patologia veterinária*. 2.ed. Rio de Janeiro: Roca, 2016. p.87-180.
- JAN, S-L.; LIN, M-C.; CHAN, S-C. Mid-term follow-up study of neonatal isolated aberrant right subclavian artery. *Cardiol. Young*, v.28, p.1024-1030, 2018.
- KÖNIG, H.E.; LIEBICH, H.G. 6.ed. *Anatomia dos animais domésticos*. São Paulo: Artimed, 2016. 804p.
- KRUPIŃSKI, M.; IRZYK, M.; MOCZULSKI, Z. *et al.* CT evaluation of aberrant right subclavian artery: anatomy and clinical implications. *Cardiol. Young*, v.29, p.128-132, 2019.
- MCKENZIE, E.C.; SEGUIN, B.; CEBRA, C.K. *et al.* Esophageal dysfunction in four alpaca crias and a llama cria with vascular ring anomalies. *J. Am. Vet. Med. Assoc.*, v.237, p.311-316, 2010.
- MULDOON, M.M.; BIRCHARD, S.J.; ELLISON, G.W. Long-term results of surgical correction of persistent right aortic-arch in dogs: 25 cases. *J. Am. Vet. Med. Assoc.*, v.210, p.1761-1763, 1997.
- NATSIS, K.; DIDAGELOS, M.; GKIOULIAVA, A. *et al.* The aberrant right subclavian artery: cadaveric study and literature review. *Surg. Radiol. Anat.*, v.39, p.1181-1182, 2017.
- OLIVEIRA, F.S.; MACHADO, M.R.F.; BORGES, E.M.; OLIVEIRA, D. Variação anatômica da artéria subclávia direita de cão - relato de caso. *Ars Vet.*, v.17, p.83-85, 2001.
- PAIVA, O.M. Dois casos de A. subclávia dextra como última colateral do arcus aorticus no cão. *Rev. Fac. Med. Vet. São Paulo*, v.3, p.203-223, 1948.
- SHOJAEI, B.; AKHTARDANESH, B.; KHEIRANDISH, R.; VOSOUGH, D. Megaesophagus caused by an aberrant right subclavian artery and the brachiocephalic trunk in a cat. *J. Vet. Res.*, v.15, p.46-52, 2011.
- TANAKA, N.M.; HOOGEVONINK, N.; TUCHOLSKI, A.P. *et al.* Megaesôfago em cães. *Rev. Acad. Ciên. Anim.*, v.8, p.271-279, 2010.
- TSUKISE, A.; SUGAWA, Y.; OKANO, M. Two anomalous cases of the right subclavian artery arising directly from the aortic arch in dogs. *Jap. J. Vet. Sci.*, v.34, p.11-15, 1972.
- VITUMS, A. Anomalous origin of the right subclavian and common carotid arteries in the dog. *Cornell Vet.*, v.52, p.5-15, 1962.
- YOON, H.Y.; JEONG, S.W. Surgical correction of an aberrant right subclavian artery in a dog. *Can. Vet. J.*, v.52, p.1115-1118, 2011.