



## Original Article

# Clinical and functional evaluation of patients submitted to reverse arthroplasty with minimum one year of follow-up<sup>☆</sup>



Flávio de Oliveira França<sup>a,b,\*</sup>, José Marcio Alves Freitas<sup>a,b,c</sup>, Pedro Couto Godinho<sup>a,b,c</sup>, Dermerson Martins Gonçalves<sup>a,b,c</sup>, Tertuliano Vieira<sup>a,b,c</sup>, Ulisses Silva Pereira<sup>a,b,c</sup>

<sup>a</sup> Hospital Ortopédico, Belo Horizonte, MG, Brazil

<sup>b</sup> Hospital Belvedere, Belo Horizonte, MG, Brazil

<sup>c</sup> Hospital Belo Horizonte, Belo Horizonte, MG, Brazil

## ARTICLE INFO

## Article history:

Received 24 May 2017

Accepted 24 October 2017

Available online 9 October 2018

## Keywords:

Replacement arthroplasty  
Recovery of physiological function  
Range of articular motion  
Treatment outcome

## ABSTRACT

**Objective:** To assess the clinical and functional results of patients submitted to reverse arthroplasty with a minimum follow-up of one year.

**Methods:** Twenty-two patients submitted to shoulder reverse arthroplasty by the Surgery and Shoulder Rehabilitation Group were retrospectively evaluated with pre and postoperative imaging analysis, analog pain scale, range of motion, and ASES functional score.

**Results:** Out of 19 (86.3%) patients with preoperative ASES classified as poor/bad, 11 (57.9%) progress to good/excellent after intervention, showing improvement of function, ranging from a mean preoperative ASES score of 22 ( $\pm$  18.8) to a postoperative mean of 64.8 ( $\pm$  27.7) ( $p=0.031$ ). Regarding the pain, there was an improvement in analog pain scale, presenting a preoperative mean of 7.64 (1–10) and a postoperative mean of 2.09 (0–7;  $p<0.001$ ). Regarding mobility, of 22 patients, 15 (68.2%) had preoperative pseudoparalysis and, of these, ten (66.7%) had an active anterior elevation greater than 90° after reverse arthroplasty. In turn, patients without pseudoparalysis had no significant gain in range of motion ( $p=0.002$ ). The authors observed active anterior elevation gain, with a preoperative mean of 76° (0–160°) and a postoperative mean of 111° (0–160°;  $p=0.002$ ).

**Conclusion:** Despite being a relatively new procedure in Brazil, reverse shoulder arthroplasty can be used effectively and safely in patients who were previously without treatment options such as rotator cuff arthropathy and revisions providing pain relief, improvement of function, and mobility of the upper limb.

© 2017 Sociedade Brasileira de Ortopedia e Traumatologia. Published by Elsevier Editora Ltda. This is an open access article under the CC BY-NC-ND license (<http://creativecommons.org/licenses/by-nc-nd/4.0/>).

<sup>☆</sup> Study conducted at Grupo de Cirurgia e Reabilitação de Ombro, Hospital Ortopédico de Belo Horizonte, Belo Horizonte, MG, Brazil.

\* Corresponding author.

E-mail: [flavio.franca29@gmail.com](mailto:flavio.franca29@gmail.com) (F.O. França).

<https://doi.org/10.1016/j.rboe.2017.10.012>

2255-4971/© 2017 Sociedade Brasileira de Ortopedia e Traumatologia. Published by Elsevier Editora Ltda. This is an open access article under the CC BY-NC-ND license (<http://creativecommons.org/licenses/by-nc-nd/4.0/>).

## Avaliação clínica e funcional de pacientes submetidos a artroplastia reversa com seguimento mínimo de um ano

### R E S U M O

#### Palavras-chave:

Artroplastia de substituição  
Recuperação de função  
fisiológica  
Amplitude de movimento  
articular  
Resultado do tratamento

**Objetivo:** Avaliar os resultados clínicos e funcionais de pacientes submetidos a artroplastia reversa com seguimento mínimo de um ano.

**Métodos:** Foram avaliados retrospectivamente 22 pacientes submetidos a artroplastia reversa de ombro pelo grupo de cirurgia e reabilitação de ombro da nossa instituição com análise pré e pós-operatória de exames de imagem, escala analógica da dor, amplitude de movimento e escala funcional ASES.

**Resultados:** Dos 19 (86,3%) pacientes que apresentavam ASES pré-operatória classificada como péssimo/ruim, 11 (57,9%) evoluíram para bom/excelente após a intervenção, apresentaram melhoria da função, saíram de uma escala ASES pré-operatória média de 22 ( $\pm 18,8$ ) para uma pós-operatória de 64,8 ( $\pm 27,7$ ;  $p = 0,031$ ). Quanto à dor, observou-se melhoria da escala analógica da dor, apresentaram média pré-operatória de 7,64 (1-10) e pós-operatória de 2,09 (0-7;  $p < 0,001$ ). Em relação à mobilidade, dos 22 pacientes, 15 (68,2%) apresentavam pseudoparalisia pré-operatória; desses, dez (66,7%) passaram a apresentar elevação anterior ativa superior a 90° após artroplastia reversa. Por outro lado, os pacientes sem pseudoparalisia não apresentaram ganho significativo de amplitude de movimento ( $p = 0,002$ ). Foi observado ganho de elevação anterior ativa, com média pré-operatória de 76° (0-160°) e pós-operatória de 111° (0-160°;  $p = 0,002$ ).

**Conclusão:** Apesar de ser um procedimento relativamente novo no Brasil, a artroplastia reversa de ombro pode ser usada com eficácia e segurança em pacientes que previamente apresentavam-se sem opções terapêuticas como artropatia do manguito rotador e revisões que proporcionam alívio de dor, melhoria da função e mobilidade do membro superior.

© 2017 Sociedade Brasileira de Ortopedia e Traumatologia. Publicado por Elsevier Editora Ltda. Este é um artigo Open Access sob uma licença CC BY-NC-ND (<http://creativecommons.org/licenses/by-nc-nd/4.0/>).

## Introduction

In the 1970s, a glenohumeral prosthesis was designed in which the anatomy was inverted (using a socket-shaped humeral component and ball-shaped glenoidal component), giving rise to reverse prostheses.<sup>1</sup> In the 1980s, Grammont et al.<sup>2</sup> perfected this system, medially and distally dislocating the glenohumeral rotation center. These principles allowed humeral elongation and deltoid muscle retensioning, increased their strength and function, and decreased mechanical torque at the interface between the prosthetic components and the bone surface, which reduced the risks of loosening.<sup>3</sup> Originally used for the treatment of rotator cuff arthropathy (RCA), it is now also indicated for inflammatory arthritis, fractures, fracture sequelae, post-tumor resection, revisions, and pseudoparalysis.<sup>4</sup>

Numerous factors influence the results of reverse arthroplasty, related to surgical indication, surgeon experience, surgical technique, patient and implant characteristics, and postoperative rehabilitation, among others.

Reverse arthroplasty is a relatively new procedure in Brazil, having been performed since 2007. Thus, its medium and long-term results in the Brazilian population need to be further researched. Currently, it is included in the types of prostheses regulated by the Brazilian Health Regulatory Agency and the Supplementary Health System. However, the Brazilian

Unified Health System does not include this implant in its list of procedures.

This study is aimed at assessing the clinical and functional results of patients who underwent reverse arthroplasty by the Surgery and Shoulder Rehabilitation Group of this institution, with a minimum follow-up of one year.

## Material and methods

This is a retrospective study of patients who underwent reverse shoulder arthroplasty, operated by six surgeons. The study was approved by the Research Ethics Committee, under No. 2.025.589. Patients who underwent reverse arthroplasty due to RCA with diagnostic confirmation by magnetic resonance imaging (MRI) to assess the extensive lesion of the rotator cuff tendons and X-rays to visualize glenohumeral arthrosis, as well as those patients with osteosynthesis failure in glenohumeral fractures. All patients presented trophic deltoid muscle with grade V strength and a minimum follow-up of one year. Patients with a follow-up of less than one year and/or permanent axillary nerve injury and/or arthrosis due to another etiology were excluded.

Patients were objectively and subjectively assessed. For objective functional evaluation, the American Shoulder and Elbow Surgery (ASES) protocol was translated and adapted to Brazilian Portuguese for clarity, understanding, and

acceptance by the patients.<sup>5</sup> For subjective measurement, the visual analog scale (VAS) was used; it ranges from zero to ten, in which zero represents the absence of pain and ten the maximum pain experienced by the patient.<sup>6</sup> Another subjective criterion used was patient satisfaction; at the end of the evaluation, patients answered whether or not they would undergo the procedure again.

In the present study patients with or without pseudoparalysis, characterized by an incapacity for active anterior elevation (AAE) above 90° were operated; those with passive anterior elevation limitation or neurological injury were not included.

After applying the inclusion and exclusion criteria, 22 patients were retrieved, who were invited to attend clinical and functional evaluations using the adapted ASES protocol, measuring the range of motion (ROM) with a manual goniometer, satisfaction, and VAS. During the evaluation, radiographs were requested on neutral anteroposterior, scapular lateral and axial lateral views, aimed at determining implant placement, component fixation, and incidence of scapular notching according to the classification of Sirveaux et al.<sup>7</sup>

As the study includes a limited number of patients, for the statistical analysis they were grouped according to the ASES score. Patients whose score ranged from zero to 40 points were classified as very poor/poor (between zero to 20, very poor; 21 to 40, poor), 41 to 60 as fair, and 61 to 100 as good/excellent (61 to 80, good; 81 to 100, excellent). The original criterion of progressive improvement of the function was respected, according to the score; 0 represented the worst result and 100 the best possible function.<sup>8</sup>

In all patients, a deltopectoral approach was used, as well as the Equinox<sup>®</sup> prosthesis (Exactech Inc, Gainesville, FL), lateralized, with a maximum retroversion of 20°. In 16 cases, cemented prostheses were used; two cases required an associated cementation of the glenoidal component, and in six cases, uncemented prostheses were used. The fixation of the glenosphere baseplate was made with at least four screws and a maximum of six screws.

The stability of the prosthetic joint was evaluated intraoperatively through subjective criteria such as tension at palpation of the deltoid muscle and conjoint tendon, and the piston test, translated by a maximum decoaptation of 2 mm between the humeral polyethylene and glenosphere, when upper limb axial traction is made; furthermore, the limb was

mobilized in all planes after the components were placed. Postoperative rehabilitation was initiated after six weeks of immobilization with a Velpeau shoulder immobilizer.

In the present study, problems and complications were assessed intra and postoperatively based on the concept described by Zumstein et al.,<sup>9</sup> in which problems are defined as intra or postoperative events that usually do not affect the final outcome of the procedure and complications are defined as events that affect the final result.

## Statistical methodology

In all statistical tests, a 5% significance level was adopted. Thus, statistically significant associations were those whose *p*-value was less than 0.05. The variables were tested for their type of distribution by the Kolmogorov-Smirnov test; for the analyses, the parametric test class was used, since all continuous variables presented a normal distribution.

For the comparison of the ASES and AAE categories, pre and postoperatively, the McNemar test was used. In turn, the VAS was compared pre and postoperatively using the paired Student's *t*-test.

The closer the value is to 1, the stronger the association.

The analyses were performed using the statistical software SPSS (Statistical Package for Social Sciences) version 20.0 (2012, Chicago, IL, USA).

## Results

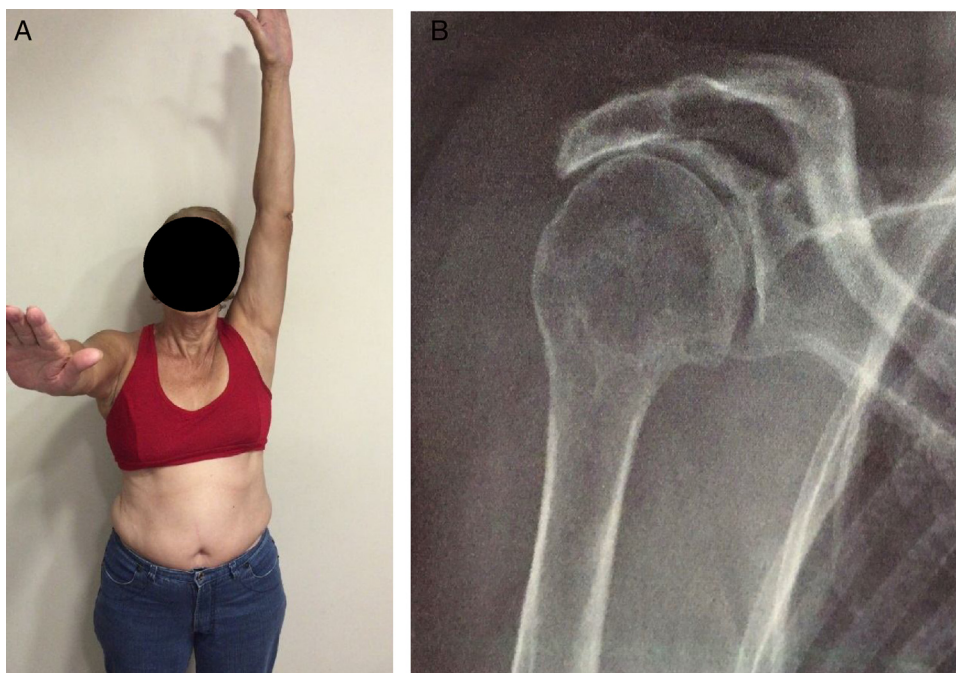From October/2011 to November/2016, 22 patients (81.8%) underwent reverse arthroplasty due to RCA, 18 (81.8%) women and four men (18.2%), with a mean age of 75.5 years (65–86), and four patients underwent reverse arthroplasty (18.2%) due to proximal humeral fracture revision, with a minimum follow-up of 12 months (13–63).

The functional analysis of the pre and postoperative ASES rating score showed that of the 22 patients (Table 1), 19 (86.3%) had preoperative ASES classified as very poor/poor, and 11 (57.9%) of these evolved to a good/excellent score in the postoperative period (Fig. 1A and B, Fig. 2A and B). Of the three (13.7%) previously classified as fair, 100% evolved to good/excellent (*p* = 0.031; Table 1).

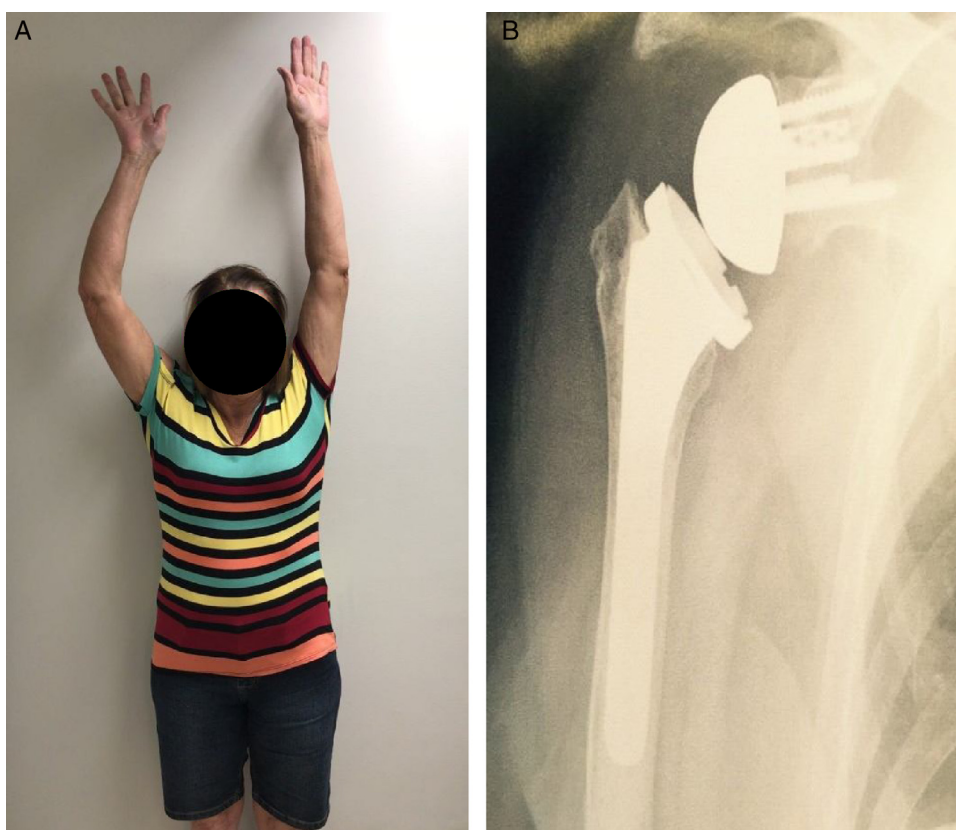
**Table 1 – Functional pre and postoperative comparison, using the ASES rating score, of patients who underwent reverse arthroplasty.**

		Postoperative ASES				Total
		Very poor/poor	Fair	Good/excellent		
ASES	Very poor/poor	19	3	5	11	19
		86.3%	15.8%	26.3%	57.9%	100.0%
Preoperative	Fair	3	0	0	3	3
		13.7%	0.0%	0.0%	100.0%	100.0%
Total		22	3	5	14	22
		100%	13.7%	22.7%	63.6%	100.0%

*p*-Value = 0.031.



**Fig. 1 – (A) A patient with rotator cuff arthropathy and pseudoparalysis of the right upper limb; (B) X-ray demonstrating rotator cuff arthropathy, classified as Hamada II.**



**Fig. 2 – (A) The patient of Fig. 1A, operated for reverse arthroplasty on the right shoulder and gain of active elevation; (B) X-ray of the patient of A, showing the reverse prosthesis.**

**Table 2 – Functional pre and postoperative comparison, using the ASES rating score, solely of patients who underwent reverse arthroplasty due to rotator cuff arthropathy.**

		Postoperative ASES			
			Very poor/poor	Fair/good/excellent	Total
ASES	Very poor/poor	16	2	14	16
		88.9%	12.5%	87.5%	100.0%
Preoperative	Fair	2	0	2	2
		11.1%	0.0%	100.0%	100.0%
Total		18	2	16	18
		100%	11.1%	88.9%	100.0%

p-Value <0.001.

**Table 3 – Comparison between pre and postoperative VAS.**

	Minimum	Maximum	Mean	Total (N)
Preoperative VAS	1	10	7.64	22
Postoperative VAS	0	7	2.09	22

p-Value <0.001.

The isolated evaluation of the 18 patients treated due to RCA (Table 2), 16 (88.9%) presented very poor/poor preoperative ASES score and two (11.1%), fair. Among these 16, 14 (87.5%) evolved to fair/good/excellent. The two (11.1%) previously classified as fair evolved to good/excellent ( $p < 0.001$ ; Table 2).

The mean ASES preoperative score was 21.5 points ( $\pm 18.8$ ) and the mean postoperative score was 64.6 points ( $\pm 27.7$ ). The mean difference between the scores was 43.1 points (95% CI = -51.5; -34.7); considered statistically significant ( $p < 0.001$ ).

Regarding the VAS, the patients presented improvement of the pain complaint, with a mean preoperative VAS of 7.64 and a postoperative score of 2.09 ( $p < 0.001$ ; Table 3).

When assessing AAE (Table 4), ten (66.7%) of the 15 (68.5%) patients who presented AAE up to 90° (pseudoparalysis) evolved to 91° or more after the procedure and were no longer characterized as pseudoparalytic. No significant gains were observed in the group of patients who presented preoperative AAE greater than 91° ( $p = 0.002$ ; Table 4).

In this study, 18.2% of the patients presented postoperative problems. Of these, one patient (4.5%) presented postoperative hematoma and three (14.3%) patients presented scapular

notching on postoperative radiographic evaluation; no other noteworthy X-ray changes were observed in the other patients.

As for complications, one patient (4.5%) developed postoperative late infection and consequent humeral component release and underwent resection arthroplasty.

When asked if they would undergo the procedure again, 100% of the patients responded affirmatively, demonstrating satisfaction with the results of the reverse arthroplasty.

## Discussion

By dislocating the center of rotation of the glenohumeral joint medially and distally, the action and strength of the deltoid muscle increases, and the mechanical torque on the prosthetic components is reduced, which reduces the risks of loosening.

The design of the prosthesis may also influence the results. All the current designs have a medialized center of rotation; some are more medialized and others, more lateralized. This variation may lead to clinical and functional changes.<sup>10-12</sup>

In the present study, a lateralized prosthesis was used (Equinoxe®, Exactech Inc.; Gainesville, FL), and the patients presented mean postoperative LR of 44.1° (range: 15° to 60°); the literature presents variable LR results.

Mulieri et al.<sup>13</sup> observed a LR variation of 24°: preoperatively, it was 27° (-20° to 70°) and postoperatively, 51° (-30° to 90°;  $p = 0.001$ ). Lädemann et al.<sup>14</sup> did not observe a significant difference in LR; they observed a variation of 16° to 18° in both the pre and postoperative periods ( $p = 0.10$ ). In turn, Muh et al.<sup>15</sup> showed an LR improvement of approximately

**Table 4 – Comparison between pre and postoperative AAE.**

		Postoperative AAE			
			Up to 90°	91° or more	Total
AAE	Up to 90°	15	5	10	15
		68.2%	33.3%	66.7%	100.0%
Preoperative	91° or more	7	0	7	7
		31.8%	0.0%	100.0%	100.0%
Total		22	5	17	22
		100%	22.7%	77.3%	100.0%

p-Value <0.002.

10°, a preoperative mean of 10° (-20 to 70°) to 19.6° (-10 to 70°) in the postoperative period ( $p < 0.05$ ). Amaral et al.<sup>16</sup> failed to observe alterations in pre and postoperative LR.<sup>16</sup> This variability is justified because LR depends on several factors, such as the integrity of the lateral rotators (infraspinatus and teres minor tendons), the number of fibers mobilized from the posterior portion of the deltoid muscle, and the type of prosthesis used.<sup>11,12</sup> In an attempt to obtain clinical and functional LR improvements, new surgical techniques have been used; transfer of the latissimus dorsi is one of the most common.<sup>17</sup>

Regarding the functional evaluation through the ASES rating score, the present patients improved from a preoperative mean of 22 ( $\pm 18.8$ ) to a postoperative mean of 64.8 ( $\pm 27.7$ ), values that are in agreement with the literature. Ferreira Neto et al.<sup>18</sup> reported a progression on the ASES rating score from 23.1 ( $\pm 15$ ) to 82.7 ( $\pm 15$ ;  $p < 0.001$ ). Muh et al.<sup>15</sup> observed a preoperative mean of 40 ( $\pm 16.71$ ), which evolved to 72.4 ( $\pm 12.75$ ;  $p < 0.05$ ). Sabesan et al.<sup>19</sup> demonstrated a mean variation of 45.6 points, with a mean preoperative score of 33.0 and a mean postoperative score of 78.6 ( $p < 0.001$ ). Cuff et al.<sup>20</sup> observed a variation of 43 points, with a mean of 32 (0-65) preoperatively and 75 (7-100) postoperatively ( $p < 0.001$ ).

When analyzing the pre and postoperative ASES rating score of the patients who underwent surgery due to RCA (Table 2), a statistically significant improvement was observed in the function ( $p < 0.001$ ); it was higher than the group in Table 1 ( $p < 0.031$ ), which encompasses patients who underwent surgery due to RCA and fracture revision. This fact can be justified by the inclusion of patients who underwent revision surgeries after previous implant failure, as it is a new surgical act. This reinforces the literature data in which the best reverse arthroplasty results are obtained in patients operated due to RCA.<sup>6,7,21</sup>

Regarding pain, in the present study, the mean preoperative VAS was 7.64 (1-10) and the mean postoperative score was 2.09 (0-7), a statistically significant difference ( $p < 0.001$ ) that is in agreement with the literature.

Klein et al.<sup>22</sup> observed an improvement in VAS from 6.1 to 1.5 ( $p < 0.0001$ ). Similarly, Lädemann et al.<sup>14</sup> observed an improvement from 6.7 to 1.0 ( $p < 0.001$ ); Ortmaier et al.,<sup>23</sup> from 7.1 (5-9) to 1.0 (0-2;  $p < 0.001$ ); and Ferreira Neto et al.,<sup>18</sup> from 7.9 to 1.0 ( $p < 0.002$ ).

The highest incidence of success and lowest rate of complications are observed in patients with RCA and pseudoparalysis.<sup>16,19</sup> In patients without pseudoparalysis, the improvement in ROM was not significant.<sup>24</sup> These data were in agreement with those of the present series.

Of the 15 patients (68.2%) who had preoperative pseudoparalysis, 10 (66.7%) had AAE greater than 90° after reverse arthroplasty. Furthermore, the group of patients without preoperative pseudoparalysis did not present significant ROM gain ( $p = 0.002$ ).

The patients in this study presented a gain of AAE, with a preoperative mean of 76° (0-160°) and postoperative of 111° (0-160°), which is in agreement with the literature ( $p = 0.002$ ).

Cuff et al.<sup>24</sup> observed a mean AAE gain of 54° (64-118°), 63.5° (4.2-152.1°) preoperatively and 118° postoperatively (4.5-180°;

$p < 0.0001$ ). Frankle et al.<sup>25</sup> reported an improvement in AAE of 50.1° with a preoperative mean of 55° (10-120°) and a postoperative mean of 105.1° (30-180°;  $p < 0.0001$ ).

The incidence of scapular notching in the present sample was 14.3%, similar to that published in the literature based on the prosthesis model used (Equinox<sup>®</sup>, Exactech Inc.; Gainesville, FL) and with a lower percentage than the Brazilian studies published on this problem.<sup>16,18,26</sup> As described by Wright, this is the most frequent problem after reverse arthroplasty.<sup>27</sup>

The appearance of scapular notching is noticeable during the first year postoperatively, but it is not clear whether it progresses. The impact between the humeral component and the scapular neck during arm adduction occurs due to the medialization of the center of rotation of the reverse prosthesis. The clinical significance of the scapular notching is controversial; although some studies suggest a correlation with glenoid component loosening, the most widely published literature on this topic failed to present clinical evidence of this hypothesis,<sup>28</sup> as did the present study.

In the present sample, only one patient (4.5%) presented late infection; it was the sole case of complication, below the mean value found in the Brazilian<sup>16,18</sup> and international literature,<sup>8,17</sup> which ranges from 15 to 68% for complications, but within the mean values for infection, which range from 1 to 15%. This fact may have been due to the careful indication for a reverse prosthesis in the present sample group and the short follow-up period, variables that lead to lower rates of complications, as described by Walch et al.<sup>29</sup>

Despite the problems and complications, 100% of the present patients were satisfied and declared that they would undergo a reverse arthroplasty again, a result close to that described by Fávoro et al.,<sup>26</sup> in which only one patient declared that he would not undergo the procedure again.

## Conclusion

This study demonstrates that, despite being a relatively new procedure in Brazil, reverse shoulder arthroplasty can be effectively and safely used in cases that previously presented no treatment options, such as RCA and revisions, providing pain relief, improvement of function, and mobility of the upper limb.

## Conflicts of interest

The authors declare no conflicts of interest.

## REFERENCES

1. Flatow EL, Harrison AK. A history of reverse total shoulder arthroplasty. *Clin Orthop Relat Res.* 2011;469(9):2432-9.
2. Grammont P, Trouilloud P, Laffay J, Deries X. Concept study and realization of a new total shoulder prosthesis. *Rheumatologie.* 1987;39:407-18.
3. Zumstein MA, Pinedo M, Old J, Boileau P. Problems, complications, reoperations, and revisions in reverse total

- shoulder arthroplasty: a systematic review. *J Shoulder Elbow Surg.* 2011;20(1):146-57.
4. Mahmood A, Malal JJ, Waseem M. Reverse shoulder arthroplasty – a literature review. *Open Orthop J.* 2013;7 Suppl 3 M13:366-72.
  5. Knautl I, Moser II ADL, Melo III AS, Richards RR. Tradução e adaptação cultural à língua portuguesa do American Shoulder and Elbow Surgeons Standardized Shoulder Assessment Form (ASES) para avaliação da função do ombro. *Rev Bras Reumatol.* 2010;50(2):176-89.
  6. Huskisson EC. Measurement of pain. *Lancet.* 1974;2(7889):1127e31.
  7. Sirveaux F, Favard L, Oudet D, Huguet D, Walsh G, Mole D. Grammont inverted total shoulder arthroplasty in the treatment of glenohumeral osteoarthritis with massive rupture of the cuff: results of a multicentre study of 80 shoulders. *J Bone Joint Surg Br.* 2004;86(3):388-95.
  8. Kirkley A, Griffin S, Dainty K. Scoring systems for the functional assessment of the shoulder. *Arthroscopy.* 2003;19(10):1109-20.
  9. Zumstein MA, Pinedo M, Old J, Boileau P. Problems, complications, reoperations, and revisions in reverse total shoulder arthroplasty: a systematic review. *J Shoulder Elbow Surg.* 2011;20(1):146-215.
  10. Samitier G, Alentorn-Geli E, Torrens C, Wright TW. Reverse shoulder arthroplasty. Part 1: Systematic review of clinical and functional outcomes. *Int J Shoulder Surg.* 2015;9(1): 24-31.
  11. Boileau P, Watkinson DJ, Hatzidakis AM, Balg F. Grammont reverse prosthesis: design, rationale, and biomechanics. *J Shoulder Elbow Surg.* 2005;14 1 Suppl S:61S-147S.
  12. Grammont PM, Baulot E. Delta shoulder prosthesis for rotator cuff rupture. *Orthopedics.* 1993;16(1):65-8.
  13. Mulieri P, Dunning P, Klein S, Pupello D, Frankle M. Reverse shoulder arthroplasty for the treatment of irreparable rotator cuff tear without glenohumeral arthritis. *J Bone Joint Surg Am.* 2010;92(15):2544-56.
  14. Lädermann A, Lo EY, Schwitzguébel AJ, Yates E. Subscapularis and deltoid preserving anterior approach for reverse shoulder arthroplasty. *Orthop Traumatol Surg Res.* 2016;102(7):905-8.
  15. Muh SJ, Streit JJ, Wanner JP, Lenarz CJ, Shishani Y, Rowland DY, et al. Early follow-up of reverse total shoulder arthroplasty in patients sixty years of age or younger. *J Bone Joint Surg Am.* 2013;95(20):1877-83.
  16. Amaral MV, Faria JL, Siqueira G, Cohen M, Brandão B, Moraes R, et al. Artroplastia reversa do ombro no tratamento da artropatia do manguito rotador. *Rev Bras Ortop.* 2014;49(3):279-85.
  17. Ortmaier R, Hitzl W, Matis N, Mattiassich G, Hochreiter J, Resch H. Reverse shoulder arthroplasty combined with latissimus dorsi transfer. A systemic review. *Orthop Traumatol Surg Res.* 2017, pii: S1877-05681730121-4.
  18. Ferreira Neto AA, Malavolta EA, Assunção JH, Trindade EM, Gracitelli ME. Artroplastia reversa do ombro: Avaliação dos resultados clínicos e da qualidade de vida. *Rev Bras Ortop.* 2017;52(3):298-302.
  19. Sabesan VJ, Lombardo DJ, Khan J, Wiater JM. Assessment of the optimal shoulder outcome score for reverse shoulder arthroplasty. *J Shoulder Elbow Surg.* 2015;24(10):1653-9.
  20. Cuff D, Clark R, Pupello D, Frankle M. Reverse shoulder arthroplasty for the treatment of rotator cuff deficiency: a concise follow-up, at a minimum of five years, of a previous report. *J Bone Joint Surg Am.* 2012;94(21):1996-2000.
  21. Wall B, Nové-Josserand L, O'Connor DP, Edwards TB, Walch G. Reverse total shoulder arthroplasty: a review of results according to etiology. *J Bone Joint Surg Am.* 2007;89(7):1476-85.
  22. Klein SM, Dunning P, Mulieri P, Pupello D, Downes K, Frankle MA. Effects of acquired glenoid bone defects on surgical technique and clinical outcomes in reverse shoulder arthroplasty. *J Bone Joint Surg Am.* 2010;92(5):1144-54.
  23. Ortmaier R, Plachel F, Lederer S, Hitzl W, Auffarth A, Matis N, et al. Reverse shoulder arthroplasty after failed pectoralis major tendon transfer with a minimum follow-up of 5 years. A case series. *J Orthop Sci.* 2016;21(5):591-5.
  24. Cuff D, Pupello D, Virani N, Levy J, Frankle M. Reverse shoulder arthroplasty for the treatment of rotator cuff deficiency. *J Bone Joint Surg Am.* 2008;90(6):1244-51.
  25. Frankle M, Siegal S, Pupello D, Saleem A, Mighell M, Vasey M. The Reverse Shoulder Prosthesis for glenohumeral arthritis associated with severe rotator cuff deficiency. A minimum two-year follow-up study of sixty. *J Bone Joint Surg Am.* 2005;87(8):1697-705.
  26. Fávoro RC, Abdulahad M, Mussi Filho S, Valério R, Superti MJ. Artropatia de manguito: o que esperar do resultado funcional da artroplastia reversa. *Rev Bras Ortop.* 2015;50(5):523-9.
  27. Wright TW, Roche CP, Wright L, Flurin PH, Crosby LA, Zuckerman JD. Reverse shoulder arthroplasty augments for glenoid wear comparison of posterior augments to superior augments. *Bull Hosp Jt Dis (2013).* 2015;73 Suppl 1:S124-8.
  28. Lévine C, Boileau P, Favard L, Garaud P, Molé D, Sirveaux F, et al. Scapular notching in reverse shoulder arthroplasty. *J Shoulder Elbow Surg.* 2008;17(6):925-35.
  29. Walch G, Bacle G, Lädermann A, Nové-Josserand I, Smithers CJ. Do the indications, results, and complications of reverse shoulder arthroplasty change with surgeon's experience? *J Shoulder Elbow Surg.* 2012;21(11):1470-7.