

TRANSANAL DESARTERIALIZATION GUIDED BY DOPPLER ASSOCIATED TO ANORECTAL REPAIR IN HEMORRHOIDS: THD TECHNIC

Desarterialização transanal guiada por doppler associada ao reparo anorretal na doença hemorroidária: a técnica do THD

Carlos Walter **SOBRADO-JUNIOR**, José Américo Bacchi **HORA**

From Discipline of Coloproctology, Faculty of Medicine, University of São Paulo, SP, Brazil.

ABSTRACT - Introduction - Surgical treatment for hemorrhoids should be indicated individually and is based on the predominant symptom (bleeding or prolapse), severity of disease and the presence or absence of external component (plicoma). Surgeons must choose among varied techniques the one suitable for each case. **Technic** - The THD procedure consists of Doppler guided high ligation, selective to up six submucosal arterial branches that supply the hemorrhoids, leading to its desarterialization associated with prolapse repair (anorectal repair or lifting). It uses special equipment and kit. **Conclusion** - THD technique has shown good initial results. Because surgical technique respects the anatomy, it acts directly on the pathophysiology of the disease and corrects its principal consequences; it looks quite promising. Its initial application may be in patients with hemorrhoids grade II, which have surgical indication, grades III and IV, the latter being associated with resection of plicomas.

HEADINGS - Surgery. Hemorrhoids. Technique

Correspondence:

Carlos Walter Sobrado Junior,
e-mail: cwsobrado@hotmail.com

Financial source: none
Conflicts of interest: none

Received for publication: 25/06/2012
Accepted for publication: 13/08/2012

DESCRITORES - Cirurgia. Hemorroidas. Técnica.

RESUMO – Introdução – O tratamento cirúrgico para hemorroidas deve ter indicação individual e baseia-se no sintoma predominante (sangramento ou prolapso), na gravidade da doença e na presença ou ausência de componente externo (plicoma). Cabe ao cirurgião conhecer as mais variadas técnicas para que possa encontrar o tratamento mais adequado caso a caso. **Técnica** – O procedimento THD consiste na ligadura alta seletiva e guiada por Doppler de até seis ramos arteriais submucosos que irrigam as hemorroidas, levando à sua desarterialização, associada à correção do prolapso (reparo anorretal ou lifting). Utiliza equipamento e kit especiais. **Conclusão** - A técnica do THD tem mostrado bons resultados iniciais. Por ser técnica cirúrgica em que se respeita a anatomia, ela age diretamente sobre a fisiopatologia da afecção e corrige suas principais consequências, ela parece bastante promissora. Sua aplicação inicial pode ser nos pacientes com doença hemorroidária de II grau, que tenham indicação de tratamento cirúrgico, e de III e IV graus, nestes últimos, podendo ser associada à ressecção de plicomas.

INTRODUCTION

The search for the optimal surgical treatment of hemorrhoidal disease dates back to historical times, currently being necessary in only 10-20% of symptomatic patients first³. In the last century, many techniques have been developed, but few have signed up such as those proposed by Milligan-Morgan²¹, Parks²⁴ and Ferguson⁸, which can still be considered the gold standard in surgical treatment of this disease. In order to simplify the therapeutic process, were developed outpatient treatment modalities, such as sclerotherapy¹², variceal ligation², cryotherapy¹⁹ and photocoagulation²³. Arriving to the era of minimally invasive surgery, were created methods of mechanical anopexia²⁰ and, more recently, Doppler-guided

hemorrhoidal desarterialization, or THD (Transanal hemorrhoidal dearterialization) object of this text. Therapy must be instituted individually, based on predominant symptom (bleeding or prolapse), severity of disease and the presence or absence of external component (pilonidal). Surgeons face themselves with varied techniques, so they can find the most suitable treatment in each case.

Anatomophysiological bases of the technique

The length of the anal canal varies from 2.5 to 4 cm above the anal verge. Inferiorly it is limited to the perianal skin, highly innervated and sensitive area. Has its epithelial lining divided by dentate line in two areas: the cranial, less sensitive to pain with visceral innervation and distal, more sensitive. The blood supply to the rectum and the anal canal is supplied by three arteries: the superior rectal artery, a branch of the inferior mesenteric artery, middle rectal artery, a branch of the internal iliac artery, and inferior rectal artery, a branch of the internal pudendal artery. The internal hemorrhoidal plexus, also called the corpus cavernosum of the rectum, appears histologically as a cavernous venous network with arteriovenous shunts, surrounded by connective tissue, within or below the rectal mucosa. This plexus receives its blood supply exclusively from the terminal branches of the superior rectal artery.

According to Aigner¹, in healthy individuals, the mean diameter of the terminal branches of the upper rectal artery is 0.92 mm with average flow of 11.9 cm / sec and in patients suffering from hemorrhoidal diseases, both the diameter, as the flow increases, being the mean diameter of 1.87 mm with average flow of 33.9 cm / sec. Recent studies²⁸, with endoanal ultrasound Doppler (360° - rotating Itrasonographic endoprobe) demonstrated that in the circumference of the wall of the distal rectum, 6 cm above the anal verge, is generally identified six arterial branches located in positions 1, 3, 5, 7, 9 and 11 hours in individuals with or without hemorrhoids. In the same study showed that in patients with hemorrhoidal disease, there is increased arterial blood flow velocity and decrease in venous resistance.

In theory, arterial blood hyperflow going to the hemorrhoids in higher speed leads to congestion and venous injury, which causes stasis, edema and prolapsed nipples. Hypertension by overflow, also contributes to the degeneration of the connective tissue. The increased force during defecation further impairs venous drainage. All this stress on connective tissue leads, with time, to degeneration and the onset of symptoms of prolapse, bleeding, discomfort, burning, mucous secretion, pain and itching.

Historical evolution

Treatment for Doppler-guided hemorrhoidal desarterialization for hemorrhoidal disease - HAL (only desarterialization) was first described in Japan in 1995 by Morinaga et al.²², who reported good results in 116 patients evaluated for pain, bleeding and prolapse after a month of monitoring. A northamerican group in 2001, after operating on 60 patients, considered it an option to hemorrhoidectomy, in most cases³². Since then, both the technique HAL and anorectal repair equipment have been improved. Data collected from case series, increasingly bigger, and with longer follow-up have been published, mainly in Europe⁶. Currently, the technique THD (desarterialization associated to hemorrhoidopexia) have been indicated for refractory hemorrhoidal disease 2nd degree, 3rd degree and selected cases of 4th degree.

TECHNIC

The procedure consists of selective high ligation, Doppler guided, up to six submucosal arterial branches that supply the hemorrhoids, leading to its desarterialization associated with prolapse repair (anorectal repair or lifting).

Was developed a special anoscope coupled on the side of its tip to a Doppler sensor, which allows to listen to the submucosa arterial pulse sound, locating the artery. After soft digital examination with anesthetic gel or lubricant, anoscope is introduced. By means of the sound, the arterial branches are identified with great precision and its ligation is made with absorbable 00 (polyglycolic acid) to approximately 6 cm above the dentate line, through a side window on the instrument. This initial desarterialization already reduces the engorgement of the hemorrhoidal tissue, facilitating its reduction, suspension and fixation (Figure 1).

Later, there will be a simple continuous running suture with the same thread in craniocaudal direction to place about 1.0 cm above the dentate line, which tied after the starting point, lead to pexia of mucosal tissue prolapsed, which return to their anatomical position. At this stage, it must avoided deep sutures involving the anal sphincter, because hinder lifting of prolapsed tissue, and also increase postoperative pain. This procedure should be conducted in six arterial branches located in positions 1, 3, 5, 7, 9 and 11 hours. Finally, hemostasis is reviewed and a dressing is positioned with the introduction of a hemostat, as part of kit THD (Figures 2 and 3).

So, the interruption of blood flow is added to the mucosal pexia and hemorrhoids, directing

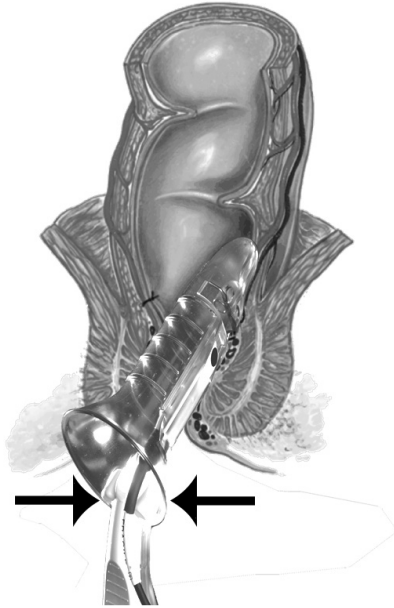
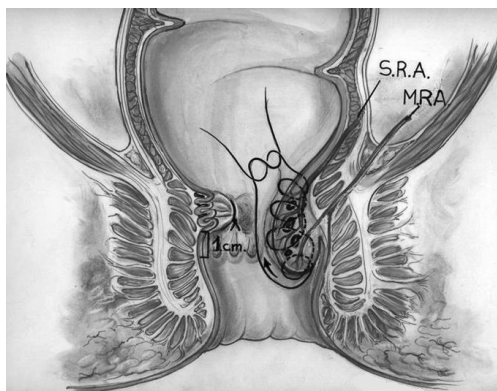


FIGURE 1 - Location of the arterial pulse by Doppler to perform the initial suture. (Source: Carlo Ratto)



SRA = superior rectal artery. MRA = middle rectal artery

FIGURE 2 - Representation of the end of the running suture for anorectal repair (lifting or hemorrhoidopexia). (Source: Carlo Ratto)

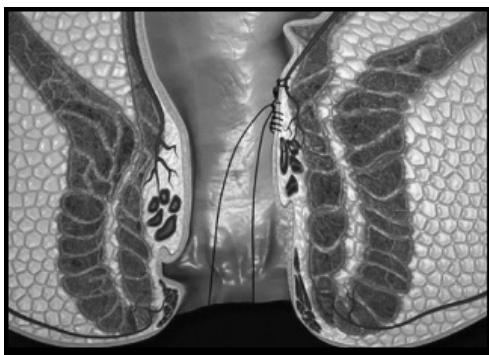

FIGURE 3 - Schematic view of the final aspect of the anorectal repair (hemorrhoidopexia) and hemorrhoidal desarterialization. (Source: <http://www.thdlab.com.br/tratamentos/1/curar-hemorroidas.html>)

treatment to the resolution of the two main symptoms of hemorrhoids: bleeding and prolapse. Because there is no tissue resection and the entire procedure take place above the dentate line, is expected to reduce postoperative pain, compared to hemorrhoidectomy procedures. Antibiotics are used as prophylaxis routine (Figures 4 and 5).

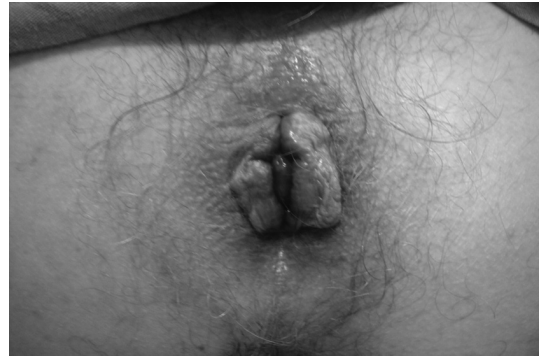

FIGURE 4 - Preoperative appearance

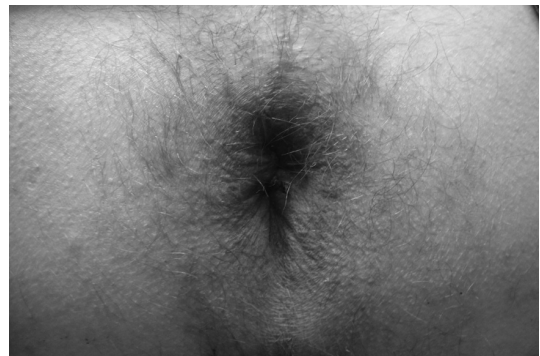


FIGURE 5 - Postoperative appearance after the THD technic

Commercial fibers (plantago ovata, psillium, methylcellulose) are prescribed routinely and, as analgesics, dipyron and antiinflammatories (ketoprofen). All patients were examined weekly for four weeks, when they are questioned about pain, stool frequency, stool appearance, bleeding, satisfaction with the procedure and return to work.

DISCUSSION

In 2009, in a review of 1996 cases published in the literature, it was concluded that the treatment is safe for hemorrhoids grades II and III, and that further studies about its efficacy are necessary in more advanced cases and in longer follow-up. In 2011, a French group, in an uncontrolled study with 100 patients with grade IV hemorrhoids, obtained good results with median follow-up of 34 months 16. In the same year, Ratto et al. published the results of the procedure in 35 consecutive patients

with more advanced hemorrhoidal disease, obtaining similar data²⁹, which suggests that the technique has potential use for the majority of cases with surgical indication^{28,29,30,33}. Since then, initial experiments in several countries^{5,13,25,27,34}, have been published, with good results, the procedure being isolated or associated with other techniques. Brazil has gaining adherents in recent years, measured by conferences, presentations and publications on initial experience^{16,31}; it showed good results and low complication rates at two years follow-up.

Were found six publications of comparative studies using hemorrhoidal desarterialization. Four of them were comparing it to the mechanic anopexia, showing similar results in the medium term, with one of them observing a lower incidence of early complications and faster return to work for groups of desarterialization¹⁰, and other two, slight reduction of pain in the early postoperative^{9,17}. A Chinese desarterialization group of patients has been very favorable for the early complications and postoperatively pain²⁶. In comparative paper with closed hemorrhoidectomy and TDH technique, showed less pain and earlier recovery, with similar results in a year⁴. Indian study found no differences between simple desarterialization and Doppler-guided ligation of hemorrhoids within one year of follow-up¹⁴. Egyptian study already showed that hemorrhoidectomy is superior to PPH and to desarterialization in advanced cases, where there anal plicomas, and is similar in the other aspects¹⁵.

CONCLUSIONS

The THD technique has shown good initial results. It respects the anatomy, acts directly on the pathophysiology of the disease and corrects its principal consequences. So, THD seems quite promising. Its initial application may be in patients with second-degree hemorrhoids, with surgical indication, and also in grades III and IV, the latter associated with plicomas resection

REFERENCES

1. Aigner F, Bodner G, Conrad F, Mbaka G, Kreczy A, Fritsch H. The superior rectal artery and its branching pattern with regard to its clinical influence on ligation techniques for internal hemorrhoids. *Am J Surg*. 2004 Jan;187(1):102-8.
2. Barron J. Office ligation of internal hemorrhoids. *Am J Surg*. 1963 Apr;105:563-70.
3. Bleday R, Pena JP, Rothenberger DA, Goldberg SM, Buls JG. Symptomatic hemorrhoids: current incidence and complications of operative therapy. *Dis Colon Rectum*. 1992 May;35(5):477-81.
4. Bursics A, Morvay K, Kupcsulik P, Flautner L. Comparison of early and 1-year follow-up results of conventional hemorrhoidectomy and hemorrhoid artery ligation: a randomized study. *Int J Colorectal Dis*. 2004 Mar;19(2):176-80.
5. Charúa Guindic L, Fonseca Muñoz E, García Pérez NJ, Osorio Hernández RM, Navarrete Cruces T, Avendaño Espinosa O, Guerra Melgar LR. Hemorrhoidal desarterialization guided by Doppler. A surgical alternative in hemorrhoidal disease management. *Rev Gastroenterol Mex*. 2004 Apr-Jun;69(2):83-7.
6. Faucheron JL, Gangner Y. Doppler-guided hemorrhoidal artery ligation for the treatment of symptomatic hemorrhoids: early and three-year follow-up results in 100 consecutive patients. *Dis Colon Rectum*. 2008 Jun;51(6):945-9.
7. Faucheron JL, Poncet G, Voirin D, Badic B, Gangner Y. Doppler-guided hemorrhoidal artery ligation and rectoanal repair (HAL-RAR) for the treatment of grade IV hemorrhoids: long-term results in 100 consecutive patients. *Dis Colon Rectum*. 2011 Feb;54(2):226-31.
8. Ferguson JA, Mazier WP, Ganchrow MI, Friend WG. The closed technique of hemorrhoidectomy. *Surgery*. 1971 Sep;70(3):480-4.
9. Festen S, van Hoogstraten MJ, van Geloven AA, Gerhards MF. Treatment of grade III and IV haemorrhoidal disease with PPH or THD. A randomized trial on postoperative complications and short-term results. *Int J Colorectal Dis*. 2009 Dec;24(12):1401-5.
10. Giordano P, Nastro P, Davies A, Gravante G. Prospective evaluation of stapled haemorrhoidopexy versus transanal haemorrhoidal dearterialisation for stage II and III haemorrhoids: three-year outcomes. *Tech Coloproctol*. 2011 Mar;15(1):67-73.
11. Giordano P, Overton J, Madeddu F, Zaman S, Gravante G. Transanal hemorrhoidal dearterialization: a systematic review. *Dis Colon Rectum*. 2009 Sep;52(9):1665-71.
12. Graham-Stewart CW. Injection treatment of haemorrhoids. *Br Med J*. 1962 Jan 27;1(5273):213-6.
13. Greenberg R, Karin E, Avital S, Skornick Y, Werbin N. First 100 cases with Doppler-guided hemorrhoidal artery ligation. *Dis Colon Rectum*. 2006 Apr;49(4):485-9.
14. Gupta PJ, Kalaskar S, Taori S, Heda PS. Doppler-guided hemorrhoidal artery ligation does not offer any advantage over suture ligation of grade 3 symptomatic hemorrhoids. *Tech Coloproctol*. 2011 Dec;15(4):439-44.
15. Hafagy W, El Nakeeb A, Fouda E, Omar W, Elhak NG, Farid M, Elshobaky M. Conventional haemorrhoidectomy, stapled haemorrhoidectomy, Doppler guided haemorrhoidectomy artery ligation; post-operative pain and anorectal manometric assessment. *Hepatogastroenterology*. 2009 Jul-Aug;56(93):1010-5.
16. Hora, JAB; Klajner, S; Kruglensky, D; Sobrado Jr, CW. Tratamento Cirúrgico da Doença Hemorroidária por Desarterialização Transanal Guiada por Doppler associada ao Reparo Anorretal (A Técnica do THD): Experiência Inicial. 1º Congresso Paulista de Coloproctologia. São Paulo 8 e 9 de junho de 2012.
17. Infantino A, Altomare DF, Bottini C, Bonanno M, Mancini S. Prospective randomized multicentre study comparing stapler haemorrhoidopexy with Doppler-guided transanal haemorrhoid dearterialization for third-degree haemorrhoids. *Colorectal Dis*. 2012 Feb;14(2):205-211.
18. Jeong WJ, Cho SW, Noh KT, Chung SS. One Year Follow-up Result of Doppler-guided Hemorrhoidal Artery Ligation and Recto-Anal Repair in 97 Consecutive Patients. *J Korean Soc Coloproctol*. 2011 Dec;27(6):298-302.
19. Lewis MI. Diverse methods of managing hemorrhoids: cryohemorrhoidectomy. *Dis Colon Rectum*. 1973 May-Jun;16(3):175-7. Neiger A (1989) Infrared-photo-coagulation for hemorrhoids treatment. *Int Surg* 74:142-143
20. Longo A. Treatment of haemorrhoids disease by reduction of mucosa and haemorrhoidal prolapse with a circular suturing device: a new procedure. *Proceedings of the Sixth World Congress of Endoscopic Surgery*. Monduzzi, 1998;777-84.
21. Milligan ETC, Morgan C, Naughton JLF, Office RR. Surgical anatomy of the anal canal and the operative treatment of haemorrhoids. *Lancet* 1937; II:1119-24
22. Morinaga K, Hasuda K, Ikeda T. A novel therapy for internal hemorrhoids: ligation of the hemorrhoidal artery with a newly devised instrument (Moricorn) in conjunction with a Doppler flowmeter. *Am J Gastroenterol*. 1995 Apr;90(4):610-3.

23. Neiger A. Infrared-photo-coagulation for hemorrhoids treatment. *Int Surg*. 1989 Jul-Sep;74(3):142-3.
24. Parks AG. The surgical treatment of haemorrhoids. *Br J Surg*. 1956 Jan;43(180):337-51.
25. Pol RA, van der Zwet WC, Hoornenborg D, Makkinga B, Kaijser M, Eeftinck Schattenkerk M, Eddes EH. Results of 244 consecutive patients with hemorrhoids treated with Doppler-guided hemorrhoidal artery ligation. *Dig Surg*. 2010;27(4):279-84.
26. Qin PP, Huang B, Cai HJ, Ge Q, Wang ZL. A prospective controlled comparative study of Doppler-guided hemorrhoidal artery ligation versus operative procedures for prolapse and hemorrhoids. *Zhonghua Yi Xue Za Zhi*. 2010 Nov 30;90(44):3131-4.
27. Ramírez JM, Aguilera V, Elía M, Gracia JA, Martínez M. Doppler-guided hemorrhoidal artery ligation in the management of symptomatic hemorrhoids. *Rev Esp Enferm Dig*. 2005 Feb;97(2):97-103.
28. Ratto C, Donisi L, Parello A, Litta F, Doglietto GB. Evaluation of transanal hemorrhoidal dearterialization as a minimally invasive therapeutic approach to hemorrhoids. *Dis Colon Rectum*. 2010 May;53(5):803-11.
29. Ratto C, Giordano P, Donisi L, Parello A, Litta F, Doglietto GB. Transanal haemorrhoidal dearterialization (THD) for selected fourth-degree haemorrhoids. *Tech Coloproctol*. 2011 Jun;15(2):191-7.
30. Scheyer M. Doppler-guided recto-anal repair: a new minimally invasive treatment of hemorrhoidal disease of all grades according to Scheyer and Arnold. *Gastroenterol Clin Biol*. 2008 Jun-Jul;32(6-7):664
31. Sobrado Jr CW, Hora JAB. Tratamento Cirúrgico da Doença Hemorroidária por Desarterialização Transanal Guiada por Doppler associada ao Reparo Anorretal: A Técnica do THD. Atualização em Cirurgia do Aparelho Digestivo e em Coloproctologia – São Paulo: Departamento de Gastroenterologia da Faculdade de Medicina da USP, 2012. Jul 2012: 319-326.
32. Sohn N, Aronoff JS, Cohen FS, Weinstein MA. Transanal hemorrhoidal dearterialization is an alternative to operative hemorrhoidectomy. *Am J Surg*. 2001 Nov;182(5):515-9.
33. Testa A, Torino G, Gioia A. DG-RAR (Doppler-guided recto-anal repair): a new mini invasive technique in the treatment of prolapsed hemorrhoids (grade III-IV): preliminary report. *Int Surg*. 2010 Jul-Sep;95(3):265-9.
34. Toh EL, Ng KH, Eu KW. The fourth branch of the superior rectal artery and its significance in transanal haemorrhoidal dearterialisation. *Tech Coloproctol*. 2010 Dec;14(4):345-8.