

DISCUSSION

The cryptorchidism results from abnormalities in the formation and testicular descent during the embryonic period⁴. It is present in 6% of newborns at term and in 0.8% of infants under one year of age. Can be bilateral in up to 10% of cases, and sometimes is associated with other defects in genitourinary tract⁵.

The most feared complication of undescended testicle is cancer, ranging from 3.5-14.5% among patients with cryptorchidism⁵. The testis are intra-abdominal in 10% of cases and at risk 200 times greater in malignant transformation³. Malignant degeneration has the peak incidence in third and fourth decade of life^{2,3}. They are usually asymptomatic and are identified incidentally by imaging tests. When symptomatic, diagnosis is difficult and the symptoms may mimic acute appendicitis, urinary calculus and mass effects, compressive symptoms of the gastrointestinal and genitourinary tracts³. Imaging tests, US, CT and MRI show pelvic or retroperitoneal mass, well defined, homogeneous, without obvious evidence of necrosis or calcification^{2,3,5}. These findings have as main differential diagnoses lymphadenopathy and sarcoma, which are more common situations. The predominant histological type is pure seminoma (43%), followed by embryonic carcinoma (28%), teratocarcinoma (27%) and choriocarcinoma (2%)³. Surgical treatment is mandatory, with resection of intra-abdominal mass and chemotherapy may be an alternative, depending on the stage and histological type of malignant transformation².

REFERENCES

1. Küçük HF, Dalkılıç G, Kuroğlu E, Altuntaş M, Barişik NO, Gülmen M. Massive bleeding caused by rupture of intra-abdominal testicular seminoma: case report. *J Trauma*. 2002 May;52(5):1000-1.
2. Lim YJ, Jeong MJ, Bae BN, Kim SH, Kim JY. Seminoma in undescended testis. *Abdom Imaging*. 2008 Mar-Apr;33(2):241-3.
3. Miller FH, Whitney WS, Fitzgerald SW, Miller EI. Seminomas complicating undescended intraabdominal testes in patients with prior negative findings from surgical exploration. *AJR Am J Roentgenol*. 1999 Feb;172(2):425-8.
4. Wood HM, Elder JS. Cryptorchidism and testicular cancer: separating fact from fiction. *J Urol*. 2009 Feb;181(2):452-61.
5. Woodward PJ. Case 70: seminoma in an undescended testis. *Radiology*. 2004 May;231(2):388-92.

ABCDDV/1153

ABCD Arq Bras Cir Dig Letter to the Editor
2015;28(4):297

DOI: /10.1590/S0102-6720201500030022

LATE SURGICAL TREATMENT FOR SPONTANEOUS RUPTURE OF HEPATOCELLULAR ADENOMA: CASE REPORT

Tratamento cirúrgico tardio para ruptura espontânea de adenoma hepatocelular: relato de caso

Luis Eduardo Veras **PINTO**, João Paulo Ribeiro **SILVA**, Gustavo Coêlho **RÊGO**, José Huygens Parente **GARCIA**

From the Departamento de Cirurgia do Hospital Universitário Walter Cantídio (Hospital das Clínicas), Serviço de Cirurgia do Aparelho Digestivo, Universidade Federal do Ceará (Department of Surgery, University Hospital Walter Cantídio, Digestive Surgery Service, Federal University of Ceará), Fortaleza, CE, Brazil

Financial source: none
Conflicts of interest: none

Correspondence:

Luis Eduardo Veras Pinto
E-mail: luiseduardoveras@hotmail.com

Received for publication: 18/09/2014
Accepted for publication: 26/03/2015

INTRODUCTION

Hepatocellular adenoma (HA) is a rare benign neoplasm of the liver. It is strongly associated with oral contraceptive used by woman in childbearing age, by men receiving anabolic steroids and metabolic diseases. HA incidence has raised over the years from 5 per 1 million in 1964⁹ to 4 per 100.000³, for unknown reasons.

HA is important because of its risk of complications such as life threatening rupture of the tumor and malignant transformation. Surgical treatment in ruptured HA has a high mortality rate but it is still the standard procedure in those cases⁵. Emergency liver resection in ruptured HA has a mortality rate from 5-10%, but in elective resections the mortality rate is under 1%.

Different procedures have been suggested to decrease mortality rates and spare liver parenchyma, such as arterial embolization of ruptured adenomas, although it is not an available procedure in most centers.

CASE REPORT

A 44-year-old woman admitted in the emergency department of another hospital with complaints of sudden upper quadrant abdominal pain. She had been using oral contraceptives for 31 years. She presented with acute mild abdominal pain in epigastrium as well as right hypochondrium pain followed by light dyspnea and dizziness. She was treated with analgesics and ordered an abdominal ultrasound made only three days after the pain. The ultrasound showed a solid liver mass in the right hepatic lobe measuring 150x100x100 mm³. She was discharged without additional treatment.

After almost five months after the occurrence, she was referred to our surgical department for diagnostic investigation after another episode of abdominal pain just like the last time, followed by tachycardia and cold sweating. Physical examination revealed mild anemia and a diffuse abdominal pain, without peritonitis or palpable masses.

Lab exams showed 8.61g/dl haemoglobin, white blood count 8.980/mm³ and 214.00 platelets. Liver transaminases level were altered: ALT 306 IU/l, AST 154 IU/l, alkaline phosphatase 142 IU/l and gamma-glutamyl transferase 229 IU/l. Alfa-fetoprotein and clotting functions were normal.

Abdominal CT and MRI showed an enlarged liver, with a contrast enhanced liver mass involving segments VI and VII. The liver mass measured 118x70mm² associated with a perilesional voluminous hematoma measuring 8cm and haemoperitoneum. The radiologic findings suggested a ruptured hepatocellular adenoma (Figure 1)

Patient was admitted and sent to observation room to be prepared for surgical procedure after clinical improvement. She was transfused with two bags of packed red blood cells and intensive electrolytes control. Patient was sent to the operation room and had an open laparotomy with Chevron incision. During operative exploration was found a voluminous liver lesion involving segments VI and VII, large subcapsular hematoma over the right hepatic lobe and mild hemoperitoneum. The right lobe of the liver had strong adhesions to the right diaphragm. It was decided to make an anterior approach with inflow control due to the risk of bleeding, by ligation of the right portal vein and the right hepatic artery. The procedure continued with parenchyma right transection in the cantlie's line, showed

by ischemic demarcation, using bipolar forceps, argon coagulator device and kelly-crush technique. The liver parenchyma was dissected by the hematoma in some parts, disarranging the liver architecture. In the last part of the procedure, was mobilized all the right liver lobe followed by outflow control, by ligation of the right hepatic vein. During the liver mobilization, was able to see a large rupture in the posterior part of the liver and multiple adhesions between liver parenchyma and diaphragm, but without any sign of active bleeding. The surgery was completed with an anatomic right hepatectomy (Figures 2 and 3)

The surgical specimen weighted 1.170 g, measured 18,0x14,0x12,0 cm, presenting with a 12 cm rupture, externalizing an irregular and hemorrhagic mass. The tumor measured 1,0x6,0x6,0 cm, friable, along with a large subcapsular hematoma and clear margins.

Microscopy showed a neoplasm filled with hepatocytes cells showing enlarged plasmatic volume, eosinophils, macrovesicular steatosis, regular nucleus with minimum atypia and rare nucleolus. There was sinusoidal dilatation with spots of necrosis and hemorrhage. All these data corroborate with the hepatocellular adenoma (Figures 4 and 5).

Patient was kept in the intensive care unit for a day. There were no blood transfusions and the patient was discharged in the 6th operative day without any complications.

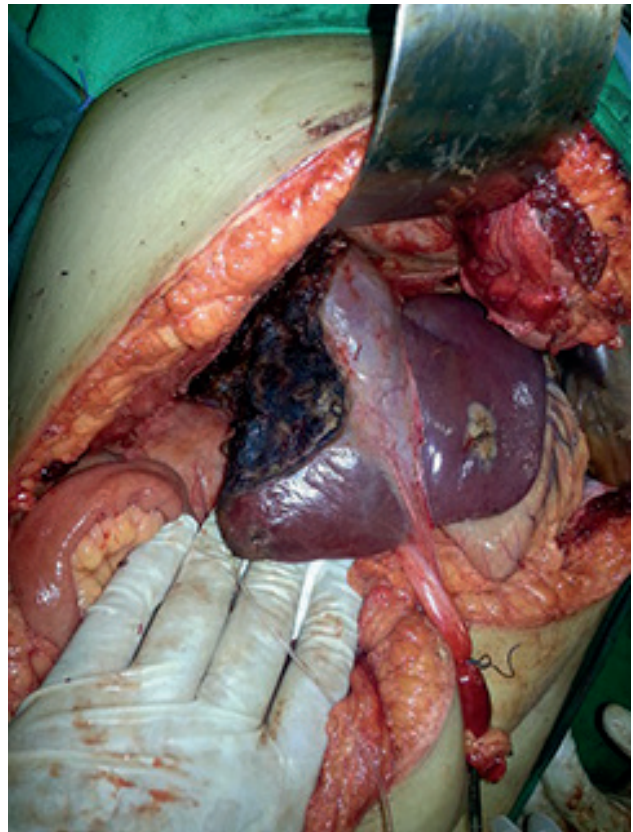


FIGURE 3 - Liver remnant after anatomic right hepatectomy (round ligament pulled caudally)

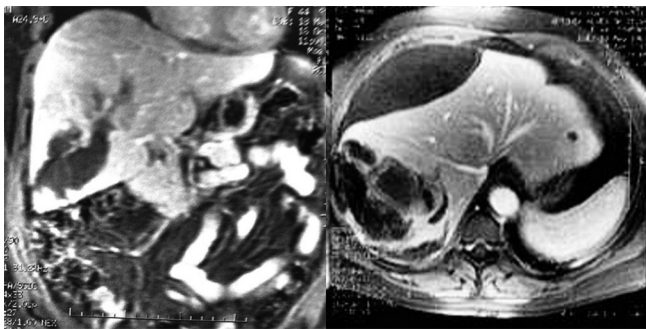


FIGURE 1 – MRI showing adenoma and bulky subcapsular hematoma

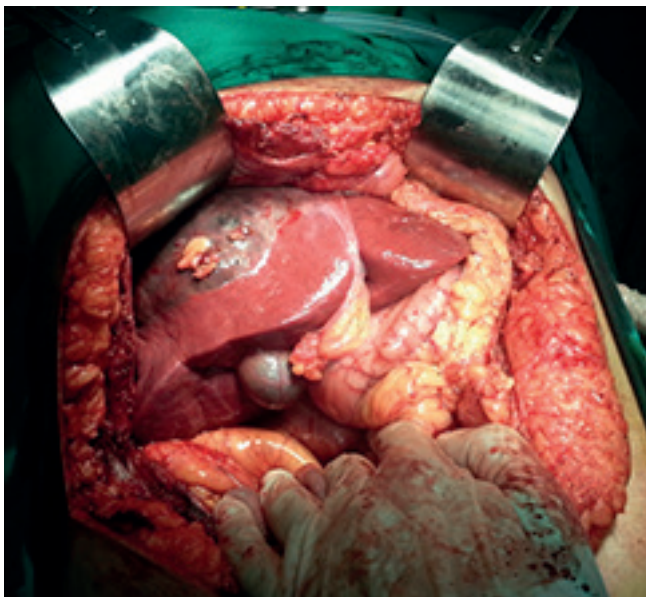


FIGURE 2 - Liver adenoma and subcapsular hematoma involving all right hepatic lobe

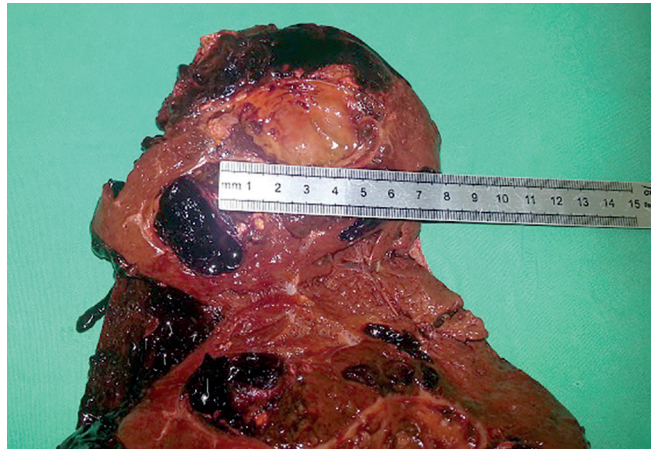

FIGURE 4 - Hepatic adenoma of 6 cm

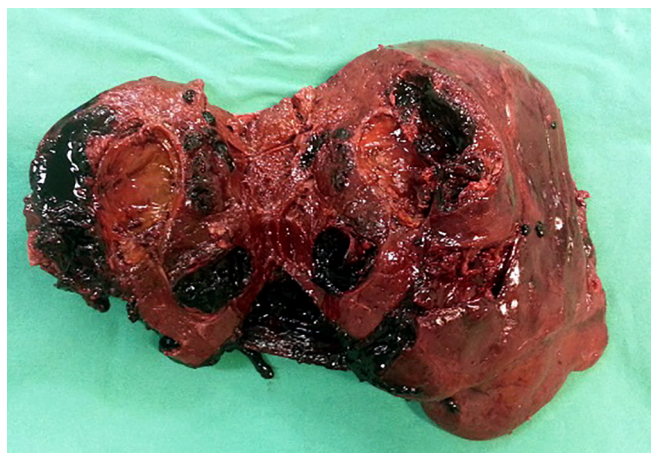


FIGURE 5 – Right hepatic lobe opened with the presence of adenoma and multiple clots infiltrating hepatic parenchyma

DISCUSSION

HA is a rare condition, and is commonly associated with oral contraceptive use⁶. The longer women uses oral contraceptives with increased estrogen level, the higher is the chance to develop hepatocellular adenomas. It's frequently seen in woman in childbearing age, as well as in men and diseases like hemochromatosis and type 1 glycogen storage disease⁴. It has clinical importance because of the risk of complications. Spontaneous rupture is the most important complication and usually happens in adenomas greater than 5 cm, in 20-40% of the cases⁴.

Approximately 10% of patients with HA present with acute abdominal pain due to rupture and hemoperitoneum, in some cases followed by hypovolemic shock. Patients might also refer nausea, vomiting, anorexia and fever. Mortality in ruptured HA has been associated with late diagnosis, coagulopathy and post-operative complications⁸.

Conservative treatment is used to small adenomas, mainly the ones related to oral contraceptives and anabolic steroids. The follow up in these cases includes abdominal TC or ultrasound each six months. Although, when the adenoma is higher than 5cm or show symptoms, the surgical treatment is recommended because of the increased risk of hemorrhage and malignant transformation⁶.

The surgical treatment vary on the case, as well as the different approaches of liver resection. The standard treatment for ruptured HA must be local or segmental resections, to spare as much liver parenchyma as possible. Laparoscopic hepatectomy is a feasible option for benign liver lesions in elective cases^{1,2}, but when it comes to ruptured, the open laparotomy is preferred due to bleeding and close contact to important liver vessels. Patients with ruptured HA must have elective resections when possible. There are several procedures to avoid emergency treatment but surgery still remains the main approach. If patient is stable and the tumor is localized in one segment, partial hepatectomy should be promptly made, but if there is important blood loss, volemic reposition with fluids and transfusions of hemocomponents should be attempted as well as arterial embolization¹⁰, with late resection when patient is stable. The selective arterial embolization have been playing an important role in the treatment of ruptured and non-ruptured HA, with low complication rates when compared with emergency surgery⁷. Arterial embolization is a very expensive procedure and is not available in most centers.

REFERENCES

1. Ardito F, Tayar C, Laurent A, Karoui M, Loriau J, Cherqui D. Laparoscopic Liver Resection for Benign Disease. Arch Surg 2007; 142 (12): 1188-93
2. Costa SRP, Araujo SM, Lima AOT, Chartuni ATP. Laparoscopic Right Posterior Sectionectomy for Treating Hepatic Tumors. ABCD Arq Bras Cir Dig 2010; 23(4): 275-9.
3. Deodhar A, Brody LA, Covey AM, Brown KT, Getrajdman GI. (2011) Bland embolization in the treatment of hepatic adenomas: preliminary experience. J VascIntervRadiol22:795-799;
4. Dokmak et al, 2009. Dokmak S, et al: A single center surgical experience of 122 patients with single and multiple hepatocellular adenomas. Gastroenterology 2009; 137:1698-1705.
5. Eckhauser FE, Knol JA, Raper SE, Thompson NW. Enucleation combined with hepatic vascular exclusion is a safe and effective alternative to hepatic resection for liver cell adenoma. Am Surg. 1994;60:466-71.

6. Herman P, Pugliese V, Machado MAC, Montagnini AL, Salem MZ, Bachella T et al. Hepatic Adenoma and Focal Nodular Hyperplasia: Differential Diagnosis and Treatment. World J Surg 2000; 24(5): 372-76
7. Huurman VA, Stoot JH, van der Linden E, Terpstra OT, Schaapherder AF. Necrosis of a large hepatic tumor after hemorrhage and subsequent selective arterial embolization. World J Gastroenterol. 2006;12:6059-61.
8. Marini et al, 2002. Marini P, et al: Management of spontaneous rupture of liver tumours. Dig Surg 2002; 19:109-113.
9. Puech A, Pages A, Dermenghem M, Seignalet J. (1964) Multinodular Adenoma of the Liver. Montp Med 65:114-119. Ad'enomemultinodulaire du foie.
10. Terkivatan et al, 2001. Terkivatan T, et al: Treatment of ruptured hepatocellular adenoma. Br J Surg 2001; 88:207-209.

ABCDDV/1154

ABCD Arq Bras Cir Dig Letter to the Editor
2015;28(4):299

DOI: /10.1590/S0102-6720201500030023

RIGHT-SIDED BOCHDALEK HERNIA IN ADULT ASSOCIATED WITH CHOLESTATIC SYNDROME: CASE REPORT

Hérnia de Bochdalek à direita em adulto, associada à síndrome colestática: relato de caso

José Moreira dos **SANTOS-NETTO**, Cássio Virgílio Cavalcante **OLIVEIRA**, Marcelo Gonçalves **SOUSA**

From the Departamento de Cirurgia, Centro de Ciências Médicas, Universidade Federal da Paraíba, Hospital Universitário Lauro Wanderley (Department of Surgery, Lauro Wanderley University Hospital), João Pessoa, PB, Brazil.

Financial source: none
Conflicts of interest: none

Correspondence:

José Moreira dos Santos Netto
Email: moreira_netto@hotmail.com

Received for publication: 22/01/2015
Accepted for publication: 16/06/2015

INTRODUCTION

The congenital diaphragmatic hernia (CDH) is defined as an anatomical defect on diaphragm, which permits the herniation of abdominal viscera into the thorax⁴. The hernia occurs due to an incomplete occlusion of the pleuroperitoneal channel during the embryonic period. The main cause of the incomplete closure can be a genetic mutation, a teratogen or both.

In terms of anatomic location, the CDH can be classified as Bochdalek type when an incomplete pleuroperitoneal channel occlusion is found posterolaterally; as Morgagni type, while the defect is seen retrosternally; and yet as a congenital transhiatal esophageic type hernia. Among them, the Bochdalek type is the most common, found in 78-90% of patients; the Morgagni type, in 1,5-6% of cases; and transhiatal, 14-24%¹¹.

In most cases, the clinical impact occurs in the neonatal period, since only 10% of hernias are diagnosed after this period⁷. In neonates, the clinical presentation is acute, providing a higher morbidity and mortality. In adulthood, symptoms, if any, are more insidious, vague and intermittent, affecting not