



Medical Microbiology

Investigation of *Helicobacter pylori* antigen in stool samples of patients with upper gastrointestinal complaints



Zeki Calik^a, Murat Karamese^{a,*}, Osman Acar^a, Selina Aksak Karamese^b, Yalcin Dicle^c, Fatih Albayrak^d, Serpil Can^e, Bulent Guvendi^f, Alpgiray Turgut^g, Mustafa Cicek^h, Halil Yazgiⁱ

^a Department of Microbiology, Faculty of Medicine, Kafkas University, Kars, Turkey

^b Department of Histology and Embryology, Faculty of Medicine, Kafkas University, Kars, Turkey

^c Department of Nursing, School of Health, Mus Alparslan University, Mus, Turkey

^d Department of Internal Medicine, Faculty of Medicine, Ataturk University, Erzurum, Turkey

^e Department of Physiology, Faculty of Medicine, Kafkas University, Kars, Turkey

^f Department of Genereal Surgery, Faculty of Medicine, Kafkas University, Kars, Turkey

^g Department of Biochemistry, Faculty of Veterinary, Ataturk University, Erzurum, Turkey

^h Department of Anatomy, Faculty of Medicine, Gazi Osman Pasa University, Tokat, Turkey

ⁱ Department of Microbiology, Faculty of Medicine, Ataturk University, Erzurum, Turkey

ARTICLE INFO

Article history:

Received 8 January 2015

Accepted 23 August 2015

Associate Editor: Ana Lúcia da Costa Darini

Keywords:

Helicobacter pylori

Upper gastrointestinal complaints

Rapid urease test

H. pylori card test

ABSTRACT

Helicobacter pylori infection is usually acquired in early childhood and it can persist throughout life without antibiotic treatment. This study aimed to compare the accuracy of the noninvasive *H. pylori* Stool Antigen Test-applied on the stool samples with the invasive gold standart Rapid Urease Test-applied on the gastric biopsy samples of patients with upper gastrointestinal complaints. After endoscopy, biopsy and stool specimens were taken in 122 patients. The infection was detected with rapid urease test which is accepted as gold standart test. Rapid, one-step *H. pylori* card test was applied to all patients stool specimens. In this study 106 of the 122 patients (86.8%) were positive for *H. pylori* infection, while 16 of the 122 patients (13.2%) were negative. *H. pylori* card test was negative in 13 of the 16 patients and was positive in 98 of the 106. The sensitivity, specificity, positive and negative predictive values were 92.45%, 81.25%, 97.02%, and 61.90%, respectively. *H. pylori* card test is rapid, easy, noninvasive and inexpensive methods for detection *H. pylori* infection. This test showed high sensitivity and specificity. Additionally, it may be a good alternative to invasive tests for the detection of *H. pylori* infections especially in children.

© 2015 Sociedade Brasileira de Microbiologia. Published by Elsevier Editora Ltda. This is an open access article under the CC BY-NC-ND license (<http://creativecommons.org/licenses/by-nc-nd/4.0/>).

* Corresponding author.

E-mail: murat.karamese@hotmail.com (M. Karamese).

<http://dx.doi.org/10.1016/j.bjm.2015.11.022>

1517-8382/© 2015 Sociedade Brasileira de Microbiologia. Published by Elsevier Editora Ltda. This is an open access article under the CC BY-NC-ND license (<http://creativecommons.org/licenses/by-nc-nd/4.0/>).

Introduction

Helicobacter pylori (*H. pylori*) is classified as a gram-negative, spiral-shaped bacterium and a microaerophilic, fastidious, human pathogen. *H. pylori* infection is usually acquired in early childhood and it can persist throughout life without antibiotic treatment. It affects about 20% of the population in developed countries and more than 90% in the developing world.^{1–4} Oral–oral and fecal–oral are the most common methods of transmission.⁵

H. pylori specifically colonizes on the gastric mucus layer, and it has developed a variety of mechanisms to survive in the harsh acidic environment of the gastric mucosa.⁶ *H. pylori* contains many virulence factors that cause the infection and contributes to gastric inflammation.⁷ It is a major cause of gastric and duodenal ulcer and gastritis, and the organism has been etiologically associated with Mucosal-Associated Lymphoid Tissue (MALT) lymphoma and gastric carcinoma.^{8,9}

Invasive and non-invasive tests are used in the diagnosis of *H. pylori* infection. The invasive methods include culture, histology, and urease tests. Biopsy specimens obtained with upper gastrointestinal endoscopy are necessary for these tests.^{10–12} The noninvasive methods include stool antigen test (SAT), urea breath test and serology.¹³

All the tests have advantages and disadvantages. The rapid urease test (RUT) is a gold standard method for the detection of *H. pylori*, and it is faster and cheaper than other invasive tests.^{14,15} Proton pump inhibitors (PPIs), bismuth-containing compounds and antimicrobial agents may affect the performance of this test by inhibiting urease activity. In addition, other urease-producing microorganisms in the gastric mucosa can cause false positive results.^{12,16} SATs are non-invasive and inexpensive methods to detect active *H. pylori* infection. This test has two versions: enzyme immunoassay and immunochromatography. Eradication of *H. pylori* infection is evaluated by SATs. Therefore this test is useful before and after *H. pylori* therapy.^{2,16,17}

This study aimed to compare the accuracy of the non-invasive *H. pylori* Stool Antigen Test (SAT) applied on the stool samples with the invasive gold standard Rapid Urease Test (RUT) applied on the gastric biopsy samples of patients with upper gastrointestinal complaints.

Materials and methods

Patient selection and collection of samples

This study was approved by the Local Ethics Committee of Ataturk University, Institute of Health Science with the number of 1466. The subjects were selected from patients with upper gastrointestinal complaints admitted to the Ataturk University, Medical Faculty and Department of Gastroenterology. Of those referred to the endoscopy unit for gastrointestinal endoscopy to evaluate dyspeptic complaints, 122 (49 male, 73 female) were included in this study. Patients taking bismuth preparations, PPIs, H₂ receptor antagonists or antibiotics for the last month or taking anti-acids for the last

two days were excluded from the study. The first stool samples of all patients were collected immediately after the endoscopy.

Detection of *H. pylori* in biopsy samples

The RUT (Salubris Helicheck, Boston, USA) was used for the detection of *H. pylori* on biopsy samples in this study. *H. pylori* produce an abundance of urease. The urease enzyme hydrolyses urea to release CO₂ and NH₃. The release of ammonia increases the pH of the medium. The urease activity causes a change in the pH indicator color for positive *H. pylori* results. All the biopsy specimens were taken from the patients during endoscopy and the RUTs were performed by the clinicians according to the manufacturer's protocol.^{2,18}

Investigation of *H. pylori* antigens in stool samples

The rapid, one-step *H. pylori* card test (H+R *H. pylori* CARD, Madrid, Spain) was used to investigate the presence of *H. pylori* antigens in the stool samples. This test is a qualitative immunochromatographic assay for the determination of *H. pylori* in stool samples. The membrane is precoated with monoclonal antibodies, on the test band region, against *H. pylori* antigens. During testing, the sample is allowed to react with the colored conjugate (anti-*H. pylori* monoclonal antibodies-red polystyrene microspheres) predried on the test strip. The mixture then moves up the membrane by capillary action. As the sample flows through the test membrane, the coloured particles migrate. For a positive result, the specific antibodies present on the membrane will capture the colored conjugate. The mixture continues to move across the membrane to the immobilized antibody placed in the control band region, where a red band always appears. The presence of this red band serves as; an internal control for the reagents and verification that sufficient volume was added and proper flow was obtained.

The stool samples were evaluated by the card test according to the manufacturer's protocol. A single red band appearing across the central window in the site marked with the control line was considered negative. A red band appearing in the site marked with the result line and in the site marked with the control line was considered positive. A total absence of the control band, regardless of the appearance of the result site was considered invalid.

Statistical analysis

The statistical analysis was performed using SPSS for Windows Version 17.0 (Statistical Package for Social Sciences version 17.0). Positive predictive value, negative predictive value, sensitivity and specificity were evaluated with the following formulas.

Positive predictive value;

$$\text{True positives}/(\text{True positive} + \text{False positive}) \times 100$$

Negative predictive value;

$$\text{True negatives}/(\text{False negatives} + \text{True negatives}) \times 100$$

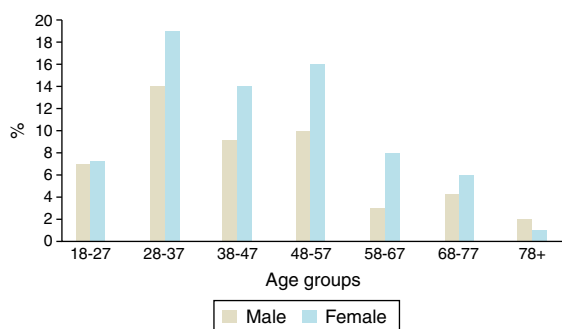


Fig. 1 – The age groups of patients with upper gastrointestinal complaints.

Table 1 – Comparison of endoscopic findings and rapid urease test results.

Diagnosis	Rapid urease test positive	Rapid urease test negative	Total
Gastritis	91	15	106
Ulcer	15	1	16
Total	106	16	122

Sensitivity; True positives/(True positives + False negatives) × 100

Specificity; True negatives/(False negatives + True negatives) × 100

Results

The mean age of the 122 patients' was 45.02 ± 15.134 years. The male patients' ranged from 18 to 84 years old with a mean age of 44.41 ± 16.075 years. The female patients' ranged from 18 to 80 years old with a mean age of 45.42 ± 14.568 years.

The RUT detected *H. pylori* in 63 of the 73 female patients (59.4%) and 43 of the 49 male patients (40.6%) with upper gastrointestinal complaints. The RUT-positive patients with upper gastrointestinal complaints had a mean age of 45.21 ± 15.641 years and the RUT-negative patients with upper gastrointestinal complaints had a mean age of 43.75 ± 11.538 years. The relationship between patients with upper gastrointestinal complaints and their ages are shown in Fig. 1. The upper gastrointestinal complaints are most seen in 28–37 and 48–57 age ranges. It means that middle-age patients are under risk of upper gastrointestinal diseases.

Of the subjects, 106 (86.8%) were diagnosed with gastritis and 16 (13.2%) were diagnosed with ulcer by endoscopic

Table 3 – Evaluation of *H. pylori* card test with rapid urease test.

<i>H. pylori</i> Card Test	Rapid urease test		Total
	Positive	Negative	
Positive	98	3	101
Negative	8	13	21
Total	106	16	122

Sensitivity; $98/(98+8) \times 100 = 92.45\%$
 Specificity; $13/(3+13) \times 100 = 81.25\%$
 Positive predictive value; $98/(98+3) \times 100 = 97.02\%$
 Negative predictive value; $13/(8+13) \times 100 = 61.90\%$
 False positive rate; $1 - 0.812 = 0.188 = 18.8\%$
 False negative rate; $1 - 0.924 = 0.076 = 7\%$.

biopsy. For the 106 RUT-positive patients, 91 (85.8%) were diagnosed with gastritis and 15 (14.2%) were diagnosed with ulcer. For the gastritis patients diagnosed by endoscopy, 91 (85.8%) were *H. pylori* positive according to the RUT. The RUT also tested positive for 15 (93.75%) of the patients with ulcers diagnosed by endoscopy (Table 1).

H. pylori infection was positive in 106 patients according to the RUT. Among these patients, 98 (93.75%) were positive for *H. pylori* according to the immunochromatographic assay (rapid one-step *H. pylori* card test). In addition, 3 (18.75%) of the RUT-negative patients were positive according to this method (false positive). In regards to the endoscopy diagnosis, 85 of the 91 (93.4%) *H. pylori*-positive gastritis patients and 13 of the 15 (86.6%) *H. pylori*-positive ulcer patients were positive according to the immunochromatographic assay.

In addition, 12 of the 15 (80%) *H. pylori*-negative gastritis patients and the single *H. pylori*-negative ulcer patients were negative according to the card test (Table 2).

The *H. pylori* card test and RUT results were compared and positive predictive value, negative predictive value, sensitivity and specificity were evaluated for the card test (Table 3).

Discussion

Approximately half of the world's population is infected with *H. pylori*. *H. pylori* infection is especially a public-health problem in developing countries. It is the leading cause of various upper gastroduodenal tract diseases such as gastric and duodenal ulcer, gastritis, MALT and gastric carcinoma.^{9,13,15} *H. pylori* infection can be detected by invasive and noninvasive methods. Endoscopy is necessary for the invasive tests. All these methods have advantages and disadvantages.^{14,16}

Table 2 – All the data about the test results and diagnosis of patients.

Diagnosis	Rapid urease test results	<i>H. pylori</i> Card Test Positive	<i>H. pylori</i> Card Test Negative	Total
Gastritis	Positive	85	6	91
	Negative	3	12	15
Ulcer	Positive	13	2	15
	Negative	0	1	1
	Total	101	21	122

The RUT is an invasive method and considered a gold standard. This test is inexpensive and allows for the rapid detection of *H. pylori*. The test may result in false negative if the patient recently used antimicrobial agents, PPIs or bismuth-containing compounds or a heterogeneous distribution of bacteria is present in the gastric mucus layer. In addition, contamination of the biopsy with saliva or other urease producing microorganisms in the gastric mucosa can cause false positive results. This test's sensitivity, specificity, and positive predictive values are more than >98%, 99%, and 99%, respectively.^{12,15,19} The RUT was used as the gold standard method and compared with the immunochromatographic assay (*H. pylori* card test) in this study.

The study examined 122 patients with upper gastrointestinal complaints especially ulcer and gastritis. The patients' biopsy specimens and stool samples were examined with the RUT and one-step *H. pylori* card test, respectively. Of these patients, 106 (86.8%) were positive for *H. pylori* infection; while 16 (13.2%) were negative. The sensitivity, specificity, positive predictive value and negative predictive value of the *H. pylori* card test were 92.45%, 81.25%, 97.02%, and 61.90%, respectively. In current literature, the sensitivity and specificity of the card test were 87.8%, 93.8% and 75–100%, respectively.^{11,20–25} These results are similar to our study and showed that performance of the card test was excellent for the noninvasive detection of *H. pylori*. In addition, previous studies have shown that the *H. pylori* card test exhibits good performance before and after eradication therapy.^{22,26}

In our study, 3 of the 16 (18.75%) RUT-negative patients were found positive according to the *H. pylori* card test (false positive). A cross-reaction with an antigen from *Helicobacter* species or other microorganism of the intestinal flora may cause false positive results.^{27,28} On the other hand, the irregular distribution of bacteria in the gastric mucosa can cause suspect false negative results with the RUT.¹⁹

Among the 106 RUT-positive patients, 8 (7.25%) were considered as negative (false negative) according to the immunochromatographic assay of the stool samples. Card test characteristics or the application of the test may have caused false negative results. Additionally, contamination of the biopsy with saliva or other urease producing microorganisms in the gastric mucus layer can cause false positive results with the RUT.^{12,19}

Infections caused by *H. pylori* usually affect adults. In many previous studies, patient's age ranged from 23 to 89 years.^{20,29,30} In the current study, patient's age ranged from 18 to 84 years. No children were included; however, previous studies have shown that the rapid one-step immunochromatographic card test performs well for the detection of *H. pylori* infection in children's stool samples.^{26,30}

Conclusions

In conclusion, the *H. pylori* card test is rapid, easy, noninvasive and inexpensive method for the detection of *H. pylori* infection. This test showed high sensitivity and specificity. No significant difference was found in sensitivity or specificity between the RUT (the gold standard method) and the one-step *H. pylori* card test. On the other hand, *H. pylori* in the stool is not a diagnosis

of ulcer and/or gastritis. So, invasive examination should also be done to confirm the diagnosis. However, this test can be used in some insufficient conditions such as if endoscopy is not available. Additionally, the *H. pylori* card test has exhibited good performance before and after eradication therapy and it is a good alternative to invasive tests for the detection of *H. pylori* infection in children.

Conflicts of interest

The authors declare no conflicts of interest.

REFERENCES

- Bonifácio BV, dos Santos Ramos MA, da Silva PB, Bauab TM. Antimicrobial activity of natural products against *Helicobacter pylori*: a review. *Ann Clin Microbiol Antimicrob*. 2014;13:54.
- Patel SK, Pratap CB, Jain AK, Gulati AK, Nath G. Diagnosis of *Helicobacter pylori*: what should be the gold standard? *World J Gastroenterol*. 2014;20:12847–12859.
- Roesler BM, Rabelo-Gonçalves EM, Zeitune JM. Virulence factors of *Helicobacter pylori*: a review. *Clin Med Insights Gastroenterol*. 2014;7:9–17.
- Rhee KH, Park JS, Cho MJ. *Helicobacter pylori*: bacterial strategy for incipient stage and persistent colonization in human gastric niches. *Yonsei Med J*. 2014;55:1453–1466.
- Yang K, Li Y, Zhou X. [Overview of researches for *Helicobacter pylori* in oral cavity and stomach]. *Hua Xi Kou Qiang Yi Xue Za Zhi*. 2014;32:314–318.
- Cid TP, Fernández MC, Benito Martínez S, Jones NL. Pathogenesis of *Helicobacter pylori* infection. *Helicobacter*. 2013;18(Suppl. 1):12–17.
- Kalali B, Mejías-Luque R, Javaheri A, Gerhard M. H. *pylori* virulence factors: influence on immune system and pathology. *Mediators Inflamm*. 2014;2014:426309.
- Tadesse E, Daka D, Yemane D, Shimelis T. Seroprevalence of *Helicobacter pylori* infection and its related risk factors in symptomatic patients in southern Ethiopia. *BMC Res Notes*. 2014;7:834.
- Osawa H. Ghrelin and *Helicobacter pylori* infection. *World J Gastroenterol*. 2008;14:6327–6333.
- Tamadon MR, Saberi Far M, Soleimani A, et al. Evaluation of noninvasive tests for diagnosis of *Helicobacter pylori* infection in hemodialysis patients. *J Nephropathol*. 2013;2:249–253.
- Pourakbari B, Ghazi M, Mahmoudi S, et al. Diagnosis of *Helicobacter pylori* infection by invasive and noninvasive tests. *Braz J Microbiol*. 2013;44:795–798.
- Mégraud F, Lehours P. *Helicobacter pylori* detection and antimicrobial susceptibility testing. *Clin Microbiol Rev*. 2007;20:280–322.
- Di Rienzo TA, D'Angelo G, Ojetti V, et al. 13C-Urea breath test for the diagnosis of *Helicobacter pylori* infection. *Eur Rev Med Pharmacol Sci*. 2013;17(Suppl. 2):51–58.
- Lopes AI, Vale FF, Oleastro M. *Helicobacter pylori* infection – recent developments in diagnosis. *World J Gastroenterol*. 2014;20:9299–9313.
- Hunt RH, Xiao SD, Megraud F, et al. *Helicobacter pylori* in developing countries World Gastroenterology Organization Global Guideline. *J Gastrointest Liver Dis*. 2011;20:299–304.
- Chey WD, Wong BC, Practice Parameters Committee of the American College of Gastroenterology. American College of Gastroenterology guideline on the management of *Helicobacter pylori* infection. *Am J Gastroenterol*. 2007;102:1808–1825.

17. Shimoyama T. Stool antigen tests for the management of *Helicobacter pylori* infection. *World J Gastroenterol*. 2013;19:8188–8191.
18. Mayo Clinic. Mayo Medical Laboratories; 2014. Available at: <http://www.mayomedicallaboratories.com/articles/hottopics/transcripts/2010/2010-8a-hpylori/8a-11.html> [accessed 3.12.14].
19. Ramis IB, de Moraes EP, Fernandes MS, et al. Evaluation of diagnostic methods for the detection of *Helicobacter pylori* in gastric biopsy specimens of dyspeptic patients. *Braz J Microbiol*. 2012;43:903–908.
20. Chisholm SA, Watson CL, Teare EL, Saverymuttu S, Owen RJ. Non-invasive diagnosis of *Helicobacter pylori* infection in adult dyspeptic patients by stool antigen detection: does the rapid immunochromatography test provide a reliable alternative to conventional ELISA kits? *J Med Microbiol*. 2004;53(Pt 7):623–627.
21. Gatta L, Perna F, Ricci C, et al. A rapid immunochromatographic assay for *Helicobacter pylori* in stool before and after treatment. *Aliment Pharmacol Ther*. 2004;20:469–474.
22. Veijola L, Myllyluoma E, Korpela R, Rautelin H. Stool antigen tests in the diagnosis of *Helicobacter pylori* infection before and after eradication therapy. *World J Gastroenterol*. 2005;11:7340–7344.
23. Wu IC, Wang SW, Yang YC, et al. Comparison of a new office-based stool immunoassay and (13)C-UBT in the diagnosis of current *Helicobacter pylori* infection. *J Lab Clin Med*. 2006;147:145–149.
24. Ozdemir M, Baykan M. Evaluation of the *Helicobacter pylori* stool antigen test (HpSA) in the diagnosis of *Helicobacter pylori* infection in dyspeptic patients. *Genel Tıp Derg*. 2005;15:65–70.
25. Li YH, Guo H, Zhang PB, Zhao XY, Da SP. Clinical value of *Helicobacter pylori* stool antigen test, ImmunoCard STAT HpSA, for detecting *H pylori* infection. *World J Gastroenterol*. 2004;10:913–914.
26. Antos D, Crone J, Konstantopoulos N, Koletzko S. Evaluation of a novel rapid one-step immunochromatographic assay for detection of monoclonal *Helicobacter pylori* antigen in stool samples from children. *J Clin Microbiol*. 2005;43: 2598–2601.
27. Krausse R, Müller G, Doniec M. Evaluation of a rapid new stool antigen test for diagnosis of *Helicobacter pylori* infection in adult patients. *J Clin Microbiol*. 2008;46:2062–2065.
28. Silva JM, Villares CA, Monteiro MDS, Colaúto C, dos Santos AF, Mattar R. Validation of a rapid stool antigen test for diagnosis of *Helicobacter pylori* infection. *Rev Inst Med Trop Sao Paulo*. 2010;52:125–128.
29. Trevisani L, Sartori S, Rossi MR, et al. Evaluation of a new rapid immunoassay for the detection of *Helicobacter pylori* in faeces: a prospective pilot study. *Aliment Pharmacol Ther*. 2005;21:485–489.
30. Kuloğlu Z, Kansu A, Kirsacıoğlu CT, et al. A rapid lateral flow stool antigen immunoassay and (14)C-urea breath test for the diagnosis and eradication of *Helicobacter pylori* infection in children. *Diagn Microbiol Infect Dis*. 2008;62: 351–356.