

Evaluation of opening pattern and bone neoformation at median palatal suture area in patients submitted to surgically assisted rapid maxillary expansion (SARME) through cone beam computed tomography

Daniel Gomes SALGUEIRO¹, Vitor Hugo Leite de Oliveira RODRIGUES¹, Victor TIEGHI NETO¹, Carolina Carmo de MENEZES², Eduardo Sanches GONÇALES³, Osny FERREIRA JÚNIOR³

1- Master's Student, Department of Stomatology, Bauru School of Dentistry, University of São Paulo, Bauru, Brazil.

2- Department of Pediatric Dentistry, Orthodontics and Community Health, Bauru School of Dentistry, University of São Paulo, Bauru, Brazil.

3- Department of Stomatology, Discipline of Oral Surgery, Bauru School of Dentistry, University of São Paulo, Bauru, Brazil.

Corresponding address: Osny Ferreira Júnior - Universidade de São Paulo, Faculdade de Odontologia de Bauru - Departamento de Estomatologia - Al. Octávio Pinheiro Brisola, 9-75 - 17012-901 - Bauru - SP - Brazil - Phone: +551432358258 - e-mail: osnyfjr@fob.usp.br

Submitted: December 10, 2014 - **Modification:** May 25, 2015 - **Accepted:** May 26, 2015

ABSTRACT

Surgically assisted rapid maxillary expansion (SARME) is the treatment of choice to adult patients even with severe transversal maxillary discrepancies. However, the adequate retention period to achieve the bone remodeling, thus assuring treatment stability, is controversial. Objective: To evaluate the opening pattern and bone neoformation process at the midpalatal suture in patients submitted to surgically assisted (SARME) through cone beam computed tomography (CBCT). Material and Methods: Fourteen patients were submitted to SARME through subtotal Le Fort I osteotomy. Both the opening pattern and the mean bone density at midpalatal suture area to evaluate bone formation were assessed pre- and post-operatively (15, 60 and 180 days) through CBCT. Results: Type I opening pattern (from anterior to posterior nasal spine) occurred in 12 subjects while type II opening pattern (from anterior nasal spine to transverse palatine suture) occurred in 2 individuals. The 180-day postoperative mean (PO 180) of bone density value was 49.9% of the preoperative mean (Pre) value. Conclusions: The opening pattern of midpalatal suture is more related to patients' age (23.9 years in type I and 33.5 years in type II) and surgical technique. It was not possible to observe complete bone formation at midpalatal suture area at the ending of the retention period studied (180 days).

Keywords: Transverse maxillary deficiency. Surgically assisted rapid maxillary expansion. Cone beam computed tomography

INTRODUCTION

Aging results in both bone density increasing and alterations on the biological behavior of the craniofacial complex sutures due to skeletal maturity. Although the increasing of bone rigidity is variable among individuals, it offers greater resistance to the forces applied to midpalatal suture during maxillary expansion³.

Surgically assisted rapid maxillary expansion (SARME) or surgically assisted maxillary expansion

(SAME) has been indicated both for patients reaching skeletal maturity and those previously submitted to rapid maxillary expansion (RME) whose treatment failed^{5,22}.

The literature emphasizes the indispensable role of post-expansion orthodontic retention of midpalatal suture^{14,17,25}. Within this retention period, both bone neoformation and suture remodeling takes place, decreasing the relapse possibilities²⁶. In the studies on SARME mentioned in international literature, the mean age of the patients undergoing

SARME varied from 19 to 29. The groups studied were quite small and mostly contained not more than 20 patients. The period of retention after expansion varies from 2 to 12 months. Generally, a period of 3 months is used¹³.

Still, the biological behavior of midpalatal suture of adult patients submitted to SARME has not been fully clarified, especially regarding the time amount required to achieve bone neoformation/mineralization and the adequate retention period to achieve bone remodeling, thus assuring treatment stability⁹.

Cone beam computed tomography (CBCT) is a useful tool to assess quantitatively the effects of maxillary expansion³⁰ and measure bone density at midpalatal suture area¹. Moreover, CBCT provides tridimensional visualization of craniofacial structures and other advantages, such as: relatively low cost; no anatomic structure superposition; easy access; and low radiation exposure compared to conventional multislice tomography⁷.

The aim of this study was to evaluate the opening pattern and bone neoformation at the midpalatal suture area, immediately before and during orthodontic retention period, in patients submitted to surgically assisted rapid maxillary expansion through cone beam computed tomography.

MATERIAL AND METHODS

It was a prospective study and the sample comprised 56 digital volumetric tomographies of 14 adult patients (four images *per* patient), both genders, presenting posterior cross bite due to transversal maxillary deficiency treated by surgically assisted rapid maxillary expansion (SARME), no systemic disease that contraindicated the procedure. The tomography device used in this research was the i-CAT (Imaging Sciences International Hatfield, Pennsylvania, USA). Expanders were intermittently activated. Patients wore either Hyrax (n=8) or Haas (n=6) appliances and did not have any contributory

disease contraindicating the surgical procedure. One surgeon performed all surgeries at hospital environment. The images used in this study came from the institutional files. This study was approved by the Ethics in Research Committee protocol number 401.136 and all participants signed an informed consent agreement.

All patients were subjected to modified subtotal Le Fort I with osteotomy of pterygoid pillars and midpalatal suture according to Betts, et al.⁵ (1995), but without osteotomy of the nasal septum (Figure 1). The four tomographies were obtained at pre-operative and 15-, 60-, and 180-day post-operative periods for each patient. During the surgery, 1.0 g of cephalothin and 10 mg of intravenous dexamethasone were administered in addition to the drugs needed for the general anesthesia. Cephalothin was maintained for 24 hours and during this period they were under nursing care.

The following activation protocol was used: after a latency period of five days, the screws were turned 0.5 mm *per* day ($\frac{1}{4}$ turn at the morning and $\frac{1}{4}$ turn at night) for 7 days followed by no activation for the next 7 days. The activation-latency cycles were interpolated until the palatal cusps of maxillary pre-molars and molars touched the buccal cusps of mandibular pre-molars and molars, achieving the desired expansion²³.

All tomographies were evaluated through i-CAT Vision software. Firstly irregular tool was used to mark an irregular line from posterior to anterior nasal spine, following the hard palate curvature at sagittal reformations (Figure 2). This tracing enabled to obtain the axial reformation of the marked area and to analyze the opening pattern and bone neoformation density at the midpalatal suture area (Figure 3).

The midpalatal suture opening pattern classification was carried out in all 14 tomographic images at 60-day post-operative period, corresponding to the ending of the expansion period, through visual analysis of the images. The

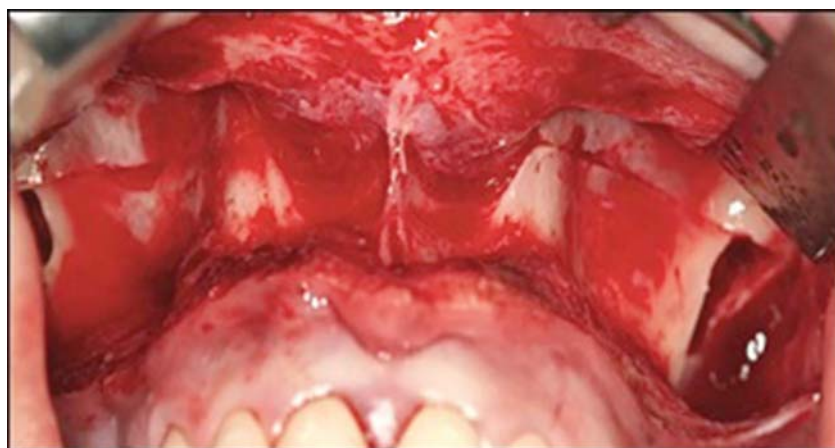

Figure 1- Subtotal Le Fort I osteotomy with zygomatic pillar step

classification was based on the study of Pereira, et al.¹⁹ (2010), as follows: Type I – opening from anterior to posterior nasal spine; Type II – opening from anterior nasal spine to transversal palatal suture (Figure 4).

To measure the bone neoformation density, HU Statistics tool was used by marking rectangles (1 mm²) on all extension of the suture/disjunction of midpalatal suture at about 3 mm spacing among

them through Distance tool.

Once the rectangular area was marked, the software provided the mean expressed in Hounsfield units (HU). Approximately 15 rectangular marks were performed along with the midpalatal suture on 56 sample images, divided into the following areas: anterior (from the anterior nasal spine to incisor foramen), median (from incisor foramen to transversal palatal suture) and posterior (from

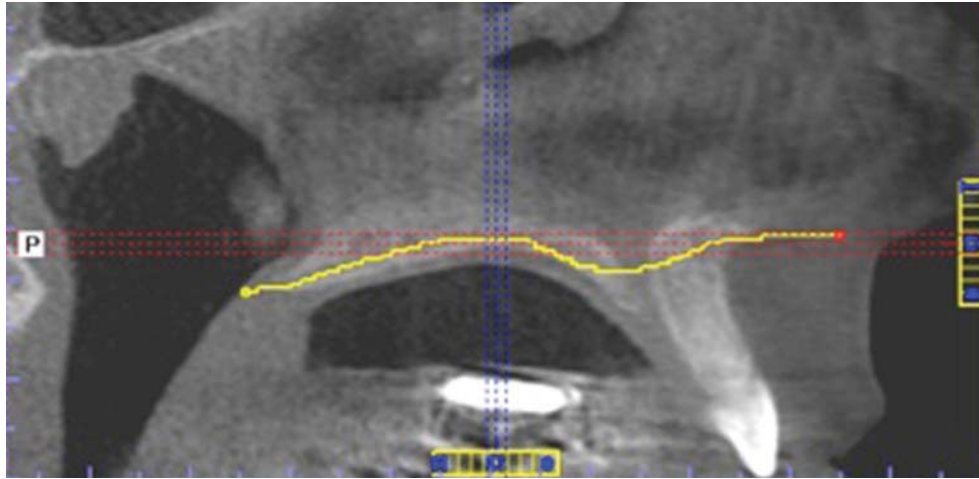


Figure 2- Demarcation of hard palate curvature with the aid of “irregular” tool

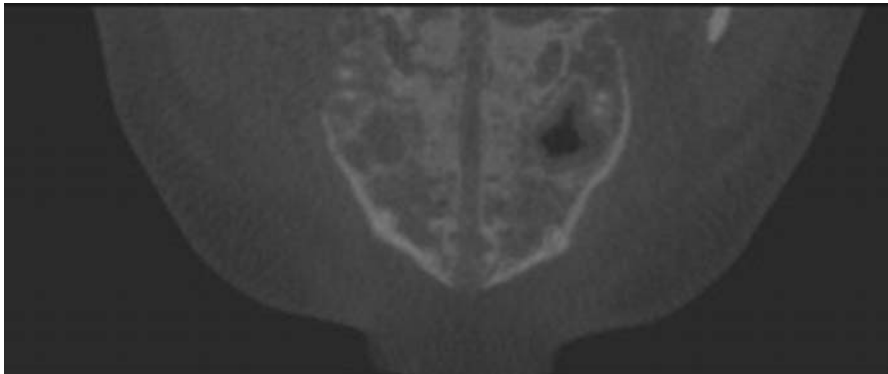


Figure 3- New axial reformation obtained from hard palate demarcation

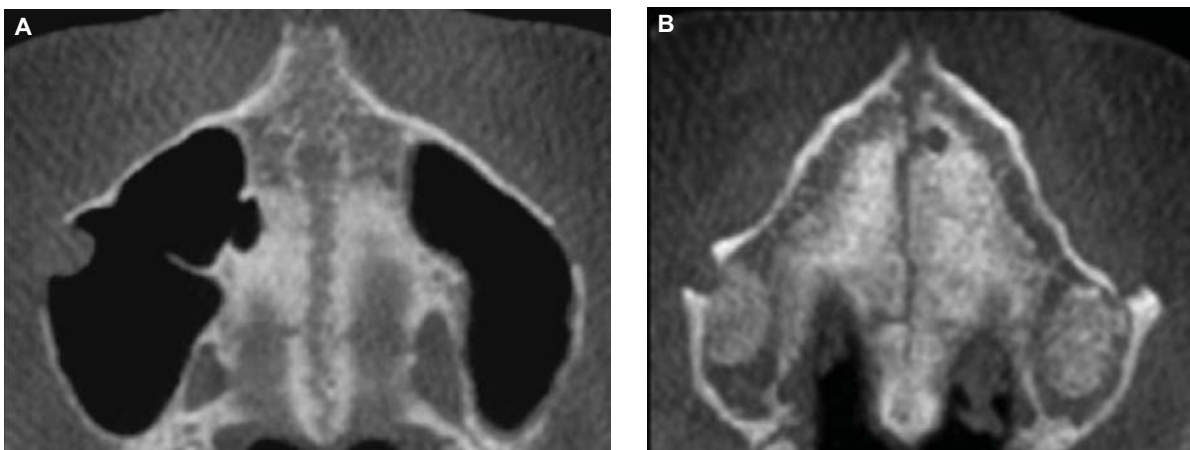


Figure 4- Type I (left) and type II (right) opening pattern

transversal palatal suture to posterior transversal palatal suture) (Figures 5 and 6).

A single examiner assessed the images. Paired t-test was applied to verify the systematic error, at $p < 0.05$. Dahlberg's formula was used to evaluate the casual error. ANOVA was applied for statistical analysis. All statistical tests were performed by Statistica 7.0 software.

RESULTS

The studied sample comprised 56 tomographies of 14 individuals (9 females and 5 males) with mean age of 25.3 years ($SD=5.71$ years). Orthodontic appliances consisted of Hyrax (tooth born) and Haas (tooth and mucosa born), respectively installed in 6 and 8 individuals. Type I opening pattern of midpalatal suture was observed in 12 images, while Type II in 2 images (Figure 7 and 8).

Table 1 displays the bone density mean of the

three evaluated maxillary areas: anterior, median and posterior, at each studied period. The bone density at these 3 periods: 15-day post-operative (PO 15), 60-day post-operative (PO 60) and 180-day post-operative (PO 180) was smaller than the Initial Period (Pre) in the three regions studied. The period allowed the evaluation of bone density after that the total activation (PO 60) demonstrated the smallest density values. The density values found after six months retention (PO 180) were lower than the Initial Period (Pre). The last column compares the final and initial density in percentage.

Table 2 shows the density results at each studied period: pre-operative (Pre), 15-day post-operative (PO 15), 60-day post-operative (PO 60), and 180-day post-operative (PO 180) with the mean of each period and the percentage regarding to initial period and analyzed by ANOVA. Statistically significant differences were seen by Tukey test.

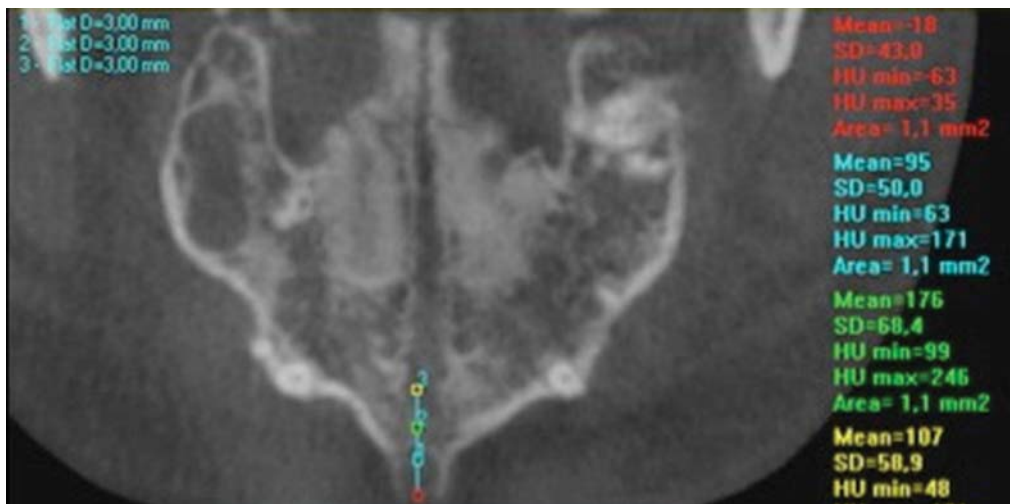


Figure 5- Density mean along with the area of interest

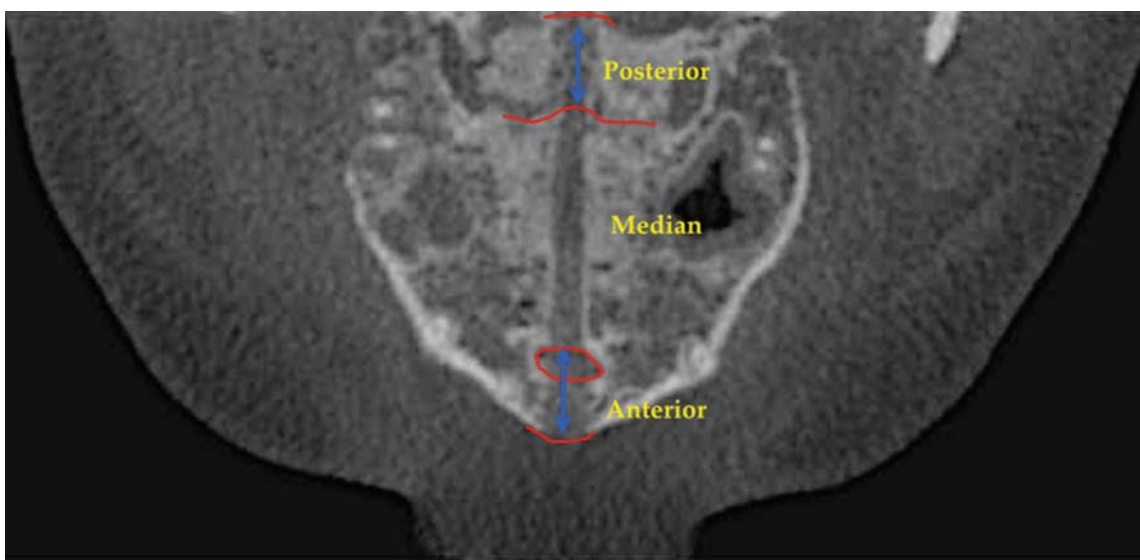


Figure 6- Marked anterior, median and posterior areas

Patients	Gender	Age	Expander	Opening pattern
1	F	33	Haas	Type I
2	F	20	Haas	Type I
3	M	38	Haas	Type II
4	M	26	Hyrax	Type I
5	F	19	Hyrax	Type I
6	F	21	Haas	Type I
7	F	21	Hyrax	Type I
8	F	26	Hyrax	Type I
9	M	23	Haas	Type I
10	F	22	Hyrax	Type I
11	M	23	Haas	Type I
12	F	29	Hyrax	Type II
13	F	32	Hyrax	Type I
14	M	21	Hyrax	Type I
	Mean	25.28		
	SD	5.71		

Figure 7- Gender, age, expander type and opening pattern of midpalatal suture

	Type I	Type II
Age	23.9 years	33.5 years

Figure 8- Mean age for type I and II opening patterns

DISCUSSION

Rapid maxillary expansion (RME) is considered a simple, highly efficient and stable treatment to correct even severe transversal maxillary discrepancies. However, RME success rate decreases with aging²⁴. Moreover, aging and the increasing of resistance against skeletal expansion is directly related because of cranial and face suture fusion^{12,13}. Accordingly, RME is a treatment with high predictability in children and teenagers, but not in adults, commonly resulting in treatment failure and complications like tooth tipping and reduction in buccal cortical bone thickness²³.

Ideally, the maxillary orthodontic expansion should preferably occur before 15 years old. However, expansion in individuals reaching skeletal maturity is possible, but without predictable and stable outcomes. RME after the pubertal peak tends to show more relapse, hence it is important to plan a sufficient retention period with older patients⁶.

Usually, the orthopedic mechanics is capable of opening the midpalatal suture until 16-17 years old¹⁰. Considering individuals achieving skeletal maturity, RME does not provide stable expansion of atresic maxilla whose deficiency was greater than 5 mm²⁸.

Thus, currently, surgically assisted rapid

expansion (SARME) has been the treatment of choice, well accepted by the literature, to overcome the bone resistance to expansion^{5,22}. This treatment modality consists of associating surgical and orthodontic procedures aiming at providing space on tooth arch for tooth alignment⁸.

A few studies demonstrated through finite element analysis the need of osteotomy of pterygoid pillars to decrease the stress concentration on this area, which was very high when the osteotomy was not performed^{2,12}. Moreover, this procedure prevents damage to sphenoid bone and results in a more uniform expansion of the maxillary posterior area.

Other authors concluded that SARME associated with pterygomaxillary disjunction should be chosen in patients aged above 20 years¹⁵. The aforementioned study was conducted through computed tomography aiming to compare pre- and post-operative periods of patients submitted to SARME with and without pterygoid pillar disjunction.

SARME is considered a procedure with little risk of serious complications, although major complications are mentioned in literature, such as: life threatening epistaxis to a cerebrovascular accident, skull base fracture with reversible oculomotor nerve pareses and orbital compartment syndrome¹³. Less serious complications reported are post-operative hemorrhage, pain, sinusitis, palatal tissue irritation/ulceration, asymmetrical expansion, nasal septum deviation, periodontal problems and relapse²³.

The mean age of this study's patients was 25.3 years (Figure 1 and 2), which is in agreement with

Table 1- Density mean values (HU) of anterior, median, posterior areas of palate and percentage at the final period (PO 180) in relation to that of initial period (Pre)

Area	Pre	PO 15	PO 60	PO 180	%
Anterior	334.117	135.953	65.85	101.625	30.4%
Median	435.281	264.155	110.007	188.631	43.3%
Posterior	424.916	326.857	151.497	279.188	65.7%

Table 2- ANOVA comparative analysis of density variables before and after 15, 60, and 180 days in relation to the mean values and standard deviation (SD) of all areas. Different letters show statistically significant differences among means by Tukey test

Density variables	Mean	SD	p
Pre	379.214C	148.193	0.000*
PO 15	234.732B	143.393	0.000*
PO 60	104.995A	152.092	0.000*
PO 180	189.287AB	100.968	0.000*

* p<0.05

the literature which reports that patients submitted to SARME showed an age range from 19-29 years¹⁵. The mean age of patients exhibiting type I opening pattern was 23.9 years, while the mean age of those presenting type II opening pattern was 33.5 years. This result corroborates the literature reporting the difficult in obtaining a greater and more parallel maxillary expansion in older individuals⁴. According to the findings of this study, age was directly related to the opening pattern of the midpalatal suture. The rationale behind this affirmation is that all patients were submitted to a single surgical technique, but nevertheless exhibited different opening patterns of the midpalatal suture. Thus, we can hypothesize that older individuals would show a tendency towards difficult in obtaining disjunction of the posterior area of maxilla, evidencing an opening pattern less parallel (V shaped). Consequently, these individuals would tend to present a type II opening pattern. Also, the results of this study did not show statistically significant differences regarding the expander type.

Although Hyrax and Haas appliances show similar effects, maxillary expansion is obtained through different mechanisms: dental-alveolar expansion by the former and more orthopedic expansion by the latter¹⁸. In this study, regardless of the expander type, the desired expansion of maxillary expansion was achieved with both appliances and the opening pattern of the midpalatal suture seems to be more related to the patient's age and surgical technique than to the expander type used in the orthopedic mechanics, as aforementioned explained.

It is worth emphasizing the indispensable role of post-expansion orthodontic retention of the midpalatal suture because at this period both bone neoformation and remodeling take place after disjunction, decreasing relapse possibilities²⁶. According to a study which compared the stability between rapid and slow maxillary expansion, the dental arch transverse dimensions showed a more pronounced relapse maintaining approximately 40% of initial molar expansion with significant difference from control²¹. Progel, et al.²² (1992), Berger, et al.⁴ (1998) and Koudstaal, et al.¹³ (2005), reported 0.88 mm (12%), 1.01 mm (17.5%) and 0.5 mm (55%) of relapse, respectively, in a 12-month study period. They concluded that expansion obtained with SARPE is stable, but all their patients were still in orthodontic treatment. Although a number of articles on the stability of surgically assisted rapid palatal expansion (SARPE) have been published, the reported stability varies considerably^{1,4,24}.

After midpalatal suture disjunction, bone repair of the area is required to reach treatment stability. However, literature has reached no consensus regarding to the retention period necessary for bone repair²⁹.

The midpalatal suture is the area in which the skeletal expansion is observed after RME or SARME and is commonly seen on conventional occlusal radiographs. On occlusal view, obtained through occlusal radiographs of the maxilla, midpalatal suture is visualized up to the middle of the palate. Consequently, the proper view of the posterior area of palate is not possible because of the superposition of the cranial base structures. Thus, the main advantage of computed tomography (CT) over occlusal radiograph of maxilla is the perfect visualization of the posterior area of midpalatal suture, without interference of the cranial structures¹⁶.

In one study through CBCT comprising 60 adult and 60 teenager patients, the authors concluded that bone density of adults was significantly higher than that of teenagers, but the density of the anterior palatal area of teenagers was similar to that of posterior palatal area of adults¹¹.

Similarly, a CT study with teenagers showed the complete midpalatal suture ossification from anterior to posterior nasal spine after a mean retention period of 8-9 months²⁷. Nevertheless, in this present study, the complete bone neoformation

of midpalatal suture did not take place within the studied period, that is, 180 days (6 months) of retention. These findings were similar to those of the study conducted by Petrick, et al.²⁰ (2011) through CT, who evidenced different density values between pre-operative and 7-month post-operative periods²⁰. The bone density of the anterior, median and posterior areas was 48%, 53% and 75% of their initial values, respectively. The aforementioned study verified that the retention period after SARME should be longer. Probably the difference in the retention periods between these studies occurred because the former employed children submitted to RME^{20,27}. As shown by some studies^{5,12}, RME tends to result in incomplete opening of posterior palatal area and consequently bone repair is faster together with the fact that bone neoformation takes place faster in children^{27,20}.

In this study, similarly to that of Petrick, et al.²⁰ (2011), the density values of the anterior area were significantly smaller than those of median and posterior areas of maxilla. The bone density of anterior, median, and posterior areas was 30.4%, 43.3% and 65.7% of the initial values, respectively.

The authors from this research acknowledge the limitation on the small sample size. A study with a large number of patients, especially older individuals, is needed to conclude emphatically that the age affects the opening pattern and the bone neoformation. Another limitation was the assessment performed by a single examiner.

The importance of this study relies on the fact that the bone density at the ending of the retention period (180 days) was smaller than that before SARME. Accordingly, a retention period longer than 180 days is necessary to find similar density values between pre- and post-operative periods.

CONCLUSIONS

Based on the methodology employed and the results obtained, it can be concluded:

1. The opening pattern of the palatal suture seems to be more related to patients' age than to type of orthopedic mechanics employed.

2. The bone density values after 180 days of retention were smaller than those of the pre-operative period, demonstrating that this retention period was not sufficient for the complete bone neoformation at the midpalatal suture area of the studied patients.

REFERENCES

1- Angelieri F, Cevidanes LH, Franchi L, Gonçalves JR, Benavides E, McNamara JA Jr. Midpalatal suture maturation: classification method for individual assessment before rapid maxillary expansion. *Am J Orthod Dentofacial Orthop.* 2013;144:759-69.

2- Assis DS, Xavier TA, Noritomi PY, Gonçalves AG, Ferreira O Jr, Carvalho PC, et al. Finite element analysis of stress distribution in anchor teeth in surgically assisted rapid palatal expansion. *Int J Oral Maxillofac Surg.* 2013;42:1093-9.

3- Bell RA. A review of maxillary expansion in relation to rate of expansion and patient's age. *Am J Orthod.* 1982;81:32-7.

4- Berger JL, Pangrazio-Kulbersh V, Borgula T, Kaczynski R. Stability of orthopedic and surgically assisted rapid palatal expansion over time. *Am J Orthod Dentofacial Orthop.* 1998;114(6):638-45.

5- Betts NJ, Vanarsdall RL, Barber HD, Higgins-Barber K, Fonseca RJ. Diagnosis and treatment of transverse maxillary deficiency. *Int J Adult Orthod Orthognath Surg.* 1995;10:75-96.

6- Bishara SE, Staley RN. Maxillary expansion: clinical implications. *Am J Orthod Dentofacial Orthop.* 1987;91:3-14.

7- De Vos W, Casselman J, Swennen GR. Cone-beam computerized tomography (CBCT) imaging of the oral and maxillofacial region: a systematic review of the literature. *Int J Oral Maxillofac Surg.* 2009;38:609-25.

8- Gonçalves ES. *Cirurgia ortognática: guia de orientação para portadores de deformidades faciais esqueléticas.* São Paulo: Santos Editora; 2010.

9- Gurgel JA, Malmström MF, Pinzan-Vercelino CR. Ossification of the midpalatal suture after surgically assisted rapid maxillary expansion. *Eur J Orthod.* 2012;34:39-43.

10- Haas AJ. Palatal expansion: just the beginning of dentofacial orthopedics. *Am J Orthod.* 1970;57:219-55.

11- Han S, Bayome M, Lee J, Lee YJ, Song HH, Kook YA. Evaluation of palatal bone density in adults and adolescents for application of skeletal anchorage devices. *Angle Orthod.* 2012;82:625-31.

12- Holberg C, Steinhäuser S, Rudzki I. Surgically assisted rapid maxillary expansion: midfacial and cranial stress distribution. *Am J Orthod Dentofacial Orthop.* 2007;132:776-82.

13- Koudstaal MJ, Poort LJ, van der Wal KG, Wolvius EB, Prah Andersen B, Schulten AJ. Surgically assisted rapid maxillary expansion (SARME): a review of the literature. *Int J Oral Maxillofac Surg.* 2005;34:709-14.

14- Kurt G, Altuğ-Ataç AT, Atac MS, Karasu HA. Changes in nasopharyngeal airway following orthopedic and surgically assisted rapid maxillary expansion. *J Craniofac Surg.* 2010;21:312-7.

15- Laudemann K, Petruchin O, Mack MG, Kopp S, Sader R, Landes CA. Evaluation of surgically assisted rapid maxillary expansion with or without pterygomaxillary disjunction based upon preoperative and post-expansion 3D computed tomography data. *Oral Maxillofac Surg.* 2009;13:159-69.

16- Loddi PP, Pereira MD, Wolosker AB, Hino CT, Kreniski TM, Ferreira LM. Transverse effects after surgically assisted rapid maxillary expansion in the midpalatal suture using computed tomography. *J Craniofac Surg.* 2008;19:433-8.

17- Mitsuda ST, Pereira MD, Passos AP, Hino CT, Ferreira LM. Effects of surgically assisted rapid maxillary expansion on nasal dimensions using acoustic rhinometry. *Oral Surg Oral Med Oral Pathol Oral Radiol Endod.* 2010;109:191-6.

18- Oliveira NL, Silveira AC, Kusnoto B, Viana G. Three-dimensional assessment of morphologic changes of the maxilla: a comparison of 2 kinds of palatal expanders. *Am J Orthod Dentofacial Orthop.* 2004;126:354-62.

19- Pereira MD, Prado GP, Abramoff MM, Aloise AC, Masako Ferreira L. Classification of midpalatal suture opening after surgically assisted rapid maxillary expansion using computed tomography. *Oral Surg Oral Med Oral Pathol Oral Radiol Endod.* 2010;110:41-5.

20- Petrick S, Hothan T, Hietschold V, Schneider M, Harzer W, Tausche E. Bone density of the midpalatal suture 7 months after surgically assisted rapid palatal expansion in adults. *Am J Orthod Dentofacial Orthop.* 2011;139:S109-16.

21- Pinheiro FH, Garib DG, Janson G, Bombonatti R, Freitas MR. Longitudinal stability of rapid and slow maxillary expansion. *Dental Press J Orthod.* 2014;19:70-7.

22- Pogrel MA, Kaban LB, Vargervik K, Baumrind S. Surgically assisted rapid maxillary expansion in adults. *Int J Adult Orthodon Orthognath Surg.* 1992;7:37-41.

- 23- Ribeiro PD Jr, Gonçalves ES, Souza PC, Nary Filho H, Luz JGC. Clinical evaluation of surgically assisted maxillary expansion (SAME). *Rev Dent Press Ortodon Ortop Facial*. 2006;11:44-59.
- 24- Schauseil M, Ludwig B, Zorkun B, Hellak A, Korbmacher-Steiner H. Density of the midpalatal suture after RME treatment - a retrospective comparative low-dose CT-study. *Head Face Med*. 2014;10:18.
- 25- Seeberger R, Kater W, Davids R, Thiele OC. Long term effects of surgically assisted rapid maxillary expansion without performing osteotomy of the pterygoid plates. *J Craniomaxillofac Surg*. 2010;38:175-8.
- 26- Silva Filho OG, Capelozza Filho L, Fornazari RF, Cavassan AO. Rapid maxillary expansion: an essay on its instability. *Rev Dental Press Ortodon Ortop Facial*. 2003;8:17-36.
- 27- Silva Filho OG, Lara TS, Silva HC, Bertoz FA. Behavior of the midpalatal suture in children submitted to rapid maxillary expansion: evaluation with computerized tomography. *Rev Dent Press Ortodon Ortop Facial*. 2007;12:94-103.
- 28- Silverstein K, Quinn PD. Surgically-assisted rapid palatal expansion for management of transverse maxillary deficiency. *J Oral Maxillofac Surg*. 1997;55:725-7.
- 29- Suri L, Taneja P. Surgically assisted rapid palatal expansion: a literature review. *Am J Orthod Dentofacial Orthop*. 2008;133:290-302.
- 30- Woller JL, Kim KB, Behrents RG, Buschang PH. An assessment of the maxilla after rapid maxillary expansion using cone beam computed tomography in growing children. *Dental Press J Orthod*. 2014;19:26-35.