

## CASE REPORT

# Articular and cutaneous nerve block at elbow: two cases report



Sandeep Diwan <sup>a</sup>, Abhijit Nair <sup>b,\*</sup>

<sup>a</sup> Basavatarakam Indo-American Cancer Hospital and Research Institute, Department of Anaesthesiology, Telangana State, Pune, India

<sup>b</sup> Sancheti Hospital, Department of Anaesthesia, Maharashtra, Hyderabad, India

Received 24 November 2019; accepted 20 March 2020

Available online 20 June 2020

### KEYWORDS

Regional anesthesia;  
Acute pain;  
Fracture;  
Elbow;  
Ultrasound

### PALAVRAS-CHAVE

Anestesia regional;  
Dor aguda;  
Fratura;  
Cotovelo;  
Ultrassom

### Abstract

**Background and objectives:** In patients with elbow fractures, when there is suspected injury to underlying nerves, it is imperative for surgeons to elicit the function in the immediate post-operative period. Brachial plexus blocks like interscalene, supraclavicular and infraclavicular approaches can be a hurdle in such situations. The block planned should allow assessment of integrity of the nerves immediately in the postoperative period.

**Case report:** We describe two cases in which we administered a block not yet described in literature. We blocked the cutaneous and articular branches innervating the elbow under ultrasound guidance. General anesthesia was administered in both cases. The block provided stable intraoperative hemodynamics, good postoperative analgesia and also allowed surgeons to test the viability of the nerve.

**Conclusion:** In situations where nerves are injured during elbow fractures, selective articular cutaneous block at elbow can be used as it provides good perioperative analgesia, besides allowing evaluation of motor and sensory components in the postoperative period.

© 2020 Sociedade Brasileira de Anestesiologia. Published by Elsevier Editora Ltda. This is an open access article under the CC BY-NC-ND license (<http://creativecommons.org/licenses/by-nc-nd/4.0/>).

### Bloqueio do nervo articular e cutâneo no cotovelo: relato de dois casos

### Resumo

**Justificativa e objetivos:** Quando há suspeita de lesão nos nervos subjacentes em pacientes com fratura de cotovelo, é imperativo que o cirurgião estimule a função dos nervos no pós-operatório imediato. Bloqueios do plexo braquial com as técnicas interescalênica, supraclavicular e infraclavicular pode ser um obstáculo nessas situações. O bloqueio deve ser planejado de modo a permitir a avaliação da integridade dos nervos no pós-operatório imediato.

\* Corresponding author.

E-mail: [abhijitnair95@gmail.com](mailto:abhijitnair95@gmail.com) (A. Nair).

*Relato de caso:* Descrevemos dois casos em que realizamos uma técnica de bloqueio ainda não descrito na literatura. Realizamos o bloqueio dos ramos cutâneo e articular de nervos que inervam o cotovelo com auxílio de ultrassonografia. Anestesia geral foi realizada nos dois casos. O bloqueio proporcionou estabilidade hemodinâmica intraoperatória, boa analgesia pós-operatória e também permitiu que os cirurgiões testassem a viabilidade do nervo.

*Conclusão:* Em fraturas do cotovelo associadas à lesão de nervos, o bloqueio seletivo articular cutâneo do cotovelo pode ser utilizado, pois proporciona boa analgesia perioperatória, além de permitir a avaliação dos componentes motores e sensoriais no pós-operatório.

© 2020 Sociedade Brasileira de Anestesiologia. Publicado por Elsevier Editora Ltda. Este é um artigo Open Access sob uma licença CC BY-NC-ND (<http://creativecommons.org/licenses/by-nc-nd/4.0/>).

## Introduction

In certain clinical scenarios, Brachial Plexus Blocks (BBB) could be contraindicated. The situations we describe are damaged peripheral nerve requiring a repair and postoperative assessment and coagulopathy. We endorsed upon a novel technique a combination of articular and cutaneous nerve blocks – referred henceforth as the elbow plexus block for elbow surgery. The block is easy to perform, provided good quality postoperative analgesia and allows the surgeon to assess affected nerves immediately after surgery.

## Case reports

### Case 1

A 28 years-old male sustained a right elbow fracture with an X-Ray picture that revealed a displaced radial head fracture with severe elbow instability. He was unable to flex fingers and had hypoesthesia of the ring and little finger. A radial head fracture with probable median and ulnar nerve palsy was diagnosed. He did not have any medical problems and laboratory investigations were within normal limits. The surgeon decided for a lateral and medial exploration, radial head fixation and medial collateral ligament repair. Analgesia was crucial for postoperative analgesia. He wanted an intact brachial plexus system to test the median, radial and ulnar nerves in the postoperative period.

### Case 2

A 70 years-old obese female (92 kg, BMI = 35.91 kg m<sup>-2</sup>) with a cirrhotic of the liver for 15 years sustained a right elbow fracture following a fall. Clinical examination revealed stable hemodynamics and Child-Pugh Class B with 8 points (bilirubin – 3.3 mg dL<sup>-1</sup>, INR = 1.07, no encephalopathy, serum albumin of 3.2 gm% and no ascites). APTT was 50 seconds, platelet count of 58,000 mm<sup>3</sup> and fibrinogen levels of 362 mg dL<sup>-1</sup>. The findings in (US) of the abdomen were consistent with a fibrotic liver with portal hypertension and mild splenomegaly. Chest X-Ray revealed cardiomegaly and 2-dimensional echocardiography depicted an ejection

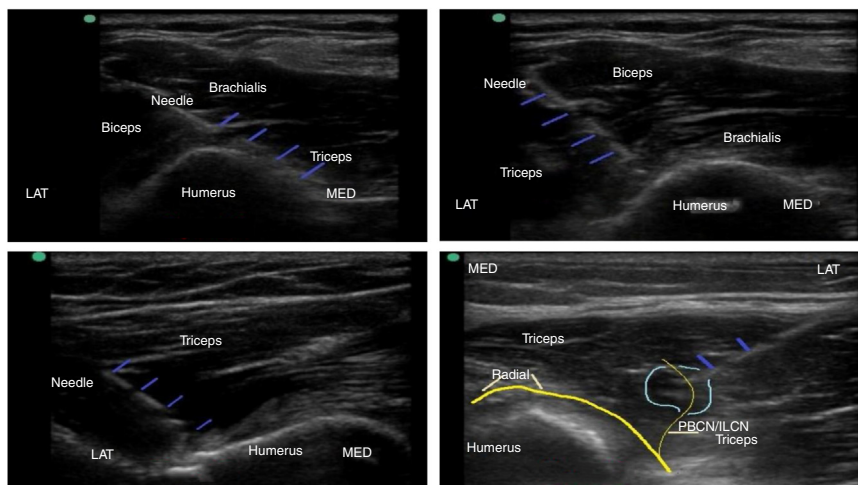
fraction of 60% with no regional wall motion abnormalities and mild mitral regurgitation. Before the surgical procedure, she received one unit of single donor plasma as suggested by the medical gastroenterologist.

Obesity and the lateral position adopted for the complex surgical procedure called for general anesthesia. Considering her underlying coagulopathy, the brachial plexus block was a contraindication for postoperative analgesia. Analgesia was imperative, considering the extensive dissection and instrumentation for elbow surgery.

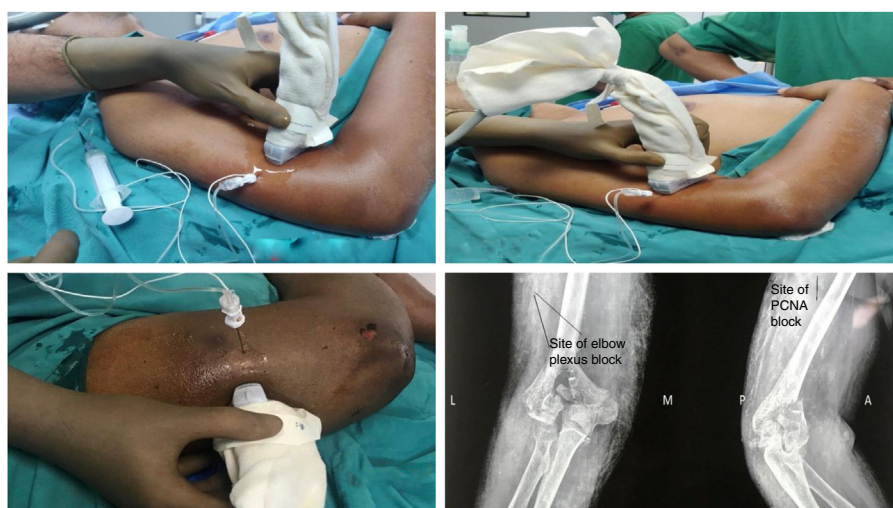In both patients, we decided for general anesthesia followed by elbow plexus block. After confirming nil by mouth status, general anesthesia was induced with 0.03 mg kg<sup>-1</sup> midazolam, 100 µg fentanyl and 2–2.5 mg kg<sup>-1</sup> propofol all intravenously. The airway was secured with 4 sized supraglottic airway (Ambu® AuraGain™) after confirming no history suggestive of reflux esophagitis. General anesthesia was maintained with oxygen: air and sevoflurane.

The articular branches of radial (C5–8, T1) and musculocutaneous nerves (C5–7) were targeted using a linear array high-frequency US probe (6–13 MHz, Sonosite, Inc). The anteromedial (Fig. 1), anterolateral (Fig. 2) and posterolateral (Fig. 3) planes 1–1.5 cm above the bone and 5–6 cm from the epicondyles were identified, below the triceps (medial), biceps brachialis and triceps (lateral), respectively.

With an in-plane approach, a 50 mm insulated needle (Stimuplex® D, 22 Ga. × 2 in.) was introduced in the anteromedial, anterolateral and posterolateral planes of the lower third humerus, 1–1.5 cm away from the bone, and 5–6 cm from the epicondyles. 5 mL each of 0.25% bupivacaine with 30 µg clonidine was injected as the needle was withdrawn below the biceps-brachialis in the anteromedial and lateral planes and the posterolateral plane below the triceps. In both patients, a Posterior Brachial Cutaneous Nerve (PBCN) block (Fig. 4) was performed with 3 mL of 0.25% bupivacaine as it emerged from the radial nerve. (LA) seepage towards the radial nerve was avoided. The probable needle placements are demonstrated in X-Ray. In patient 1, an additional blockade of the Medial Brachial Cutaneous Nerve of Arm (MABCN) was performed in the subcutaneous layer of distal arm parallel to the ulnar nerve; 1.5 mL of 0.25% bupivacaine was injected and LA seepage towards the ulnar nerve was avoided.



**Figure 1** A, Antero-medial needle placement and injection close to the bone (needle – blue). B, Anterolateral needle placement close to the bone (needle – blue). C, Posterolateral needle placement close to the bone (needle – blue). D, Injection of LA at a Posterior Brachial CN Cutaneous Nerve (PBCN). PBCN – the light-yellow thin line; Radial nerve – Thick yellow line (needle – blue).



**Figure 2** A, Needle placement in the anteromedial plane. B, Needle placement in the anterolateral plane. C, Needle placement for PBCN from lateral to medial. D, Needle placements demonstrated on X-Ray.

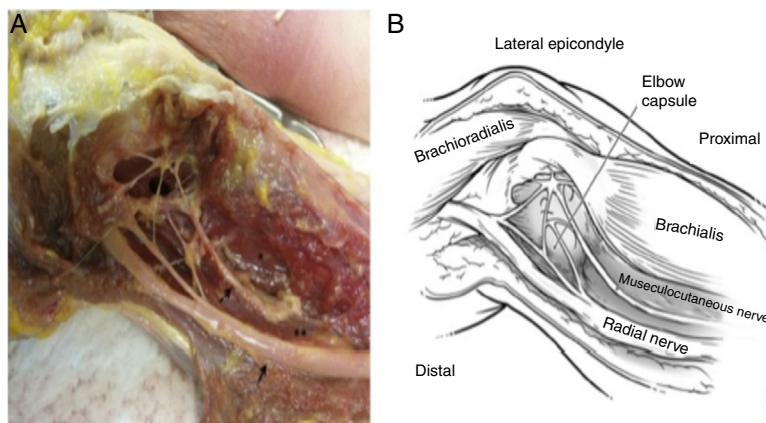
Intraoperatively, during skin incision, fracture manipulations and closure, hemodynamics was stable. No analgesics were required and non-depolarizing muscle relaxant was used. Thirty minutes before closure IV paracetamol was infused. Immediate postoperative and at 24 hours with oral paracetamol prescribed 8-hourly the VAS was 2–3/10. Motor movements could be assessed postoperatively in both patients by the surgeon at the second hour without any neurological damage done.

Thirty minutes later, at the surgical incision and during various time points (monitored every 10 minutes), the hemodynamics did not alter from its baseline. Thirty minutes before skin closure intravenous tramadol 100 mg was administered. The time to first analgesic and requirements of 48 hours injection tramadol was noted. At the end of the surgical procedure with the patient awake, the movements and sensations were questioned at the fourth hour, which was intact. In the 48 postoperative hours, two injections

of 100 mg IV tramadol were administered. The patient was discharged on the third day.

### Discussion

In literature, we have not come across a technique describing a plexus block close to the elbow joint for postoperative analgesia. The radial and musculocutaneous nerve form a significant articular plexus between the lower biceps and brachioradialis and innervate the posterolateral and anterolateral capsules.<sup>1,2</sup> The skin over the posterior arm is innervated by the posterior and inferolateral cutaneous nerves arising from radial nerve.<sup>3</sup> Five milliliters of 0.25% bupivacaine with 30 µg of clonidine at both the sites is sufficient to provide excellent postoperative analgesia for 48 hours with rescue analgesia as and when required. The MABCN was blocked as per its sonoanatomic description.<sup>4</sup>

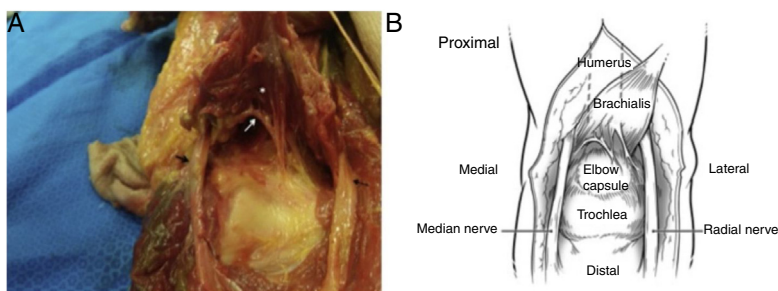


**Figure 3** A, Figure showing cadaveric dissection showing nerve plexus formed by radial and musculocutaneous nerve. B, Schematic diagram showing the nerve radial and musculocutaneous nerves with the muscles in relation to it.

Permission obtained from publisher Elsevier via Copyright Clearance Center.

License number: 4725640389382, dated 10<sup>th</sup> December 2019.

Image source: Nourbakhsh A, Hirschfeld AG, Schlatterer DR, Kane SM, Lourie GM. Innervation of the Elbow Joint: A Cadaveric Study. *J Hand Surg Am.* 2016;41:85-90.



**Figure 4** A, Figure showing articular branch of musculocutaneous nerve arising from posterior aspect of brachialis muscle. B, Schematic diagram showing the articular branch of musculocutaneous nerve.

Permission obtained from publisher Elsevier via Copyright Clearance Center.

License number: 4725640389382, dated 10<sup>th</sup> December 2019.

Image source: Nourbakhsh A, Hirschfeld AG, Schlatterer DR, Kane SM, Lourie GM. Innervation of the Elbow Joint: A Cadaveric Study. *J Hand Surg Am.* 2016;41:85-90.

The articular and cutaneous branches cannot be visualized on US. However, their location is consistent as described in dissections (Figs. 3 and 4), and therefore injecting LA with US guidance in the plane blocks the branches. The strength of our proposed block is that the motor power is preserved and that it is a peripheral block. This block is not a contraindication in patients with underlying coagulopathies, on low molecular weight heparin and on antiplatelet medications if surgery is of emergency or urgent. The limitations of this block are that the surgical relaxation and duration of postoperative analgesia offered will be definitely inferior to any brachial plexus we have described in the two cases of this report. A series of cases would have been better to expose the regional blocking technique used.

The use of tramadol or acetaminophen as analgesics is an issue since they have a ceiling dose and the comparison of the amount of medicines used could have been affected. The use of adjuvant medications such as gabapentinoids could have been used to complement analgesia.

We propose the elbow plexus block to be performed in those patients in whom the brachial plexus block is relatively

contraindicated. Further studies are necessary to ascertain the efficacy of this novel technique – the elbow plexus block in elbow surgeries –, and also explain its mechanism of action and injectate spread.

Written informed consent was obtained from the patients for using images and other clinical information to be reported in the journal. The patient understands that his/her name and initials will not be published, and due efforts will be made to conceal identity.

## Conflicts of interest

The authors declare no conflicts of interest.

## References

1. Cavalheiro CS, Filho MR, Rozas J, et al. Anatomical study on the innervation of the elbow capsule. *Rev Bras Ortop.* 2015;50:673-9.

2. Nourbakhsh A, Hirschfeld AG, Schlatterer DR, et al. Innervation of the elbow joint: a cadaveric study. *J Hand Surg Am.* 2016;41:85–90.
3. MacAvoy MC, Rust SS, Green DP. Anatomy of posterior antebrachial cutaneous nerve: practical information for surgeon operating on lateral aspect of elbow. *J Hand Surg Am.* 2006;31:908–11.
4. Chang KV, Mezian K, Naňka O, et al. Ultrasound imaging for the cutaneous nerves of the extremities and relevant entrapment syndromes: from anatomy to clinical implications. *J Clin Med.* 2018;7:457.