

Operating room fire prevention - preventive measures for safe eyelid surgery

Fogo em campo cirúrgico – Medidas preventivas para cirurgia palpebral segura

Daniella de Paiva Almeida Stuchi¹ <https://orcid.org/0000-0002-8407-8723>

Camila Cheble² <https://orcid.org/0000-0001-9912-0077>

Suzana Matayoshi³ <https://orcid.org/0000-0003-0630-4091>

ABSTRACT

Fire in the surgical field during eyelid surgery is an intra-operative complication that is dramatic for both the patient and the medical staff. It's being reported a case of surgical accident during eyelid surgery where the patient suffered a brow burn. There was interaction between the oxygen used for sedation (open mask) and a source of ignition represented by monopolar cautery. Although the patient presented good clinical evolution with complete recovery of the cutaneous lesion, this case is an alert to avoid such type of occurrence. This work highlights the conditions involved and the way of prevention.

Keywords: Fire/prevention & control; Operating room; Risk factors; Eyelids/surgery

RESUMO

Fogo em campo cirúrgico durante cirurgia palpebral é uma complicação intra-operatória que é dramática tanto para o paciente quanto para a equipe médica. Relatamos um caso de acidente cirúrgico durante cirurgia palpebral onde o paciente sofreu queimadura de supercílio. Houve interação entre o oxigênio usado para sedação (máscara aberta) e uma fonte de ignição representada pelo cautério monopolar. Embora o paciente tenha apresentado boa evolução clínica com recuperação total da lesão cutânea, este caso é um alerta para se evitar tais tipo de ocorrência. Ressaltamos neste trabalho quais as condições implicadas e o modo de prevenção.

Descritores: Fogo/prevenção & controle; Sala de cirurgia; Fatores de risco; Pálpebras/cirurgia

¹ Ophthalmology Department, Pontifical Catholic University of Campinas, Campinas County, SP, Brazil.

² Eye Plastic Surgery Department, Clinic Hospital, Medical School of University of São Paulo, São Paulo City, SP, Brazil.

³ Ophthalmology Discipline, Medical School of University of São Paulo, São Paulo City, SP, Brazil

The current study was carried out at the Medical School of University of São Paulo.

The authors declare no conflicts of interests.

Received for publication 25/02/2019 - Accepted for publication 13/06/2019.

INTRODUCTION

The present case report highlights a dangerous situation that can result in potentially severe complications to patients, namely: surgical fire in the operating room.⁽¹⁾

Most flammable anesthetics stopped being used in the 1970s to help reducing surgical fire risks. However, such risk persists due to abundance of high-energy surgical ignition sources, flammable surgical materials and open oxygen sources - surgical fire can cause severe disfigurement or death.

Surgical fire prevention requires understanding the risks posed by such events, as well as effective communication among surgeons, anesthetists and the nursing staff.^(1,2)

CASE REPORT

A 68-year-old male patient was subjected to brow ptosis correction and to upper blepharoplasty. Relevant antecedents comprised sleep apnea.

The surgery was performed in a general operating room; patient was sedated and subjected to local infiltration anesthesia. Povidone iodine aqueous solution (10%) was used as antiseptic; a tent-type face mask covered by surgical drape was also used.

It was noticed that oxygen saturation during surgery was low, so the anesthetist made the option for keeping the oxygen flow (O₂) in the mask at 7 liters per minute.

At the time to cauterize the medial fat pouch of patient's left eye, a spark went off as the monopolar (10 Watts) touched the Kelly forceps used to isolate the pouch and it burned the patient's left eyebrow hair. The surgery assistant rapidly used his hand to extinguish the flame and suffered local burn.

Patient's burn injury was immediately cleaned with sterile 0.9% saline solution. This procedure was followed by cold compress application and by dressing with 1% silver sulfadiazine, which was applied 2 times/day, for 15 days.

The patient presented good recovery without major sequelae (photos).

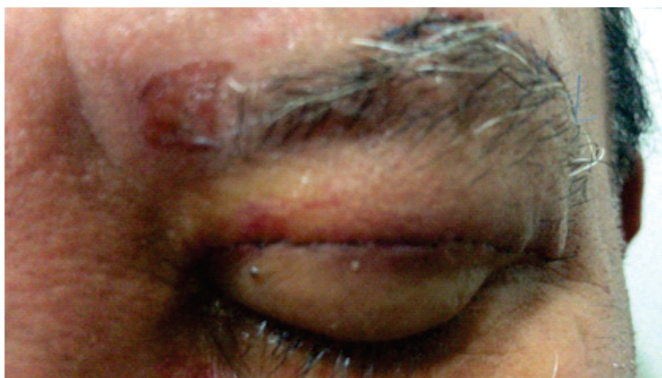

Figure 1: Three days after surgery.

DISCUSSION

This case report presents one of the most stressful situations likely to happen during eyelid surgeries. Although rare, intraoperative burn is a complication that eventually happens in operating rooms; therefore, it is necessary staying always alert to prevent it from happening. High oxygen concentration associated

with the monopolar-emitted spark generated the flame that burned patient's eyebrow in the herein reported case.

It is necessary taking into consideration some points to help promoting a safety culture based on strategies focused

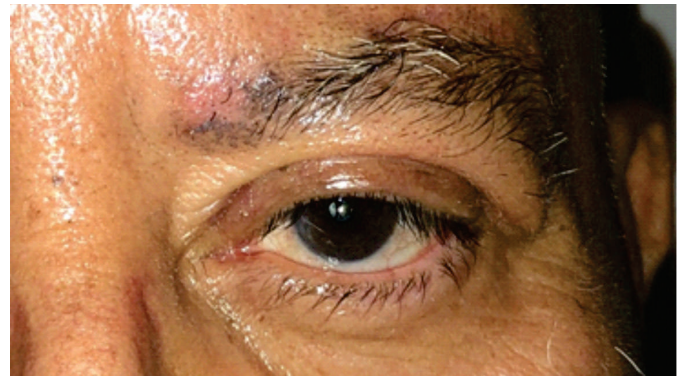


Figure 2: Ten days after surgery.

on reducing surgical fire risks. The use of alcohol-containing antiseptics can generate sparks, which can result in fire when the monopolar is used in oxygen-rich environments. Oxygen use should be interrupted for at least one minute prior to the use of an ignition source, a fact that requires communication and interaction between surgeon and anesthetist.

Open O₂ delivery systems, such as face masks and nasal cannulas, can lead to O₂-enriched environments, since air must be the first option in open delivery systems when patients do not require supplemental O₂. On the other hand, endotracheal tube or laryngeal mask should be used to protect the airway of patients who cannot maintain safe O₂ saturation levels and require supplemental O₂.⁽³⁾

It is known that other flammable products such as hair, sheets, dressings, ointments, among others, can be in the operating room during surgery; therefore, these materials must be isolated from the ignition source.^(4,5)

There are two electrosurgery types, namely: the monopolar and bipolar systems. According to the monopolar technique, an active electrode is used to conduct the electrical current, whereas a dispersion electrode is used for current output. On the other hand, the bipolar technique uses two identical electrodes (often similar to tweezers or scissors) to form a single bipolar instrument. The neutral electrode in the monopolar system is placed far from the active electrode, whereas these electrodes are separated by a short distance (1 mm to 3 mm) in the bipolar system in order to limit the electrical current flow in the tissue.⁽⁶⁾

The electric current transmitted by the active electrode in the monopolar system travels over a large area of patients' body before it gets to the dispersive electrode. Thus, this system poses great surgical fire risk because it exposes more tissue to electricity. Most often, monopolar electrosurgery injuries happen at the dispersive plate site, but they are also observed at sites presenting monitoring electrodes and in those subjected to accidental contact with metal objects, which act as alternative electricity dispersion pathways.⁽⁷⁾

The total dispersion surface becomes smaller and poses greater surgical fire risks when the dispersive plate is not fully adhered or when the irrigation fluid between plate and skin is not enough.⁽⁸⁾ This factor, as well as other recommendations, should be checked by the surgical team: metallic ornaments

must be removed; the electrocautery power must be confirmed before its activation - in case the surgeon requests continuous power increase, if patients present unusual response, or if there is interference in the monitoring signal during electrocautery use, it is necessary checking the whole circuit to rule out the possibility of failure;⁽⁹⁾ the audible indicator volume must be kept at audible level to enable the surgical team to be promptly alerted when the electrocautery is inadvertently triggered or when it is not working properly.⁽¹⁰⁾

The bipolar system eliminates many of these mechanisms, a fact that significantly minimizes the likelihood of accidental or unpredictable injuries due to the short gap between the active and return electrodes; it also limits electrode effects at local level and rules out the need of using the return plate, which can also lead to injurious processes.⁽⁸⁾

Surgeons and their teams do not need to know all electrosurgery details, but they must understand the way it works and some of its principles. In addition, they must know preventive measures and corrective actions that should be adopted to minimize the risk of unnecessary injuries.⁽⁷⁾

The patient in the present case presented good postoperative evolution towards recovery. Unfortunately, the kind of complication reported in his case can lead to severe physical damage, as well as to medical malpractice lawsuits.

The surgical team should identify potential surgical fire risks and develop a plan based on risk reduction strategies prior to surgery in order to promote awareness during these procedures. It is also important discussing about specific tasks to be achieved by each team member in case of surgical fire.⁽¹¹⁾

The major challenge lies on promoting the awareness of the surgical team as a whole. Thus, it is necessary launching educational courses and exercises to help these professionals developing skills to effectively manage surgical complications of this nature.

REFERENCES

1. Jones SB, Munro MG, Feldman LS, Robinson TN, Brunt LM, Schwaitzberg SD, et al. Fundamental use of surgical energy (FUSE): an essential educational program for operating room safety. *Perm J*. 2017;21:16-050.
2. Bruley ME. Surgical fires: perioperative communication is essential to prevent this rare but devastating complication. *Qual Saf Health Care*. 2004;13(6):467-71.
3. ECRI Institute. New clinical guide to surgical fire prevention. Patients can catch fire—here's how to keep them safer. *Health Devices*. 2009;38(10):314-32.
4. ECRI Institute. The patient is on fire! A surgical fires primer. *Guidance*. 1992;21(1):19-34.
5. ECRI Institute. Surgical fire safety. *Health Devices*. 2006;35(2):45-66.
6. Tucker RD, Hollenhorst MJ. Bipolar electrosurgical devices. *Endosc Surg Allied Technol*. 1993;1(2):110-3.
7. Afonso CT, Silva AL, Fabrini DS, Afonso CT, Côrtes MG, Sant'Anna LL. Risco do uso do eletrocautério em pacientes portadores de adornos metálicos. *ABCD Arq Bras Cir Dig*. 2010;23(3):183-6.
8. Trindade MR, Grazziotin RU, Grazziotin RU. Eletrocirurgia: sistemas mono e bipolar em cirurgia videolaposcópica. *Acta Cir Bras*. 1998;13(3):1-17.
9. Nduka CC, Super PA, Monson JR, Darzi AW. Cause and prevention of electrosurgical injuries in laparoscopy. *J Am Coll Surg*. 1994;179(2):161-70.
10. Hutchisson B, Baird MG, Wagner S. Electrosurgical safety. *AORN J*. 1998;68(5):830-7.
11. Watson DS. New recommendations for prevention of surgical fires. *AORN J*. 2010;91(4):463-9.

Corresponding author:

Daniella de Paiva Almeida Stuchi

R. Padre Vieira, 861/61- Centro - Campinas - São Paulo -
CEP: 13015-301

Phone: 00 55 19 98276-1802

E-mail: danielladepaiva@hotmail.com