

## CONSTITUTIVE MELANIN IN THE CELL WALL OF THE ETIOLOGIC AGENT OF LOBO'S DISEASE

Valeria B.A. TABORDA (1,2), Paulo R.O. TABORDA (1,2) & Michael R. MCGINNIS(3)

### SUMMARY

Lobo's disease is a chronic granulomatous disease caused by the obligate pathogenic fungus, whose cell walls contain constitutive melanin. In contrast, melanin does not occur in the cell walls of *Paracoccidioides brasiliensis* when stained by the Fontana-Masson stain.

**KEYWORDS:** Lobo's disease; Lobomycosis; Melanin; *Paracoccidioides lobo*; *Paracoccidioides brasiliensis*.

### INTRODUCTION

Lobo's disease is a chronic granulomatous mycosis caused by an obligate pathogenic fungus that usually results in indolent cutaneous keloid-like lesions, which are predominantly localized on the ears and legs of humans. The disease has also been reported in dolphins, *Tursiops truncatus* and *Sotalia fluviatilis*, that have been captured in the Atlantic Ocean, Gulf of Mexico, French-Spanish coast, the Brazilian coast and Surinam River estuary<sup>4,9,12</sup>. However, *in vitro* culture has been unsuccessful<sup>11</sup> and experimental animal inoculations have not consistently resulted in infection. Experimental human to human transfers of tissue containing the fungus has also resulted in inconsistent results, regardless the solitary lesion successfully obtained by Borelli through experimental inoculation into the knee of a human volunteer<sup>1</sup>. One case of accidental dolphin to human inoculation remains unclear<sup>12</sup>. The first molecular evidence supporting the agent of Lobo's disease as a member of the Kingdom Fungi has been published<sup>5</sup>. Classified either as *Loboa lobo* or *Paracoccidioides lobo*, the taxonomy of this fungus is currently under review.

Fungal melanins are dark brown to black pigments of high molecular weight formed by enzymatic or anti-oxidative polymerization of phenolic compounds. These occur in the cell wall, as extracellular polymers in the medium around the cells, or both<sup>15</sup>. Pigment production has been associated with fungal virulence, resistance to microbial attack and enhanced survival under environmental stress. They appear to contribute to virulence by protecting the fungal cell against attack by immune effector cells. The role of melanin as an anti-oxidant has been suggested<sup>7,13</sup>. Melanin seems to confer resistance to ionic oxidants produced by macrophages. Melanized cells are less susceptible to killing by

oxygen and nitrogen-derived radicals; and more resistant to fungicidal and fungistatic molecules than nonmelanized cells<sup>3</sup>. Melanized fungi are more resistant to damage caused by UV light, as well as irradiation, x-rays, desiccation and high temperatures<sup>15</sup>.

Fungal melanin and polyphenolic compounds are known to combine with silver salts, been reduced to a black metallic state<sup>8</sup>. In phaeoid fungi, even though some melanin can be detected in hematoxylin-eosin (H&E) stained tissue sections, the Fontana-Masson stain enhances the visualization of this heterogeneous compound<sup>16</sup>. The Warthin-Starry stain is another staining technique that can detect melanin<sup>14</sup>. Unlike the Fontana-Masson method, the Warthin-Starry modified technique does not reduce others molecules, including formalin, iron and lipofuscin<sup>14</sup>.

The purpose of this study was to determine if melanin is present in the cell walls of the etiologic agents of Lobo's disease and paracoccidioidomycosis using the Fontana-Masson stain.

### MATERIAL AND METHODS

Formalin-fixed, paraffin-embedded tissue from twenty human Lobo's disease cases, five culture-proven paracoccidioidomycosis cases, two cryptococcosis cases, and two chromoblastomycosis cases were obtained from the Instituto L. S. Lima (ILSL). Paraffin-embedded tissue from two dolphins having Lobo's disease were provided by University of Texas Medical Branch (UTMB, GA710) and Universidade Federal de Santa Catarina (UFSC, 91-0495). In each case, samples were randomized, serially sectioned, and stained by the H&E, Fontana-Masson, calcofluor white, periodic acid-Schiff (PAS), and Gomori-Grocott's methenamine silver (GMS) methods. The same stainings were done with samples from normal

(1) Dermatologist, Instituto L.S. Lima, Bauru, São Paulo, Brazil

(2) Collaborator, Medical Mycology Research Center at UTMB, Galveston, Texas, U.S.A.

(3) Director, Medical Mycology Research Center, University of Texas Medical Branch, Galveston, Texas, U.S.A.

Correspondence to: Dr. Valeria A. Taborda, R. Azarias Leite 10-38 ap. 82, 17015-210 Bauru, SP, Brazil. E-mail: fungi@blv.com.br

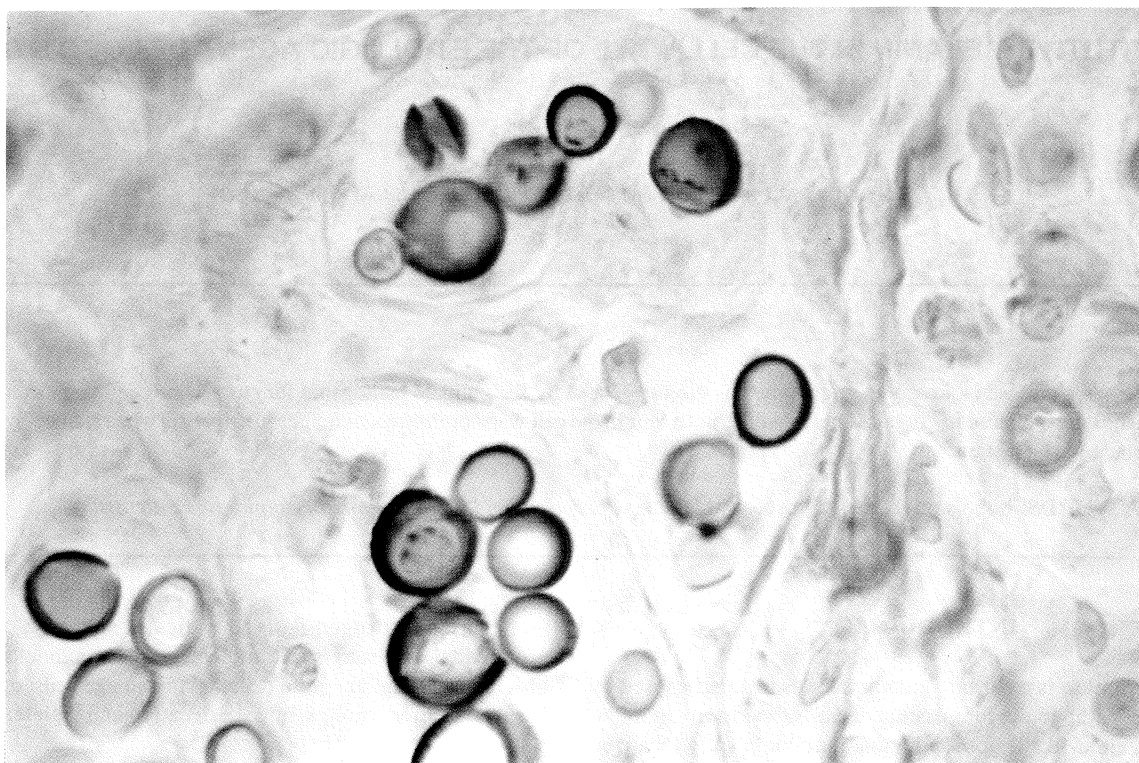


Fig. 1- Lobo's disease: melanin is present in the yeast cell walls of the agent of Lobo's disease (Fontana-Masson stain, x 400)

skin, cryptococcosis and chromoblastomycosis cases to serve as positive controls. Additionally, tissue from paracoccidioidomycosis was used as a negative control. Clinical features including age and sex, lesion location and disease duration were obtained from the clinical charts.

Using conventional light microscopy, the authors independently evaluated the histochemical staining. Because prolonged immersion (beyond 8h) decreases the reaction specificity for melanin, and other silver-reducing objects may be stained black<sup>8</sup>, two equivalent techniques of Fontana-Masson silver staining were done as described elsewhere<sup>2,8</sup>. In essence, they differ by rapid metallic histological staining using the microwave oven or conventional overnight silver bath at 25°C in the dark. Briefly, Fontana silver solution consists of 10% silver nitrate in 100/ml of water. Ammonium hydroxide is slowly added to the 10% silver nitrate solution until a faint opalescence appears. The ammoniated silver nitrate solution is mixed with distilled water, filtered and then stored overnight at 25°C in the dark or by using microwave oven. Tissue sections (5 µm) are placed in xylol, and then passed through a series of alcohol-water exchanges and finally washed in distilled water. Transferred to Fontana silver solution and stored in a covered dish in the dark for 18h. The sections are well washed and fixed in 5% sodium thiosulphate for 5 min. Washed in tap water for 5 min, counterstained with 1% neutral red for 2 min, and quickly rinsed with distilled water. Finally, dehydrated, cleared and mounted with permount<sup>8</sup>.

## RESULTS

The 20 Lobo's disease patients ranged in age from 20 to 78 years old (mean age, 51.95 y.o.). There was only 1 female. Most of the lesions were situated on the ears (10/20) and legs (5/20). The lesions were classified as localized in 16 cases (80%), multifocal in 3 cases and disseminated in 1 case. All the 20 Lobo's disease cases (localized, multifocal and disseminated) had demonstrable melanin in the yeast cell walls by either variant technique of Fontana-Masson staining. Representative negative controls were seen. No melanin was detectable in the yeast cell walls of *P. brasiliensis*. Concomitantly, in all of these specimens there was evident epidermal positive staining for melanin in the normal skin basal layers. The group of 5 paracoccidioidomycosis control cases (3 males and 2 females; age 36 to 56 years) presented cutaneous lesion (3 cases), oral mucosal lesion (1 case), and cervical lymph node lesion (1 case). Positive controls were confirmed by Fontana-Masson positive-stained fungal cell walls of 2 cryptococcosis and 2 chromoblastomycosis cases.

## DISCUSSION

Lobo's disease can be classified into major clinical types, monomorphic (keloidform, verruciform, macular, gomatous, ulcerative or infiltrative) and polymorphic (combination of monomorphic forms). The cutaneous lesions can be localized (solitary or multiple), multifocal or disseminated. Lesions remain

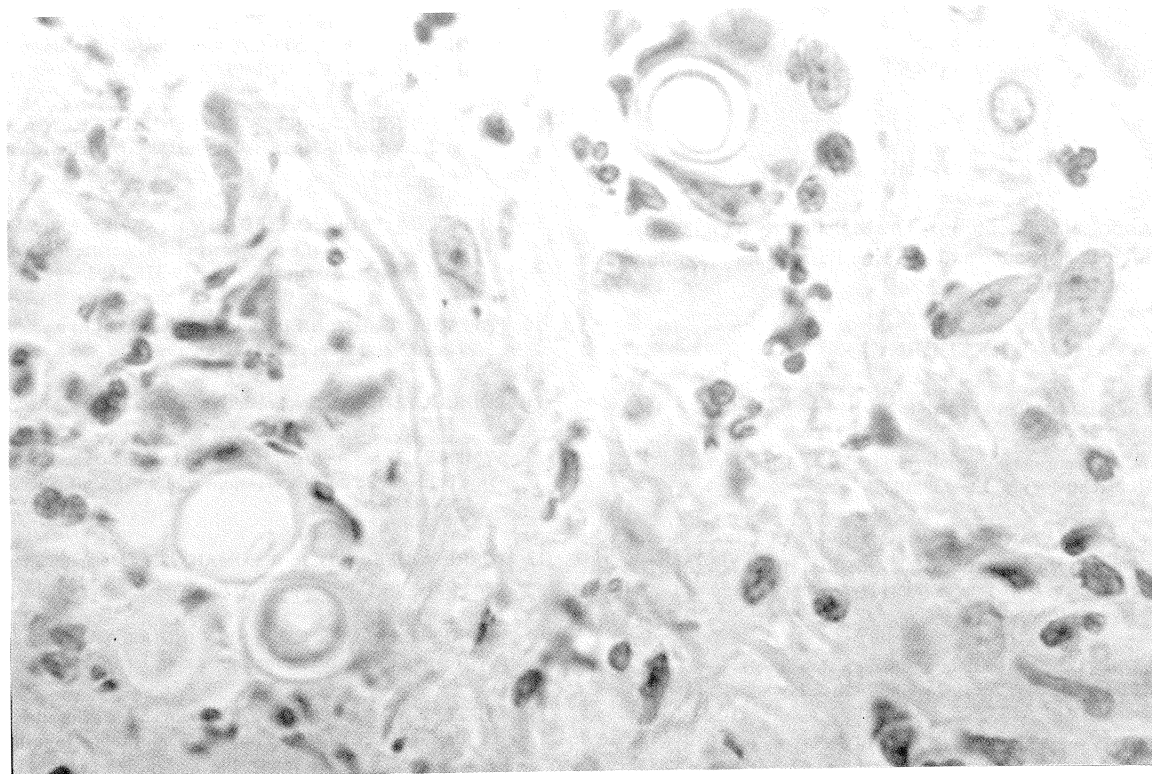


Fig. 2- Paracoccidioidomycosis: melanin is absent in the cell walls of *P. brasiliensis* (Fontana-Masson stain, x 400)

localized if, they are restricted to one area; multifocal if more than one area or anatomic region is involved, and disseminated if several different sites are involved. Regarding the lesions, they can be either mild (single lesion, less than 5 cm), moderate (several lesions, between 6-15 cm), severe lesions (extense, more than 16 cm), or a combination of these lesion types.

The agent of Lobo's disease forms numerous globose-to-lemon-shaped-to-elliptical cells, 9 to 10  $\mu$ m in diameter having thick cell walls in tissue. Adjacent cells have a narrow tubular connection or isthmus between them, giving the appearance of a string of beads. This catenulate configuration, or pseudohyphae, is a mycologic hallmark for Lobo's disease. The demonstration of melanin in the cell walls requires Fontana-Masson staining because the fungal cells clinical material and tissue sections are hyaline. The fungus does not reflect the concept of phaeoid, which refers to hyphae, conidia or both that are naturally darkly colored, pale brown to black owing to the presence of melanin. PAPPAGIANIS & AJELLO (1994)<sup>10</sup> feel that the term dematiaceous is a mycologic misnomer because its earliest useage refers to fungi with floccose (wooly) hyphae. These authors recommend the use of the term phaeoid instead of dematiaceous when referring to darkly colored fungi and their structures.

Melanin is always present in the cell walls of the vegetative form of the agent of Lobo's disease. The melanin is not evident to the un-aided eye. A similar situation occurs with *Cryptococcus*

*neoformans*. This basidiomycete always has constitutive melanin, which is not evident without histological stainings. Additionally, KWON-CHUNG *et al.* (1981) demonstrated that the Fontana-Masson silver stain did not detect presence of melanin in the yeast cell wall of *P. brasiliensis*<sup>8</sup>. Phylogenetically related groups with similar tissue forms lacking melanin, such as the ascomycete family Onygenaceae (*Histoplasma capsulatum*, *Coccidioides immitis*, *Blastomyces dermatitidis*, *Emmonsia parva* and *Paracoccidioides brasiliensis*)<sup>6</sup> can be contrasted with the agent of Lobo's disease owing to its constitutive melanin<sup>8</sup>.

Further studies including other phylogenetic related ascomycetes of the family Onygenaceae are being conducted. Possible roles for constitutive melanin in the pathogenesis of Lobo's disease and how infection duration can influence the levels of melanin production in Lobo's disease remains to be determined.

## RESUMO

### Melanina constitutiva na parede celular do agente da doença de Jorge Lobo

Doença de Jorge Lobo é uma doença crônica granulomatosa causada por um fungo obrigatório, em cuja parede celular demonstra-se a presença de melanina constitutiva. Ao contrário, no *P. brasiliensis*, e em descrições de outros ascomicetos

filogeneticamente relacionados da família *Onygenaceae*, a melanina não é detectável pela técnica de coloração histoquímica de Fontana-Masson.

### ACKNOWLEDGEMENTS

The authors are indebted to Dr. Matsumoto Kimura for the histopathological assistance and to Lester Pasarell for his comments during this investigation.

### REFERENCES

1. BORELLI, D. - Lobomycosis experimental. **Derm. venez.**, 3: 72-82, 1962.
2. BRINN, N.T. - Rapid metallic histological staining using the microwave oven. **J. Histotechnology**, 6: 125-129, 1983.
3. COOPER, C.R. & SZANISZLO, P.J. - Melanin as a virulence factor in dematiaceous pathogenic fungi. In: BOSSCHE, H.V., STEVENS, D.A. & ODDS, F.C., ed. **Host-fungus interplay**. Bethesda, National Foundation for Infectious Diseases, 1997. p. 81-93.
4. COWAN, D.F. - Lobo's disease in a bottlenose dolphin (*Tursiops truncatus*) from Matagorda Bay, Texas. **J. Wildlife Dis.**, 29: 488-489, 1993.
5. HAUBOLD, E.M.; ARONSON, J.F.; COWAN, D.F.; MCGINNIS, M.R.; COOPER, C.R. - Isolation of fungal rDNA from bottlenose dolphin skin infected with *Loboa loboi*. **Med. Mycol.**, 36: 263-267, 1998.
6. HOOG, G.S. de & GUARRO, J. - **Atlas of Clinical Fungi**. The Netherlands, Centraalbureau voor Schimmelcultures Baarn and Delft, 1995. p.1-15.
7. JACOBSON, E.S. & TINNELL, S.B. - Antioxidant function of fungal melanin. **J. Bact.**, 175: 7102-7104, 1993.
8. KWON-CHUNG, K.J.; HILL, W.B. & BENNETT, J.E. - New, special stain for histopathological diagnosis of cryptococcosis. **J. clin. Microbiol.**, 13: 383-387, 1981.
9. LOPES, P.C.S.; PAULA, G.S.; BOTH, M.C.; XAVIER, F.M. & SCARAMELLO, A.C. - First case of lobomycosis in a bottlenose dolphin from Southern Brazil. **Marine Mammal Sci.**, 9: 329-331, 1993.
10. PAPPAGIANIS, D. & AJELLO, L. - Dematiaceous - a mycologic misnomer? **J. med. vet. Mycol.**, 32: 319-321, 1994.
11. RODRIGUEZ-TORO, G. - Lobomycosis. **Int. J. Derm.**, 32: 324-332, 1993.
12. SYMMERS, W.S. - A possible case of Lobo's disease acquired in Europe from a bottle-nosed dolphin (*Tursiops truncatus*). **Bull. Soc. Path. exot.**, 77: 777-784, 1983.
13. TORRES-GUERRERO, H. & EDMAN, J.C. - Melanin-deficient mutants of *Cryptococcus neoformans*. **J. med. vet. Mycol.**, 32: 303-313, 1994.
14. WARKEL, R.L.; LUNA, L.G. & HELWING, E.B. - A modified Warthin-Starry procedure at low pH for melanin. **Amer. J. clin. Path.**, 73: 812-815, 1980.
15. WHEELER, M.H. & BELL, A.A. - Melanins and their importance in pathogenic fungi. In: MCGINNIS, M.R., ed. **Current topics in medical mycology**. New York, Springer-Verlag, 1987. v.2, p. 338-387.
16. WOOD, C. & RUSSEL-BEL, B. - Characterization of pigmented fungi by melanin staining. **Amer. J. Dermatopath.**, 5: 77-81, 1993.

Received: 11 August 1998

Accepted: 17 November 1998