

ORIGINAL ARTICLE

INVASIVE ENTERITIS BY *STRONGYLOIDES STERCORALIS* PRESENTING AS ACUTE ABDOMINAL DISTRESS UNDER CORTICOSTEROID THERAPY

Maria Aparecida Marchesan Rodrigues, Raquel Cardoso Fróes, Alexandre Anefalos and Shoiti Kobayasi

RHCFAP/3044

RODRIGUES MAM et al. - Invasive enteritis by *Strongyloides Stercoralis* presenting as acute abdominal distress under corticosteroid therapy. **Rev. Hosp. Clín. Fac. Med. S. Paulo** 56(4):103-106, 2001.

Overwhelming helminthiasis is still a problem in endemic areas, especially in immunocompromised patients. We report a case of invasive intestinal strongyloidiasis that was clinically expressed as acute abdominal distress in a 73-year-old man from São Paulo who had been receiving methylprednisone, 20 mg/day, for one year for osteoarthritis. A surgical specimen from the ileum revealed invasive enteritis with severe infestation by *Strongyloides stercoralis*. The patient died of sepsis 6 days after surgery. The possibility of invasive strongyloidiasis should be considered in the differential diagnosis of acute abdominal distress in patients undergoing immunosuppressive therapy.

DESCRIPTORS: *Strongyloides stercoralis*. Invasive enteritis. Acute abdominal distress. Corticosteroid therapy.

Strongyloidiasis is a worldwide parasitic disease, endemic in tropical countries like Brazil^{4,16,17}. The great majority of cases are asymptomatic, but when symptoms develop, patients may present mild abdominal pain, nausea, vomiting, and watery diarrhea. Poor personal hygiene, cutaneous rashes, and eosinophilia are important clues for the diagnosis. However negative stool cultures or eosinopenia do not rule out the diagnosis and under severe conditions may point to the disseminated form of strongyloidiasis^{4,8,18}.

This report presents a patient who was undergoing corticosteroid therapy for osteoarthritis and who developed a small bowel obstruction due to

Strongyloides stercoralis hyperinfection.

CASE REPORT

A 73-year-old man from São Paulo came to the emergency room with a 4-day history of cramping abdominal pain, nausea, vomiting, and watery diarrhea. On examination, he was afebrile with a markedly tender, distended abdomen with rebound tenderness and guarding. His white blood cell count

was 8 200 / mm³, and no eosinophils were detected on peripheral smear. An abdominal roentgenogram revealed air-filled dilated loops of small bowel consistent with small bowel obstruction. He underwent exploratory laparotomy that showed an inflamed section of distal ileum with a narrowed lumen adhered to the retroperitoneum. Resection of the affected segment was performed with construction of an ileocolic anastomosis. The patient subsequently developed sepsis with blood cultures positive for anaerobic bacteria and died on the sixth postoperative day. The histopathologic examination of the surgical specimen revealed invasive enteritis with severe infestation by

From the Division of Gastroenterology, Botucatu Medical School, University of the State of São Paulo (UNESP).

Strongyloides stercoralis. Many larval forms were found within the crypts and invading the deeper layers of the intestinal wall with inflammation and focal granulomas (Fig. 1).

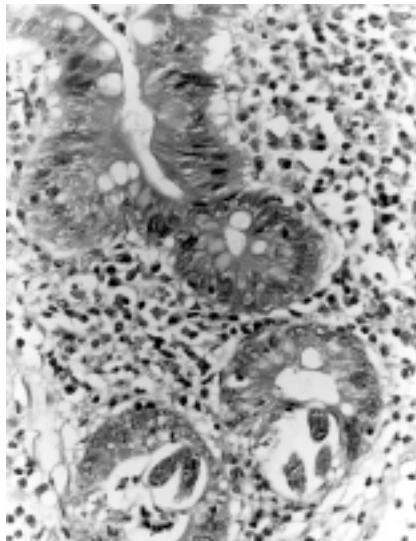


Figure 1 - Enteritis by *Strongyloides stercoralis*. Larval forms invading the crypts of the mucosa.

Retrospective analysis of the patient's records, which were not available at the emergency room, revealed that he had been receiving treatment with methylprednisone, 20 mg/day, for one year for osteoarthritis.

DISCUSSION

Even though *Strongyloides stercoralis* is an intestinal nematode, infected patients rarely present with symptoms from the gastrointestinal tract, such as intestinal obstruction or

acute abdominal distress^{2,15,20}. Severe gastrointestinal symptoms due to increased worm burden occur in the hyperinfection syndrome^{3,5,7}. This pathologic condition results from larvae that become infective within the intestine¹⁴. Predisposing factors for this overwhelming autoinfection include immunosuppression^{11,18} — particularly impaired cell mediated immunity, steroid^{5,8}, and other immunosuppressive therapy — severe malnutrition or alcoholism, leukemia, lymphoma^{13,19}, and the expanding population of HIV-infected patients¹². In this condition, filariform larvae invade the intestinal walls and may spread through lymphatic and hematogenic pathways to distant organs such as the liver and biliary tract⁹, pancreas, lungs, and the central nervous system. This hyperinfection is usually accompanied by bacteremia with enteric organisms, leading to fatal septicemia^{2,10}.

The reported case is from an elderly patient who was undergoing chronic corticosteroid therapy for osteoarthritis who developed signs and symptoms of small bowel obstruction. The information about his treatment with corticosteroid was not available when he was admitted at the emergency room. Retrospective analysis of the patient's records revealed that he was under investigation for anemia and recurrent diarrhea. The negative results for the parasitologic stool examinations did not rule out the possibility of parasitic infection, and the chronic use of corticosteroid should have prompted

prophylactic treatment with thiabendazole. With this panel of clinical data and the development of signs and symptoms of acute abdominal distress, the hypothesis of hyperinfection syndrome by *Strongyloides stercoralis* would have led to a course of treatment that did not include surgery.

Boken et al.⁶ reported a case of *Strongyloides stercoralis* hyperinfection in a patient who was treated successfully with rectal administration of thiabendazole. Undiluted thiabendazole suspension (500 mg/5 mL) was given by retention enema for 14 days (1.5 g every 12 hours) because severe upper intestinal obstruction precluded oral administration.

In the present case, the diagnosis of *Strongyloides stercoralis* hyperinfection was made only after surgery by pathological examination of the surgical specimen and did not prevent subsequent complications that led to the patient's death. Thus, this report highlights the importance of the preoperative evaluation of co-morbid states, even under emergency conditions, since they may lead to life-threatening complications.

In conclusion, the possibility of *Strongyloides stercoralis* hyperinfection should be considered in the differential diagnosis of acute abdominal distress in patients receiving cortisone analogs and other immunosuppressive drugs. Timely appropriate therapy before the development of significant abdominal complications such as perforation and peritonitis would be life-saving.

RESUMO

RHCFAF/3044

RODRIGUES MAM e col. - Estrongiloidíase intestinal invasiva como causa de abdome agudo, em paciente submetido à corticoterapia. **Rev. Hosp. Clín. Fac. Med. S. Paulo** 56(4):103-106, 2001.

A síndrome de hiperinfecção por *Strongyloides stercoralis* ainda constitui problema em áreas endêmicas, especialmente em pacientes portadores de imunossupressão. Os autores relatam um caso de estrongiloidíase intestinal

invasiva, que se apresentou clinicamente com quadro de abdome agudo obstrutivo, em um paciente masculino de 73 anos, que estava recebendo metilprednisona 20 mg/dia há um ano devido à osteoartrite. O exame anatomopatológico de segmento do íleo demonstrou enterite invasiva com intensa infestação por *Strongyloides stercoralis*. O paciente evoluiu para óbito com quadro de septicemia, 6 dias após a intervenção cirúrgica. O presente caso destaca a importância da avaliação pré-operatória de estados co-mór-

bidos, mesmo em condições de urgência, visto que podem comprometer o êxito do tratamento cirúrgico e a vida do paciente. A possibilidade de estrongiloidíase intestinal invasiva deve ser considerada no diagnóstico diferencial dos quadros de abdome agudo em pacientes submetidos à terapêutica imunossupressora.

DESCRITORES: *Strongyloides stercoralis*. Enterite invasiva. Abdome agudo. Corticoterapia

REFERENCES

1. AYDIN H, DOPPL W, BATTMANN A et al. - Opportunistic *Strongyloides stercoralis* hyperinfection in lymphoma patients undergoing chemotherapy and/or radiotherapy. Report of a case and review of the literature. **Acta Oncol** 1994; **33**: 78-80.
2. BANNON JP, FATER M & SOLIT R - Intestinal ileus secondary to *Strongyloides stercoralis* infection: case report and review of the literature. **Am Surg** 1995; **61**: 377-80.
3. BEECHING NJ & GILL GV - Sub-acute intestinal obstruction by *Strongyloides stercoralis* (letter). **J Infect** 1996; **32**: 170.
4. BERK SL, VERGUESE A, ALVAREZ S et al. - Clinical and epidemiological features of strongyloidiasis. **Arch Int Med** 1987; **147**: 1257-61.
5. BIRCK R et al. - Chronic recurrent subileus due to *Strongyloides stercoralis* infection under immunosuppressive therapy **Dtsch Med Wochenschr** 1996; **121**: 723-6.
6. BOKEN DJ, LEONI PA & PREHEIM LC - Treatment of *Strongyloides stercoralis* hyperinfection syndrome with thiabendazole administered per rectum. **Clin Infect Dis** 1993; **16**: 123-6.
7. CHAVES FR, CARVALHAL SS & MORAES A M - Estrongiloidíase. Caso fatal por peritonite secundária à perfuração intestinal. **Ped Mod** 1986; **21**: 39-42.
8. CRUZ T, REBOUÇAS G & ROCHA H - Fatal strongyloidiasis in patients receiving corticosteroids. **N Engl J Med** 1966; **275**: 1093-96.
9. DELAROCQUE AE et al. - Biliary obstruction resulting from *Strongyloides stercoralis* infection. Report of a case. **Gut** 1994; **35**: 705-6.
10. DePAOLA D - Patologia da estrongiloidíase. **Bol Cent Est Hosp Serv Est** 1962.; **14**: 3-98.
11. DEVAULT GA Jr. et al. - Opportunistic infections with *Strongyloides stercoralis* in renal transplantation. **Rev Infect Dis** 1990; **12**: 653-71.
12. DIAS RM et al. - Occurrence of *Strongyloides stercoralis* in patients with acquired immunodeficiency syndrome (AIDS). **Rev Inst Med Trop Sao Paulo** 1992; **34**: 15-7.

13. GENTA RM, MILES P & FIELDS K - Opportunistic *Strongyloides stercoralis* infection in lymphoma patients: report of a case and review of the literature. **Cancer** 1989; **63**: 1407-11.
14. GROVE DI - Strongyloidiasis. In: WARREN K & MAHMOUD A - **Tropical and Geographical Medicine**. 2nd ed. New York, Mc-Hill, 1990. p 393-399.
15. LINTERMANS JP - Fatal peritonitis, an unusual complication of *Strongyloides stercoralis* infestation. **Clin Pediatr** 1975; **14**: 974-75.
16. MACHADO ER & COSTA-CRUZ JM - *Strongyloides stercoralis* and other enteroparasites in children at Uberlândia city, state of Minas Gerais, Brazil. **Mem Inst Oswaldo Cruz** 1998; **93**: 161-4.
17. PIRES ML & DREYER G - The importance of *Strongyloides stercoralis* revisited. **Rev Hosp Clin Fac Med S Paulo** 1993; **48**: 175-82.
18. POWELL RW, MOSS JP, NAGAR D et al. - Strongyloidiasis in immunosuppressed hosts. **Arch Intern Med** 1980; **140**: 1061- 63.
19. SANDLUND JT, KAUFFMAN W & FLYNN PM - *Strongyloides stercoralis* infection mimicking relapse in a child with small noncleaved cell lymphoma. **Am J Clin Oncol** 1997; **20**: 215-6.
20. SMITH SB et al. - Fatal disseminated strongyloidiasis presenting as acute abdominal distress in an urban child. **J Pediatr** 1977; **91**: 607- 9.

Received for publication on August 25, 2000.