

Tyzzeria boae n. sp., (Apicomplexa: Eimeriidae), a New Coccidium from the Kidney of the Snake *Boa constrictor constrictor* (Serpentes: Boidae)

Ralph Lainson, Ilan Paperna*

Seção de Parasitologia, Instituto Evandro Chagas, Caixa Postal 691, 66017-970 Belém, PA, Brasil *Faculty of Agriculture, The Hebrew University of Jerusalem, P.O. Box 12, Rehovot 76-100, Israel

A new species of *Tyzzeria* is described from the kidney of the snake *Boa constrictor constrictor* Linnaeus, from the State of Pará, north Brazil. Oocysts from the cloacal contents matured in eight days, at approximately 24°C. They measured 19.0 x 18.0 (15.0 x 15.0 - 22.5 x 21.5) µm, shape-index (length/width) 1.0 (1.0 - 1.1). The oocyst wall is of an extremely delicate single, colourless layer, with no micropyle. Division of the oocyst contents into the 8 naked sporozoites leaves a bulky, spherical oocyst residuum averaging 15.5 x 14.8 (13.5 x 13.5 - 18.5 x 17.5) µm: the sporozoites measure an average of 11.0 x 1.8 (8.5 x 1.25 - 12.5 x 2.0) µm, and possess both anterior and posterior refractile bodies. *Tyzzeria boae* n.sp. is unique among the recorded species of the genus by virtue of its development in the epithelial cells of the distal convoluted tubules and collecting tubules of the kidney: stages in the merogony and gametogony of the parasite are described and figured.

Key words: Apicomplexa - Eimeriidae - *Tyzzeria boae* n.sp. - Serpentes - *Boa constrictor constrictor* - coccidia - snake - kidney - Brazil

Fresh, crush preparations of kidney tissue from a juvenile specimen of the boid snake *Boa constrictor constrictor* revealed what appeared to be the immature oocysts of a coccidial parasite, and similar cysts were also found in the cloacal contents. Subsequent sporulation showed these to be the oocysts of a hitherto undescribed species of the genus *Tyzzeria* Allen, 1936, described below.

MATERIALS AND METHODS

The infected snake was captured in an unspecified locality in the State of Pará, and estimated to be some three-four months old. It was fed, twenty-six days prior to the present observations, with the tissues of a lizard (*Ameiva ameiva*) heavily infected with a *Besnoitia* species, during some unsuccessful attempts to discover the definitive host of that parasite (Lainson & Paperna, unpublished observations).

As blood films of the snake had shown abundant intraerythrocytic gametocytes of a *Hepatozoon* species, we examined fresh squash preparations of the liver, spleen, lung and kidney in a search for the tissue stages of that parasite. In addition, impression smears of these tissues were rapidly air-dried, fixed in aqueous Bouin's fluid and stained

by a modified Giemsa method (Lainson 1958). Pieces of the organs were fixed in 10.0% buffered formol-saline, for histology.

Following discovery of the coccidial oocysts in the kidney, small pieces of this organ were triturated in 2.0% (w/v) aqueous potassium dichromate solution (K₂Cr₂O₇), placed in thin layers in loosely covered Petri-dishes and examined daily: similar treatment was given to the contents of the cloaca. Faecal material from various parts of the intestine and bile from the gall-bladder were devoid of coccidial oocysts and therefore discarded. In view of the exclusive development of other species of *Tyzzeria* in the small intestine, however, a careful search for parasites was made in both fresh and stained preparations of scrapings of the epithelium at various points along the intestine.

Twenty-five mature oocysts of the new coccidium were measured, using an ocular micrometer, x 8 eyepieces and x 100 neofluar objective. Line-drawings were the result of direct observations made while measuring the oocysts, and reference to photomicrographs prepared using a Zeiss Photomicroscope III and Kodak TMX 402 film.

All measurements are in micrometers (µm) and are given as means, with the range in parentheses, followed by the shape-index (ratio of length/width).

RESULTS

Stages in the merogony and gametogony of the new *Tyzzeria* species were found only in the smears

Supported by grant 035693 from the Wellcome Trust, London (RL).

Received 28 March 1994

Accepted 5 July 1994

and sections of kidney tissue. Occasional cysts containing the cystozoites of the *Hepatozoon* sp., in the liver were morphologically readily distinguished, and the intestine was totally devoid of coccidial parasites.

Tyzzeria boae n.sp.
(Figs 1-31)

Diagnosis: oocysts spherical to sub-spherical, 19.0 x 18.0 (15.0 x 15.0 - 22.5 x 21.5), shape-index 1.0 (1.0 - 1.1). The oocyst wall is colourless and extremely delicate, that of the mature oocyst becoming almost invisible: there is no micropyle. In fresh, crush preparations of kidney tissue the zygote entirely fills the oocyst, but there is a small space between it and the oocyst wall in immature parasites from the cloacal contents. The eight sporozoites are at first arranged close to one another, rather like a hand of bananas but, in older oocysts, frequently become irregularly scattered.

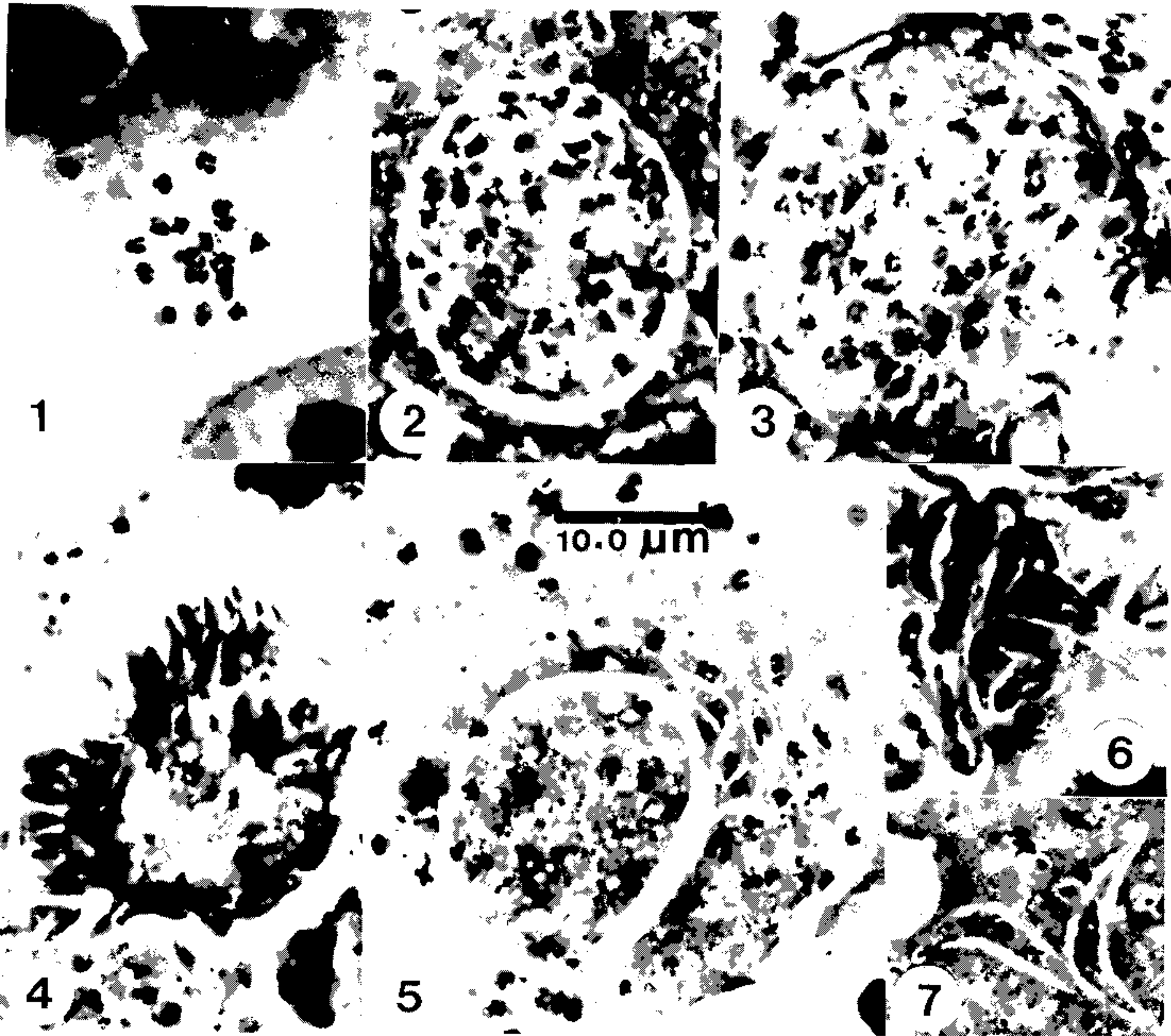
They have an average measurement of 11.0 x 1.8 (8.5 x 1.25 - 12.5 x 2.0) and possess two refractile bodies lying anterior and posterior to the nucleus. An optically dense tip to the more pointed end of the sporozoite is presumably formed by the conoid and related ultrastructures. There is a bulky, spherical oocyst residuum of granules and globules, averaging 15.5 x 14.8 (13.5 x 13.5 - 18.5 x 17.5), and no polar bodies.

Type host: the common boa-constrictor, *Boa c. constrictor* Linn. (Serpentes: Boidae).

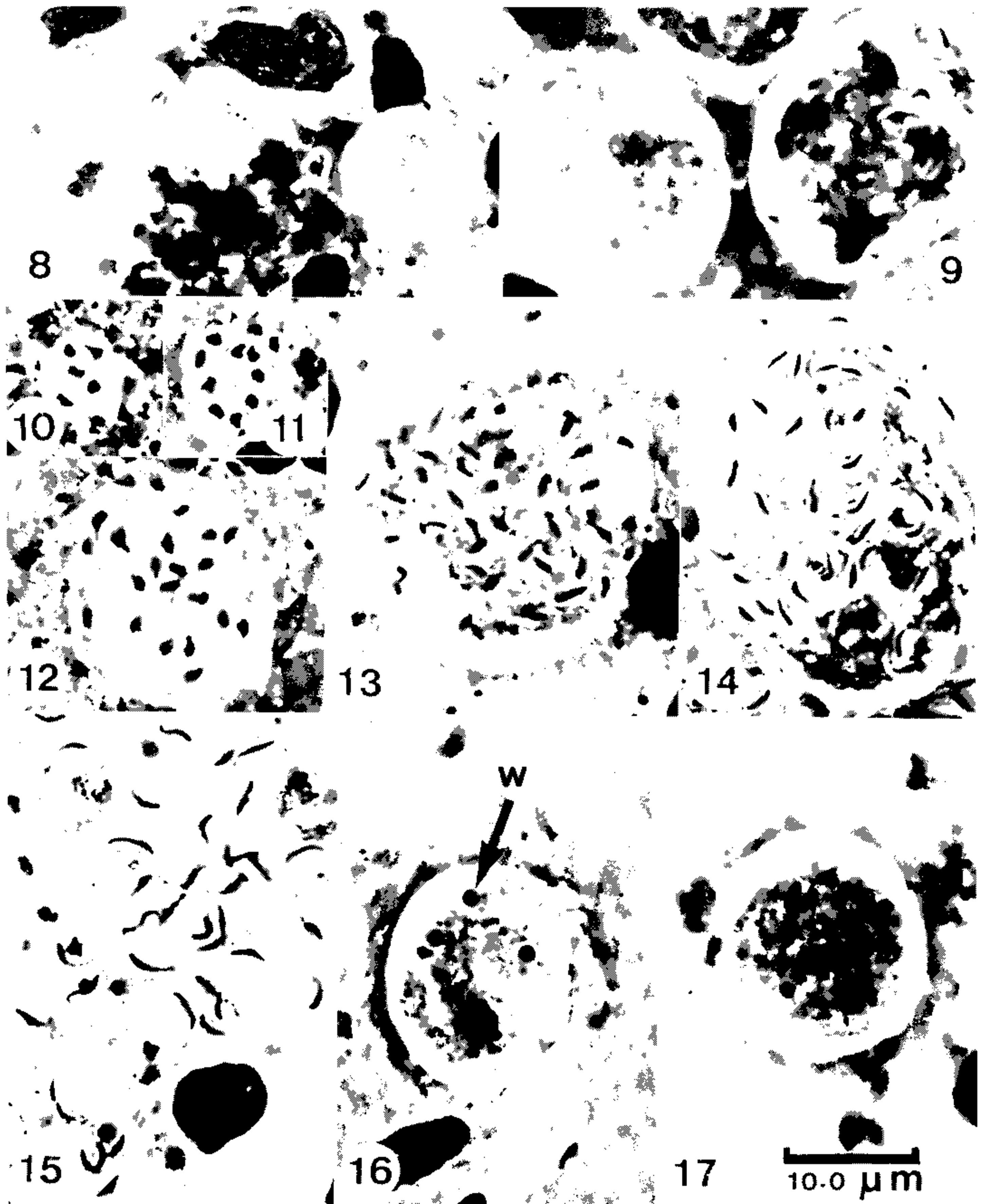
Location in host: the epithelial cells of the distal convoluted tubules and the collecting tubules of the kidneys.

Sporulation: exogenous: oocysts mature in eight days at 24°C.

Type material: oocysts in 10.0% formol-saline, and histological sections and smears of the kidney, held in the Department of Parasitology, Instituto Evandro Chagas, Belém, Pará, Brazil.



Tyzzeria boae n.sp., a coccidial parasite in the kidney tubules of the snake *Boa constrictor constrictor* (Figs 1-7): impression smears of kidney tissue, fixed in Bouin's fluid and stained by Giemsa's method. Developing and mature meronts: note the production of meronts with merozoites of differing size (4-7).



Tyzzeria boae n.sp., in *Boa constrictor constrictor*. Stained impression smears of kidney tissue, showing stages in gametogony. Fig 8: young macrogamonts. Fig 9: macrogamete (left) and mature microgamont (right). Figs 10-13: developing microgamonts. Fig 14: mature microgamont with microgametes and a large residual body. Fig 15: free microgametes. Figs 16-17: zygotes: note the prominent oocyst wall-forming bodies (W).

Repository No Boa 01/11.01.93.

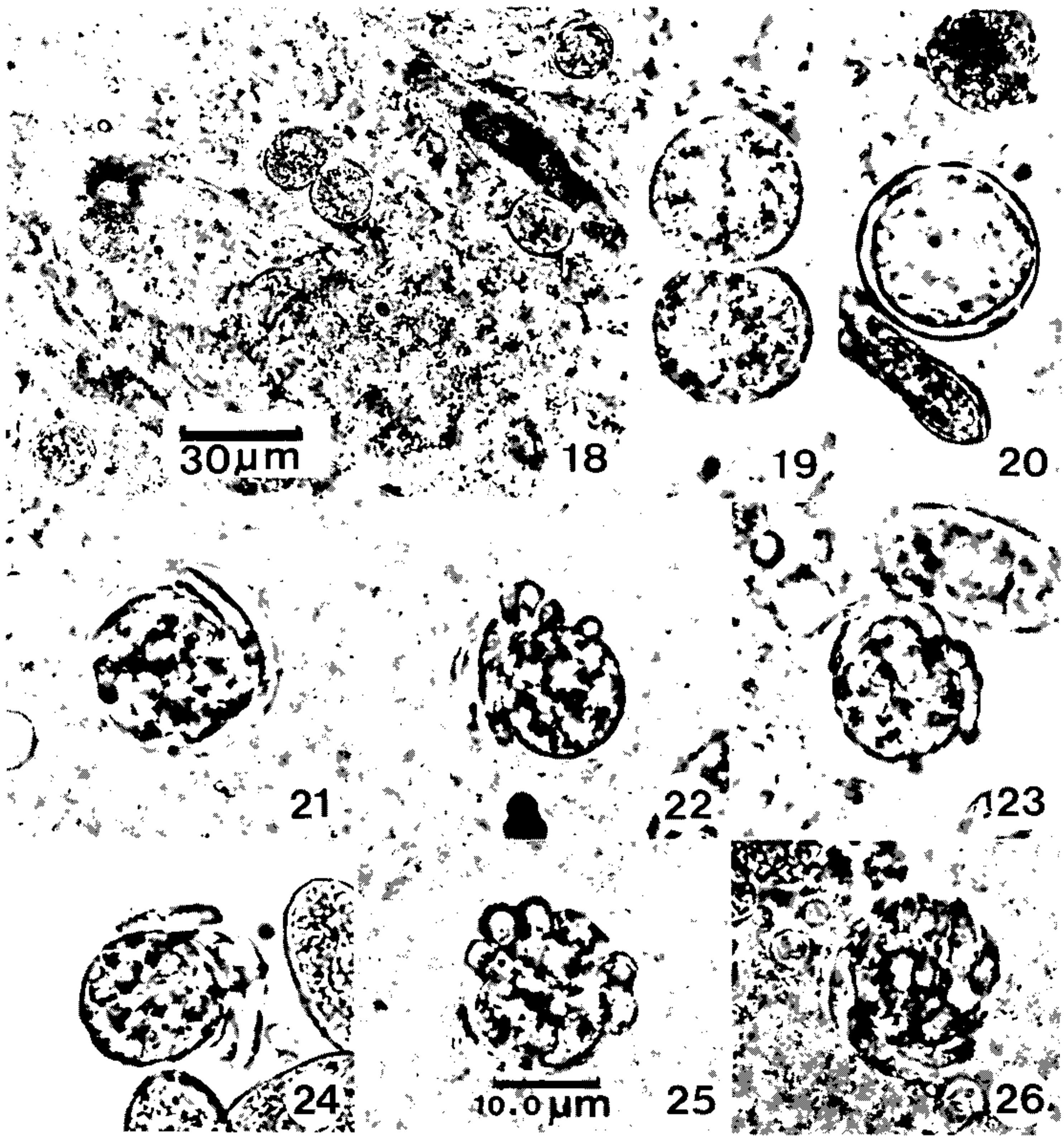
Type locality: State of Pará, north Brazil.

Prevalence: uncertain. No infection was detected in four other young boas examined.

Pathogenicity: the kidneys of the infected snake were considerably enlarged, compared with those of uninfected specimens of about the same age.

Many sections of the distal tubules showed every epithelial cell to be occupied by one or more parasites, and it remains highly likely that kidney function was impaired.

Etymology: the specific name of *T. boae* n.sp., is derived from the generic name of the reptilian host, *Boa*.



Tyzzeria boae n.sp., in *Boa constrictor constrictor*. Living stages of sporogony in crush preparations of kidney tissue and cloacal contents. Figs 18-19: low and high power view of zygotes in kidney tissue: note that the parasite entirely fills the oocyst. Fig 20: immature oocyst in the cloacal contents, three days after incubation in 2.0% $K_2Cr_2O_7$. The contents of the oocyst have now condensed away from the oocyst wall. Figs 21-26: sporulated oocysts, after eight days in $K_2Cr_2O_7$: note the eight sporozoites and large, spherical residual body.

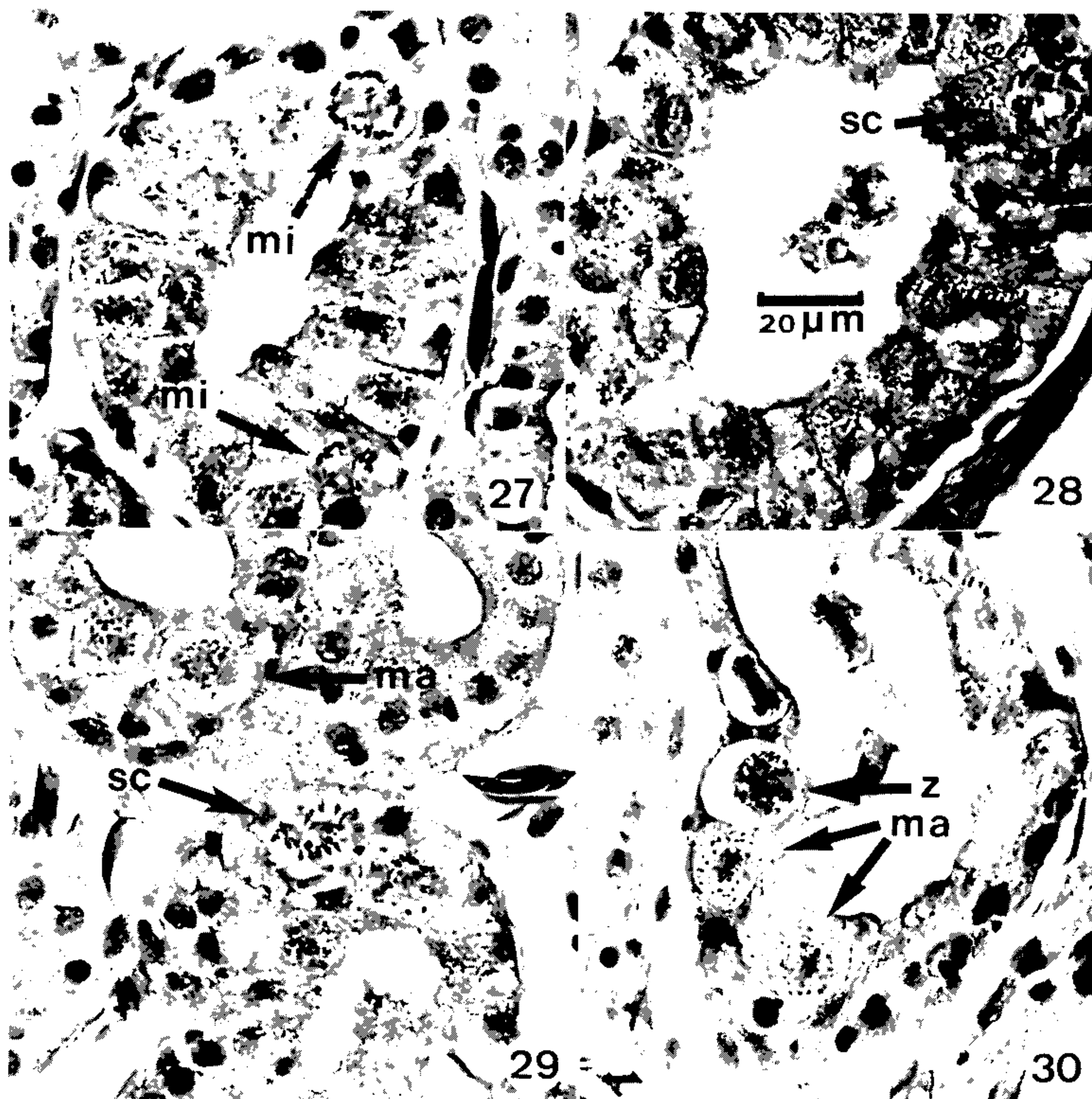
The tissue stages: merogony and gametogony.

These stages were most commonly located in the epithelial cells of the distal convoluted tubules, and less frequently in those of the collecting tubules. Within the epithelial cells, they are found on the lumen side of the host cell nucleus.

Two different types of meronts were found in the stained smears. Larger ones, reaching up to 30.0 in diameter and producing from 50-100 or more small, tear-shaped merozoites of about 5.0 x 1.75 (Figs 1-5); and smaller ones, of about 10.0 -

20.0, giving rise to a small number of larger and more slender merozoites of approximately 12.5 x 2.5 (Figs 6-7). Developing meronts are readily distinguished from growing microgamonts by their bulky and diffuse nuclei which are composed of a small number of chromatin granules (Figs 1-3).

Development of the microgamonts and macrogamonts is typical of that of other members of the Eimeriidae. The former are differentiated from meronts by their angular and densely staining nuclei (Figs 10-12). They averaged 18.6 x 15.8,



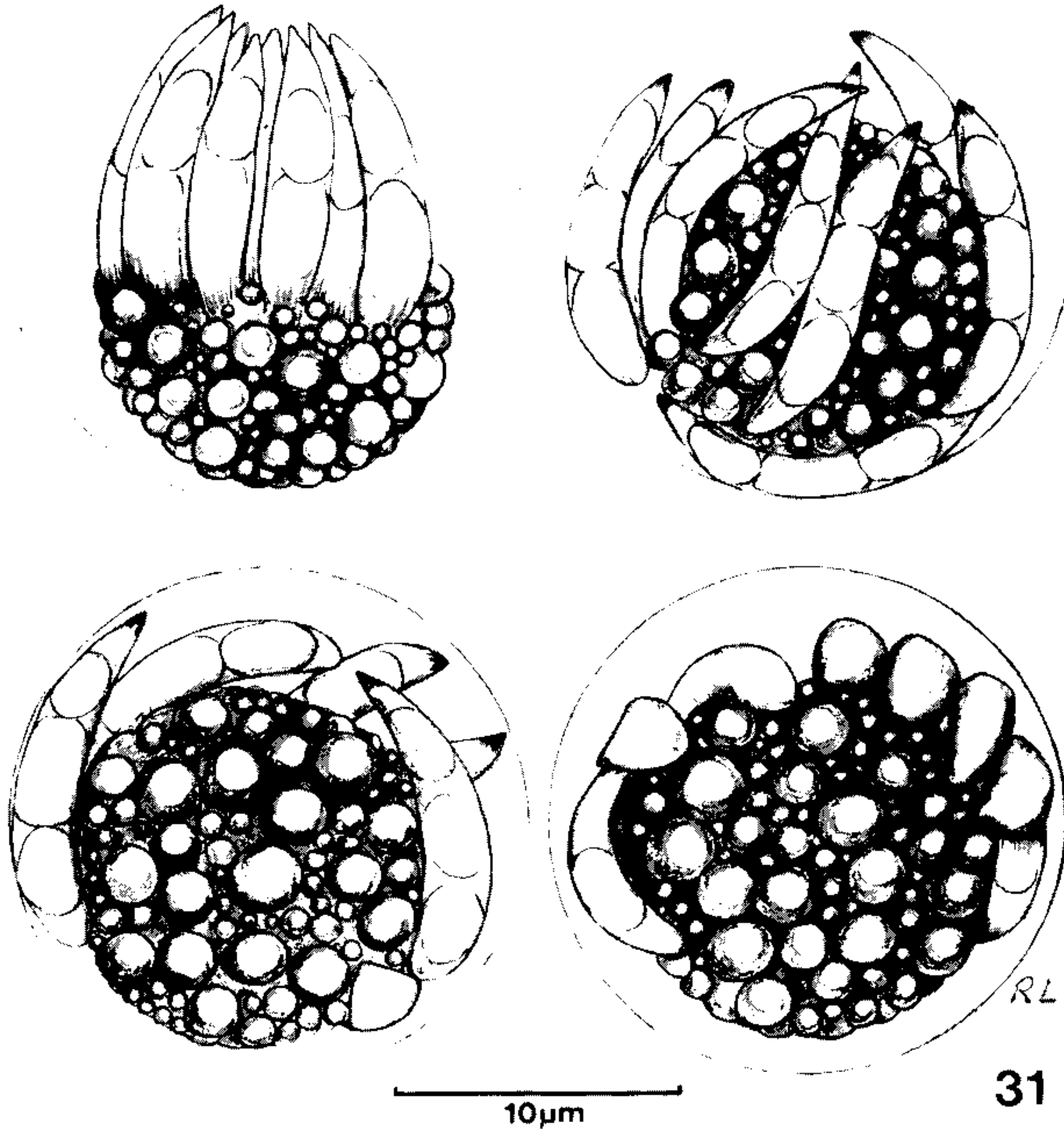
Tyzzeria boae n.sp., in *Boa constrictor constrictor*. Histological sections of kidney, showing the large number of developing meronts (sc), microgamonts (mi), macrogamonts and macrogametes (ma) and zygotes (z) in the distal convoluted tubules (Figs 27-29) and the collecting tubules (Fig. 30). Note the shedding of zygotes (immature oocysts) into the lumen of the convoluted tubule.

as measured in smears, with a range of 12.5 - 30.0 x 12.5 - 20.0: their normal shape is probably spherical to sub-spherical (Figs 13 and 27) but they are frequently grossly distorted in smears. The comma-shaped microgametes measure about 4.0 x 1.0 (Fig. 15): they presumably possess the typically paired flagella of the eimeriids, but these could not be clearly detected in the stained smears. Matubayasi (1937) described bi-flagellated microgametes of *T. natrix*, but found that the flagella stained with great difficulty. With shedding of the microgametes, there is left a bulky residual body (Figs 9 and 14).

Development of the macrogamonts calls for no

special comment. Very young forms are distinguished by their delicately staining, pale blue cytoplasm and diffuse, pale pink nucleus (Fig. 8). Mature macrogametes are spherical to sub-spherical and range from 15.0 - 22.0 x 14.0 - 20.0 (Figs 9 and 30). Their cytoplasm contains numerous granules and a diffuse chromatin mass with a conspicuous karyosome.

The fertilized macrogamete (Figs 16-17), or zygote, is recognisable by its compact, darkly stained appearance and the spherical, intensely staining oocyst wall-forming bodies which appear in its cytoplasm (Fig. 16). In kidney sections, such



Tyzzeria boae n.sp., in *Boa constrictor constrictor*. Fig. 31: line-drawings of mature oocysts in $K_2Cr_2O_7$ cultures of cloacal contents and kidney tissue.

zygotes are frequently seen rupturing into the lumen of the distal and collecting tubules (Fig. 30), from where they will clearly be expelled into the ureters and carried to the cloaca.

DISCUSSION

The type species of *Tyzzeria* is *T. perniciosa* Allen, 1936, first described from the domestic duck *Anas platyrhyncha domestica* (Aves: Anseriformes) on Long Island, U.S.A. The parasite was shown to be highly pathogenic, sometimes producing a haemorrhagic enteritis extending throughout the gut.

Levine (1988) accepts only nine species of the genus, including *T. perniciosa* (Table), of which six were recorded in birds, two in snakes and one in rodents. He thus favours the view of Hanson et al. (1957) who considered that several other described species from a variety of wild geese and swans are, in fact, synonymous with *T. parvula* of *Anser anser domesticus*, the domestic goose.

In only four of the recognized species has the site of development in the host been determined, and in all cases it is the small intestine. The remaining five species are known only from their oocysts, described from faeces. Unless some of the latter are subsequently shown to develop in the kidney, *T. boae* n.sp. is therefore exceptional in its development in the kidney tubules, and on this count alone deserves its separate specific name. As it happens, however, it is also separated from all previously described *Tyzzeria* species on oocyst morphology, and from most of them by its long sporulation time (Table).

Of the two species previously recorded from snakes, *T. natrrix* differs from *T. boae* in its smaller oocyst, which is figured with a much more robust "...double contoured wall...", development in the small intestine, and a sporulation time of only five days. The host, *Natrix tigrina*, is a member of the family Colubridae, and both taxonomically and geographically far removed from the genus *Boa*

TABLE

Recognised species of the genus *Tyzzeria* Allen, 1936 (Apicomplexa: Eimeriidae)

Parasite	Host	Oocyst (μm)	Developmental site	Sporulation time
<i>T. allenae</i> Chakravarty & Basu, 1946 emend. Pellerdy, 1974	<i>Nettapus</i> <i>coromendelianus</i> (Aves: Anseriformes)	ellipsoidal: 14-17 x 10-11	rectum	2 days
<i>T. boae</i> n.sp., present observations	<i>Boa c.</i> <i>constrictor</i> (Serpentes: Boidae)	spherical/sub spherical: av. 19 x 18	kidneys	8 days
<i>T.</i> <i>chenicusae</i> Ray & Sarkar, 1967	<i>N.</i> <i>coromendelianus</i> (Aves: Anseriformis)	cylindrical: av. 24.8 x 16.8	? ^a	3-5 days
<i>T. galli</i> Fernando & Remmler, 1973	<i>Gallus</i> <i>lafayettei</i> (Aves: Gallidae)	spherical: 12-15	? ^a	?
<i>T. natrix</i> (Matubayasi, 1936) Matubayasi, 1937	<i>Natrix tigrina</i> (Serpentes: Colubridae)	spherical: 11.7-16.1	small intestine	5 days
<i>T. parvula</i> (Kotlán, 1933) Klimeš 1963	Various spp. of <i>Anser</i> , <i>Branta</i> , <i>Aythya</i> and <i>Olor</i> (Anseriformes)	spherical/sub spherical: 10-15 x 10-14	small intestine	1 day
<i>T. pellerdyi</i> Bhatia & Pande, 1966	Various spp. of <i>Anas</i> and <i>Aythya</i> (Anseriformes)	ellipsoidal: 11-16 x 8-11	? ^a	?
<i>T.</i> <i>perniciosa</i> Allen, 1936 TYPE SPECIES	<i>Anas p.</i> <i>domestica</i> ; other spp. of <i>Anas</i> and <i>Aythya</i>	ellipsoidal: 10-13 x 9-11	small intestine	1 day
<i>T. peromysci</i> Levine & Ivens, 1960	<i>Peromyscus</i> <i>maniculatus</i> , <i>P.</i> <i>leucopus</i> (Rodentia)	ellipsoidal: 11-17 x 9-12	? ^a	?
<i>T. typhlopis</i> Ovezmukhamedov, 1968, emend. Levine, 1988	<i>Typhlops</i> <i>vermicularis</i> (Reptilia: Typhlopidae)	ellipsoidal: 31.5-32.4 x 18.9-20.7	? ^a	?

^a: only oocysts described, from faeces.

(Family Boidae). *T. typhlopis* is distinguished by its larger and elongated oocyst: the host, *Typhlopis vermicularis*, is a small burrowing snake of the family Typhlopidae and, once again, is taxonomically widely separated from the Boidae.

ACKNOWLEDGEMENTS

To Constância M Franco and Manoel C de Souza for technical assistance, and to Valter M Campos for preparation of the kidney sections. Prof Vera M Safjanova and Prof R Killick-Kendrick kindly helped us obtain the Russian and Japanese literature.

REFERENCES

- Allen EA 1936. *Tyzzeria perniciosus* gen. et sp. nov., a coccidium from the small intestine of the Pekin duck, *Anas domesticus* L. *Arch Protistenkd* 87: 262-267.
- Bhatia BB, Pande BP 1966. On two new species of coccidia from wild Anatidae. *Acta Vet Acad Sci Hung* 16: 336-340.
- Chakravarty M, Basu SP 1947. On a new coccidium, *Tyzzeria alleni* n.sp., from the intestine of the bird cotton-teal. *Sci Cult* 12: 106.
- Fernando MA, Remmler O 1973. Four new species of *Eimeria* and one of *Tyzzeria* from the Ceylon jungle fowl *Gallus lafayettei*. *J Protozool* 20: 43-45.
- Hanson HC, Levine ND, Ivens V 1957. Coccidia (Protozoa: Eimeriidae) of North American wild geese and swans. *Can J Zool* 35: 715-733.
- Klimeš B 1963. Coccidia of the domestic goose (*Anser anser* dom.). *Zentralbl Veterinaermed Reihe B*, 10: 427-448.
- Kotlán A 1933. Zur Kenntnis der Kokzidiose des Wassergeflugels. Die Kokzidiose der Hausgans. *Zentralbl Bakteriol Parasitenkd Infektionskr Hyg Abt 1 Orig* 129: 11-21.
- Lainson R 1958. Observations on the development and nature of pseudocysts and cysts of *Toxoplasma gondii*. *Trans R Soc Trop Med Hyg* 52: 396-407.
- Levine ND 1988. *The Protozoan Phylum Apicomplexa* Vol I, CRC Press, Inc., Boca Raton, Florida, USA, 139 pp.
- Levine ND, Ivens V 1960. *Eimeria* and *Tyzzeria* (Protozoa: Eimeriidae) from deer mice (*Peromyscus* spp.) in Illinois. *J Parasitol* 46: 207-212.
- Matubayasi H 1936. On a new coccidia, *Koidzumiella natrix* n.g. n.sp., parasitic in Japanese snakes; with some remarks on two other ophidian coccidia of the genus *Caryospora* and *Isospora*. *Keio Igaku* 16: 1719-1729.
- Matubayasi H 1937. Studies on parasitic protozoa in Japan II. Coccidia parasitic in snakes, with special remarks on *Tyzzeria* (*Koidzumiella*) *natrix*, parasitic in *Natrix tigrina*. *Annot Zool Japan* 16: 255-275.
- Ovezmukhamedov A 1968. Koktsidii nekotorykh presmykayushchikhsya Turkmenii. *Izv Akad Nauk Turkm SSR Ser Biol Nauk* 2: 67-70.
- Pellerdy LP 1974. *Coccidia and Coccidiosis*, 2nd Edition. Verlag Paul Parey, Berlin & Hamburg.
- Ray HN, Sarkar A 1967. On a new coccidium, *Tyzzeria cheniscusae* n.sp., from cotton teal, *Cheniscus coromendelianus* (Aves: Anseriformes). *J Protozool* 14: Supplement, p. 27, abs 95.