









## Surgical removal of periocular neof ormation in Peixe -Kinguíu (*Carassius Auratus*) submitted to anesthesia with propofol in combination with morphine – case report

[Remoção cirúrgica de neof ormación periocular em peixe-kinguiú (*Carassius Auratus*) submetido à anestesia com propofol em associação com morfina – relato de caso]

M.C.L. Rorig<sup>1</sup> , J.R. Garcez<sup>1</sup> , L.A. Baumgartner<sup>1</sup> , M.R. Matos<sup>1</sup> , M. Wilmsen<sup>2</sup> ,  
S.U. Cardoso<sup>1</sup> , S.D. Silveira<sup>3</sup> , R.A. Bombardelli<sup>4</sup> 

<sup>1</sup>Graduate, Universidade Estadual do Oeste do Paraná, Unioeste, Toledo, PR, Brasil

<sup>2</sup>Pontifícia Universidade Católica do Paraná, PUC-PR, Toledo, PR, Brasil

<sup>3</sup>Centro Universitário de Cascavel, Univel, Cascavel, PR, Brasil

<sup>4</sup>Universidade Estadual do Oeste do Paraná, Unioeste, Toledo, PR, Brasil

### ABSTRACT

Different anesthetic agents are commonly used during procedures performed in aquaculture to minimize stress and maximize fish welfare during handling. A Kinguiú fish was treated with a history of a mass near the left eye. In the clinical evaluation, a pedunculated neof ormation was found in the periocular region. The fish was submitted to anesthesia for surgical removal of the mass, which was later referred to histopathological evaluation, revealing myxoma. The anesthesia protocol used 1% propofol at a concentration of 5 mg/liter of water and morphine at a dose of 5 mg/kg, intramuscularly. Immediately after the end of the procedure, the fish was returned to the aquarium and its anesthetic recovery was observed. The objective of this report is to describe a surgical procedure in kinguiú fish and to determine the efficacy of propofol associated with morphine in this species. As a result, complete immobilization of the fish was obtained with propofol, reaching the fourth stage of anesthesia and the administration of morphine suggested being able to provide effective and long-lasting analgesia. It is concluded that despite the positive results obtained, anesthesia in fish still needs to be extensively investigated to refine analgesia protocols during procedures that cause pain and stress.

Keywords: welfare, analgesia, anesthesia, myxoma, fish

### RESUMO

Diferentes agentes anestésicos são usados durante procedimentos realizados na aquicultura para minimizar o estresse e maximizar o bem-estar dos peixes durante o processo de manejo. Um peixe kinguiú foi atendido com histórico de presença de uma massa próxima ao olho esquerdo. Na avaliação clínica, constatou-se uma neof ormación pedunculada na região periocular. O peixe foi submetido à anestesia para remoção cirúrgica da massa, que posteriormente foi encaminhada para avaliação histopatológica, a qual revelou mixoma. Como protocolo de anestesia, utilizou-se propofol 1% diluído em água, na concentração de 5mg/litro, e morfina, na dose de 5mg/kg, na concentração de 10mg/mL, intramuscular. Imediatamente após o procedimento, o peixe foi devolvido ao aquário para observação da recuperação anestésica. O objetivo deste relato é descrever um procedimento cirúrgico em peixe kinguiú e determinar a eficácia do propofol associado à morfina nessa espécie. Como resultados, obteve-se a imobilização completa do peixe com o uso do propofol, atingindo o quarto estágio da anestesia, e a administração da morfina sugeriu ser capaz de proporcionar analgesia eficaz e duradoura. Conclui-se que, apesar dos resultados positivos obtidos, a anestesia em peixes precisa ainda ser bastante investigada para refinar os protocolos de analgesia durante os procedimentos que causam dor e estresse.

Palavras-chave: bem-estar, analgesia, anestesia, mixoma, peixe

Corresponding author: cecilia.lima@pucpr.br

Submitted: January 24, 2022. Accepted: November 9, 2022

## INTRODUCTION

The growing use of fish as an experimental model combined with a greater understanding of aquatic animal medicine daily requires the need to seek information for the proper care of these animals (Gräns *et al.*, 2014). Given the importance of ornamental aquarium fish trade, aquatic animal medicine is of great importance in helping to understand the veterinary needs related to aquaculture (Gaveta, 2020).

Different anesthetic agents are commonly used in aquaculture procedures to minimize stress and maximize fish welfare during handling (Gholipur and Ahadizadeh, 2013). Propofol is a hypnotic and sedative agent characterized by fast action and recovery, safety, and minimal adverse effects. However, a limited number of studies have evaluated the efficacy of using this anesthetic in fish (Massone, 2019).

Among the most studied analgesics in teleost fish, morphine is the one that has shown better results and fewer adverse effects, in addition to a greater amount of evidence regarding its action and effects. (Chatigny *et al.*, 2018).

The present case report aims to describe a surgical procedure in a Kinguio fish (*Carassius auratus*) and to determine the effectiveness of propofol associated with morphine in this species, since the demand for the use of anesthetic and analgesic drugs in fish is increasing, especially when it refers to the field of exotic animal medicine.

## CASE REPORT

A 6-month-old Kinguio fish (*Carassius auratus*) with a body weight of 100 grams was treated at a veterinary hospital with history of presenting a mass close to the left eye. In the clinical evaluation, a periocular, pedunculated, neoformation was found, measuring 0.9x 0.4cm (Fig.1A). In view of the changes observed, surgical removal of the neoformation was suggested and, subsequently, the referral of the obtained sample for histopathological analysis.

The animal was fasted for 24 hours before the surgical procedure. To perform the surgery, the fish was then carefully removed from the aquarium and immersed in the anesthetic solution diluted in a container with a capacity of 2 liters of water (Fig. 1B).

Deionized water was used for the anesthetic dilution, at a temperature of 25<sup>0</sup>C. The anesthetic protocol consisted of an association of 1% propofol diluted in water at a concentration of 5mg/liter and morphine at a dose of 5mg/kg at a concentration of 10 mg/ml administered intramuscularly. After 1 minute being immersed in the anesthetic solution, the second stage of anesthesia was reached. After two minutes, reactions compatible with the third stage of anesthesia were observed and the fourth stage was reached 3 minutes after immersion in water with the dilution of the anesthetic (Fig. 1C).

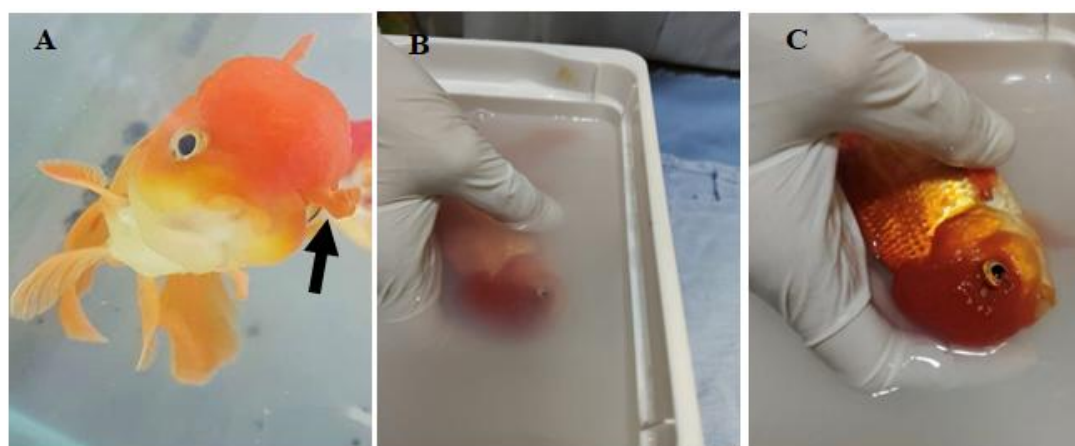


Figure 1. A- Periocular neoformation (arrow). B- Immersion in anesthetic solution. C- Kinguio fish in the fourth stage of anesthesia.

Recognition anesthesia stages were based on behavioral responses following the scale of stages of anesthesia in fish (Bowser, 2001). Table 1 refers to the evaluation of behavior

during anesthetic induction as well as the recognition of the anesthesia stage and the time of anesthetic induction.

Table 1. Behavioral evaluation during anesthetic induction

Anesthetic induction time (minutes)	Behavior	Stages of anesthesia
1	Erratic swimming, normal balance, loss of reaction to external stimuli	2
2	Erratic swimming, loss of balance, loss of response to external stimuli	3
3	Loss of spinal reflexes	4

Upon reaching the fourth stage of anesthesia, the fish was removed from the anesthetic solution and placed on a soft and moistened surface (Fig. 2A) where 5mg/kg of morphine was applied intramuscularly, just below the dorsal fin (Fig. 2B)

The neoformation was surgically removed, making an elliptical incision, around the base of the neoformation, with the aid of a scalpel handle and anatomical forceps, using a number 15 blade. After excision of the neoformation, a simple interrupted suture pattern was performed with 4.0 non-absorbable synthetic monofilament nylon thread (Fig. 2 C, D and E).

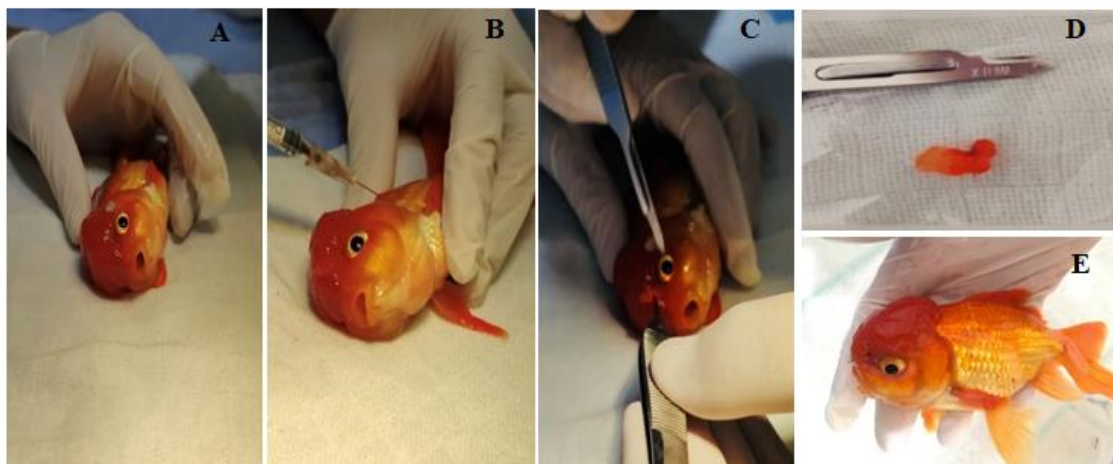


Figure 2. A- Fish placed on soft and moistened surface. B- Intramuscular application of morphine. C- Surgical removal of neoformation. D- Neoformation removed. E- Simple interrupted suture (arrow).

The duration of the surgical procedure was 20 seconds. After the suture was finished, the fish returned to the aquarium of origin where anesthetic recovery and behavioral changes were monitored (Fig. 3 A and B and table 2). Anesthetic recovery was assessed by response to mild external stimulus (righting reflex when

pushed with the aid of an object to a lateral position) and by obstacle avoidance (object positioned in front of the animal) (Balko *et al.*, 2017). Anatomical forceps were used as an object to evaluate the response to external stimuli.

### *Surgical removal...*

Table 2. Behavior assessment during anesthetic recovery

Time after procedure completion (minutes)	Behavior	Anesthesia stage	Position in the water column
1	Erratic swimming, loss of balance, loss of response to external stimuli	3	Bottom
3	Erratic swimming, normal balance, slight loss of response to external stimuli	2	Bottom
7	Normal balance, reduced movements, reaction to external stimuli	1	Intermediate position in the water column
10	Normal balance, faster movements, reaction to external stimuli	1	Intermediate position in the water column
30	Normal balance, rapid movements, reaction to external stimuli	Anesthetic recovery	Top of the aquarium Intermediary Bottom

The fish was discharged five days after the surgical procedure, apparently in good general condition (Fig. 3C). Histopathological examination showed neoplastic proliferation of

mesenchymal cells, non-encapsulated, slightly cellular, of infiltrative growth and well demarcated, confirming myxoma.




Figure 3. A- Fish at the bottom of the aquarium one minute after the end of the procedure. B- Positioning at the top 30 minutes after the end of the procedure. C- Fish 5 days after the procedure (discharge).

### **DISCUSSION**

The use of anesthetics in fish is recommended when immobilization is necessary, however, it is essential to promote animal welfare, minimizing the signs of stress and pain during procedures considered invasive, such as the surgical removal of tumors (Martins *et al.*, 2018; Gaveta, 2020). Teleost fish show behavioral changes and signs

of discomfort when submitted to potentially painful procedures (Marques *et al.*, 2021). In this case report, the choice of associating a general anesthetic with an opioid aimed to promote chemical restraint of the fish, in addition to providing analgesia and well-being.

Pre anesthetic drugs are useful for stress and anxiety reduction and currently opioids represent

one of the most common preanesthetic and analgesic drug categories in veterinary medicine (Massone, 2019). However, there is no strong evidence of efficacy for many analgesics in fish, including anti-inflammatory drugs, with morphine being the most studied analgesic and which has shown the most beneficial effects in fish including anti-inflammatory properties (Chatigny *et al.*, 2018). Therefore, the choice of morphine as an analgesic in the present report is highlighted.

The surgical removal of periocular neoformation was considered an invasive procedure as it caused tissue injury. In this context, it is important to emphasize that among the most suitable drugs for the treatment of pain, the use of pure agonist hypnoanalgesics is highlighted. Morphine, classified as a pure agonist, has been shown to be effective in controlling pain in the postoperative period, and is currently considered the analgesic of choice to reduce post-surgical pain in the species (Chatigny *et al.*, 2018).

In fish, morphine excretion rate is slower, the half-life is longer, and the drug total elimination time is quite prolonged, making it a favorable drug after surgical procedures. The choice of morphine as well as the administered dose aimed to provide prolonged analgesia and minimize the occurrence of adverse drug effects such as intermittent hyperactivity, similar to hyperactivity induced by opioids in other species, like cats, mice, horses and humans (Baker *et al.*, 2013).

Propofol is an anesthetic agent increasingly used in several fish species safely and effectively (Martins *et al.*, 2018; Zahan *et al.*, 2021). The surgical procedure performed with the association of propofol and morphine resulted in adequate chemical restraint and evidence of an analgesic effect through the association of morphine due to the observation of rapid return to food intake and the expression of normal behavior after anesthetic recovery (Chatigny *et al.*, 2018).

Although the routes of administration of propofol are widely used as intravenous or intraosseous, studies carried out with fish have demonstrated its potential use as an immersion anesthetic and a possible alternative to more conventional anesthetics, besides demonstrating a good safety

margin to avoid excessively deep inductions inducing a gentle anesthesia (Gonçalves and Giaquinto, 2020).

Anesthetic induction occurred quickly, between 1 and 5 minutes, with no hyperactivity and stress reactions being observed. This reinforces the hypothesis that short induction times are desirable because they reduce the possibility of hypoxemia and acute stress responses (Obirikorang *et al.*, 2020).

During periods of anesthesia induction and recovery, changes in posture, swimming and reflex responses were observed. Among them, balance, position in the water column, responses to external stimuli and eating behavior (Baker *et al.*, 2013; Martins *et al.*, 2018). In addition to these changes also observed in Kinguio fish, the different positions in the water column can also be considered relevant in the evaluation of anesthetic recovery, as well as the time to return to feeding, shorter than 24 hours (Baker *et al.*, 2013).

Fish submitted to anesthetic procedures are at greater risk of regurgitation of food content, which can lodge in the gills, impairing gas exchange or even contribute to the degradation of water quality by fecal contamination of water used for anesthesia (Stetter, 2001). In this case, fasting was performed to reduce risks to the patient both regarding complications related to the respiratory system and in terms of prophylaxis of infections.

For short-term surgical procedures, only two compartments are needed, one for the administration of the anesthetic agent and the other for recovery, as was done in the present case, in which the surgical procedure had short duration. However, for longer procedures, two compartments are used for anesthesia, one with a higher concentration of anesthetic for induction and another with a lower concentration for maintenance, in addition to the compartment for anesthetic recovery (Stetter, 2001).

Careful handling and maintenance of skin moisture prevents injury and excessive mucus loss (Lewbart and Harms, 1999; Murray, 2002). The patient can remain out of the water, but their skin must be kept moist to prevent desiccation (Stetter, 2001). It is also important in these cases

to use an anesthetic system that allows water to flow steadily over the gills (Murray, 2002). In this context, the choice of the size of the container used for anesthetic induction in the reported procedure is justified, since it made it possible to minimize the risks of skin drying in addition to a constant flow of water over the gills.

Anesthetic recovery was quick, between 5 and 10 minutes after the animal was transferred to water without anesthetic. A body weight of 100 grams can be one of the possible causes for short anesthetic induction and recovery, demonstrating the importance of considering the size of animals undergoing this anesthesia protocol. It is important to emphasize that larger fish are less influenced by the drug concentration to establish the induction time, as studies carried out with individuals with more than 25 grams showed shorter induction times compared to fish tested with less than 25 grams subjected to the same concentration of the anesthetic in the immersion water (Obirikorang *et al.*, 2020). In the present report, the observation of the fish recovery did not show evidence of alterations in body homeostasis, which reinforces the hypothesis that anesthetic agents reduce fish activity and metabolism, minimizing physical injuries, oxygen consumption and toxic metabolites excretion (Ross and Ross, 2008).

The patient was observed for 5 days after the surgical procedure and was in good general condition at the time of discharge. In this case, we sought to ensure the animal's well-being with the use of anesthetics. Nevertheless, the understanding of long-term side effects of anesthesia is still not completely clear.

### CONCLUSION

In conclusion, the use of propofol at a concentration of 5 mg/L promoted adequate chemical restraint for the surgical procedure in question, in addition to providing rapid induction and recovery, without evidence of changes in the patient's body homeostasis. Morphine at the dose used proved to be effective as an analgesic agent as well as being safe regarding the occurrence of adverse effects. Despite the positive results obtained in this case, pain control in fish still needs to be investigated to refine analgesia protocols during procedures that potentially

cause discomfort. Thus, properly promoting pain management, ensuring well-being, and obtaining reliable data on surgical procedures performed in the species.

### REFERENCES

- BAKER, T.R.; BAKER, B.B.; JOHNSON, S.M. *et al.* Comparative analgesic efficacy of morphine sulfate and butorphanol tartrate in koi (*Cyprinus carpio*) undergoing unilateral gonadectomy. *J. Am. Vet. Med. Assoc.*, v.243, p.882-890, 2013.
- BALKO, J.A.; WILSON, S.K.; LEWBART, G.A. *et al.* Propofol as an immersion anesthetic and in a minimum anesthetic concentration (MAC) reduction Model in Goldfish (*Carassius auratus*). *J. Zoo Wildlife Med.*, v.48, p.48-54, 2017.
- BOWSER, P.R. Anesthetic options for fish. In: GLEED, R.D.; LUDERS, J.W. *Recent advances in veterinary anesthesia and analgesia: companion animals*. Ithaca: International Veterinary Information Service, 2001.
- CHATIGNY, F.; CREIGHTON, C.M.; STEVENS, E.D. Updated review of fish analgesia. *J. Am. Assoc. Lab. Sci.*, v.57, p.5-12, 2018.
- GAVETA, A.G. *Anaesthesia with MS-222, 2-Phenoxyethanol and clove oil in doctor fish Garra rufa (Heckel, 1843)*. 2020. 99f. Dissertação (Mestrado em Aquicultura) - Escola Superior de Turismo e Tecnologia do Mar - Instituto Politécnico de Leiria, Portugal, 2020. Disponível em: <https://iconline.ipleiria.pt/bitstream/10400.8/4968/2/Tese%2Bmestrado%2BAdriana%2BGaveta%2Bfinal%20%283%29.pdf>. Acessado em: 2 ago. 2022.
- GHOLOPOUR KANANI, K.H.; AHADIZADEH, S. Use of propofol as an anesthetic and its efficacy on some hematologic values of ornamental fish *Carassius auratus*. *SprigerPlus*, v.2, p.2-5, 2013.
- GONÇALVES, B.B.; GIAQUINTO, P.C. Propofol and benzocaine anesthetics responses profiles in Nile Tilapia. *Int. Aquatic Res.*, v.12, p.219-225, 2020.

- GRANS, A.; SANDBLOM, E.; KIESSLING, A. *et al.* Post-surgical analgesia in rainbow trout: is reduced cardioventilatory activity a sign of improved animal welfare or the adverse effects of an opioid drug? *PLoS One*, v.9, p.1-8, p.e95283, 2014.
- LEWBART, G.A.; HARMS, C. Building a fish anesthesia delivery system. *Exotic DVM*, v.1, p.25-28, 1999.
- MARQUES, K. D.; CAVALCANTI, L.V.; NAKAGOMI, C.S. *et al.* Anestesia e analgesia em peixes teleósteos. *Braz. J. Dev.*, v.7, p.79603-79608, 2021.
- MARTINS, T.; VALENTIM, A.; PEREIRA, N. *et al.* Anaesthetics and analgesics used in adult fish for research: a review. *Lab. Anim.*, v.53, p.325-341, 2018.
- MASSONE, F. *Anestesiologia veterinária: farmacologia e técnicas*. 7.ed. Rio de Janeiro: Guanabara Koogan, 2019.
- MURRAY, M.J. Fish Surgery. *Semin. Avian Exotic Pet Med.*, v.11, p.246-257, 2002.
- OBIRIKORANG, K.A.; ASANTE-TUOH, D.T.; AGBO, N.W. *et al.* Anaesthetic potential of propofol for nile tilapia (*Oreochromis niloticus*): Effect of anaesthetic concentration and body weight. *Sci. Afr.*, v.10, p.1-12, p.e00595, 2020.
- ROSS, L.G.; ROSS, B. *Anesthetic and sedative techniques for aquatic animals*. 3.ed. Oxford, UK: Blackwell Publishing, 2008. 240p.
- STETTER, M.D. Fish and amphibian anesthesia. *Vet. Clin. North Am. Exotic Anim. Pract.*, v.4, p.69-82, 2001.
- ZAHARAN, E.; RISHA, E.; RIZK, A. Comparison propofol and eugenol anesthetics efficacy and effects on general health in Nile Tilapia. *Aquaculture*, v.534, 2021.