



Original Article

Evaluation of surgical treatment of Dupuytren's disease by modified open palm technique^{☆,☆☆}

Thiago Almeida Guilhen^{*}, Ana Beatriz Macedo Vieira, Marcelo Claudiano de Castro, Helton Hiroshi Hirata, Itibagi Rocha Machado

Instituto Jundiaiense de Ortopedia e Traumatologia, Jundiaí, SP, Brazil

ARTICLE INFO

Article history:

Received 11 March 2013

Accepted 20 May 2013

Keywords:

Dupuytren contracture

Hand

Surgical procedures operative

ABSTRACT

Objective: to assess the surgical technique using the modified palm open technique for the treatment of severe contractions of Dupuytren's disease.

Methods: over a period of four years, 16 patients underwent surgical treatment, and in its entirety belonged to stages III and IV of the classification proposed by Tubiana et al. We performed measurements of the extension deficit of the metacarpophalangeal joints, proximal and distal interphalangeal in preoperative, postoperative (3 months) and late postoperative period (5–8 years). Angles greater than 30° metacarpophalangeal joints and 15° proximal interphalangeal the results were considered surgical recurrence.

Results: there was obtained an average of 6.3° at the metacarpophalangeal joint, 13.8° in the proximal interphalangeal and distal interphalangeal at 1.9°.

Conclusion: the modified open palm technique is an effective method in the surgical treatment of severe contractures in Dupuytren's disease.

© 2014 Sociedade Brasileira de Ortopedia e Traumatologia. Published by Elsevier Editora Ltda. All rights reserved.

Avaliação do tratamento cirúrgico da doença de Dupuytren pela técnica da palma aberta modificada

RESUMO

Objetivo: avaliar o tratamento cirúrgico com o uso da técnica da palma aberta modificada para o tratamento das contraturas graves da doença de Dupuytren.

Métodos: em quatro anos, foram submetidos ao tratamento cirúrgico 16 pacientes, que pertenciam aos estágios III e IV da classificação proposta por Tubiana et al. Foram feitas aferições do déficit de extensão das articulações metacarpofalangeanas e interfalangeana proximal e distal nos períodos pré-operatório, pós-operatório (três meses) e pós-operatório tardio (cinco a oito anos). Angulações maiores do que 30° nas articulações metacarpofalangeanas e 15° nas interfalangeanas proximais foram consideradas como recidiva cirúrgica.

Palavras-chave:

Contratura de Dupuytren

Mãos

Procedimentos cirúrgicos operatórios

[☆] Please cite this article as: Guilhen TA, Vieira ABM, de Castro MC, Hirata HH, Machado IR. Avaliação do tratamento cirúrgico da doença de Dupuytren pela técnica da palma aberta modificada. Rev Bras Ortop. 2014;49:31–36.

^{☆☆} Study conducted at Instituto Jundiaiense de Ortopedia e Traumatologia, Jundiaí, SP, Brazil.

^{*} Corresponding author.

E-mail: tguilhen@hotmail.com (T.A. Guilhen).

Resultados: obtivemos uma média de déficit de extensão de 6,3° ao nível da articulação metacarpofalangeana, 13,8° na interfalangeana proximal e 1,9° na interfalangeana distal.

Conclusão: a técnica da palma aberta modificada é um método eficaz no tratamento cirúrgico das contraturas graves na doença de Dupuytren.

© 2014 Sociedade Brasileira de Ortopedia e Traumatologia. Publicado por Elsevier Editora Ltda. Todos os direitos reservados.

Introduction

Dupuytren's disease was named after Baron Guillaume Dupuytren,¹ a celebrated French surgeon, whose complete monograph guided the current knowledge of this pathology. In 1831, Dupuytren described the disease as an anatomopathological change, with thickening and retraction of the palmar fascia with flexion deformity of the fingers. This monograph associated the disease to local chronic trauma on the palm, usually related to heavy duty. But Dupuytren cautioned that not all cases could be explained this way.

The condition is due to metaplasia of the palmar fascia fibrous framework, which basically compromise the pretendinous band, superficial transverse ligament, spiral band, natatory ligament, lateral sagittal ligament, and Grayson's ligament.

The Dupuytren's contracture follows a progressive evolution, and its initial manifestations are an invagination of the skin and the appearance of nodules that unite among them, forming hard consistency cords in the palm and advancing longitudinally to the finger. The condition is usually painless, and after its maturation may suffer retractions, which cause a flexion deformity of the metacarpophalangeal (MCP) and proximal interphalangeal (PIP) joints. The condition affects more men than women (ranging from 7:1 to 10:1), from the fourth to sixth decade of life; and the fourth and fifth fingers are the most commonly affected. Additionally, there may be an association with the formation of fibrous strands in the plantar fascia (Lederhose's disease, 5%) and in the penile fascia (Peyronie's disease, 3%).²

Its etiology is still unknown, but the importance of heredity was proved, because of the high incidence in the descendants of northern Europe. The condition is even known as "disease of the Vikings". Its inheritance is autosomal dominant with reduced penetrance in women. There is a significant association with epilepsy, diabetes, trauma, and alcohol intake, and no evidence that it is an occupational disease.²⁻⁴

The anatomopathologic aspect is that of an aggressive lesion, displaying a large number of cells and mitoses. The basic cell present is the myofibroblast (similar to fibroblast), usually found in the palmar fascia, but with significant ability to generate contractile forces. The transforming growth factor β (TGF- β) is an abundant cytokine present in the tissue, being largely responsible for the proliferation and differentiation of fibroblasts into myofibroblasts. Moreover, it improves the contractile behavior of myofibroblasts and causes rapid and stronger contractions in response to mechanical stimuli.^{2,5}

Other factors influencing the differentiation, growth, and contractility of myofibroblasts include platelet-derived protein, fibroblast growth factor, epidermal growth factor, and

interleukin-1, as well as cells that synthesize the proteins periostin and tenascin.⁵

The diagnosis is clinical, being established by inspection and palpation. The differential diagnosis includes acampodactilia, rheumatoid arthritis, retraction of the scar caused by burn or injury, palmar callus of effort, and ulnar nerve deficit.⁵

Compared to conservative treatment, the most promising therapy is the application of intrafocal clostridium collagenase in the cord, now in an advanced clinical trial phase.⁵

Nowadays, the surgical option is the most acceptable. In the development of the therapeutic plan, it is important to determine the stage at which the disease is, as this knowledge influences the intraoperative technical difficulty and in the post-operative complications, as well as the recurrence of the disease. The need for more extensive dissection, the devitalized skin and the excessive tension on the suture are predisposing factors for post-operative complications, such as hematoma, skin necrosis, infection and pain.^{5,6}

The original surgical treatment was the removal of the contracted fascia; since then, various techniques and modifications have been described: fasciotomy, dermofasciotomy with skin graft, regional fasciotomy, radical fasciotomy, open palm technique, partial fasciotomy with preservation of the skin, limited fasciotomy, segmental aponeurotomy, and percutaneous fasciotomy.^{1,4,6-10}

In the open palm technique, originally described by Dupuytren¹ and popularized by McCash,⁷ a regional fasciotomy in the palm of the hand is done, allowing the extension of the fingers. This procedure results in a large skin defect. The wound is left open to heal by secondary intention, to avoid stress and hematoma formation; this reduces the incidence of necrosis and the possibility of infection and scar adhesions.⁶

Objective

The objective of this study is to evaluate the results of surgical treatment of patients with Dupuytren's disease grades III and IV operated in our department with the use of the open palm technique (McCash) modified with the association of proximal and distal longitudinal incisional extensions on the palm, besides Brunner incisions in the fingers.¹¹

Materials and methods

From March 2004 to December 2007, 16 patients with clinical diagnosis of Dupuytren's disease underwent surgical treatment. The mean age was 65 years (range, 54-75), with postoperative follow-up of 5-8 years. Six patients were affected only in the fifth finger, five were bilateral and five

Table 1 – Preoperative, post-operative (three months) and late post-operative (5–8 years) angulation.

	Preoperative			Post-operative			Late post-operative		
	MCP	PIP	DIP	MCP	PIP	DIP	MCP	PIP	DIP
Patient 1	45	35	20	05	00	00	15	20	00
Patient 2	50	30	20	05	05	00	05	20	00
Patient 3	40	30	15	00	00	00	00	10	00
Patient 4	50	40	20	00	05	05	10	30	05
Patient 5	45	30	15	05	10	00	25	20	00
Patient 6	40	30	20	00	05	00	00	05	00
Patient 7	50	35	10	00	05	00	00	05	00
Patient 8	45	30	10	05	00	00	05	05	05
Patient 9	50	35	20	05	00	00	05	10	05
Patient 10	45	30	20	00	00	00	00	10	00
Patient 11	50	40	10	00	00	00	15	20	00
Patient 12	40	30	20	00	00	00	00	10	00
Patient 13	45	35	20	05	00	05	05	10	05
Patient 14	55	40	25	00	00	05	10	20	05
Patient 15	50	45	25	00	05	05	05	15	05
Patient 16	45	30	25	00	00	00	00	10	00

MCP, metacarpophalangeal; PIP, proximal interphalangeal; DIP, distal interphalangeal.

unilateral, with involvement of the fourth and fifth fingers. Thirteen patients were male Caucasians, including the three women.

In our study, we used the classification proposed by Tubiana et al.,¹² which consists of the sum of the extension deficits of the metacarpophalangeal (MCP), proximal interphalangeal (PIP), and distal interphalangeal (DIP) joints, measured with a goniometer. This classification is divided into four stages: grade I (0–45°), grade II (46–90°), grade III (91–135°), and grade IV (>135°). In this study, were included only patients with Grades III and IV, and it was taken into account only the finger with greater involvement.^{11,12}

In all patients, the surgical technique used was that recommended by McCash, with transverse incision in the distal palmar crease, associated with a modification with proximal and distal longitudinal incisional extensions on the palm. In the fingers, Brunner incisions were made. We made a partial fasciotomy, which left open only the transverse incision.⁴

Post-operative care consisted of daily dressing changes during the first 48 h, daily changes in the next two weeks, and every three days in subsequent weeks. The fingers were immobilized in extension for the first five days and the patient was referred for early chirotherapy rehabilitation.

The extension deficits for MCP, PIP, and DIP joints were gauged in preoperative, post-operative (three months) and late post-operative periods (5–8 years). Extension deficits exceeding 30° in MCP, 15° in PIP, and 10° in DIP joints were considered as surgical recurrences.^{11,12}

Results

Table 1 lists the measurements of the extension deficit, in degrees, of the three joints (MCP, PIP, and DIP) obtained with a goniometer.

Fig. 1 displays the results of measurements of the extension deficits in each joint in the pre-, post-, and late post-operative period.

To compare the angle of the MCP, PIP, and DIP joints of patients with respect to preoperative, post-operative (three months) and late post-operative period (5–8 years), we applied the non-parametric statistical test of Mann–Whitney for paired samples, and the *p* values were corrected by Bonferroni method for multiple comparisons. Table 2 shows the results of the tests.

For the three joints, a statistically significant decrease was observed for the average angle of the pre- to post-operative period, at the level of 5% (*p* < 0.05). For the MCP and DIP joints, no significant difference between the post-operative period (three months) and late post-operative period (5–8 years) was noted. However, for the PIP joint a significant mean increase between the post-operative and late post-operative periods was noted (*p* = 0.0025), but still at a lower value than that observed preoperatively.

Fig. 2 displays the scatter plot and the Spearman's correlation coefficient among the joints for the angulations measured. A strong positive correlation among measures of different joints, with coefficients between 0.75 and 0.85 (all statistically significant, *p* > 0.0001) was noted.

Table 2 – Results of the Mann–Whitney test for comparison of measurements of the joints between periods.

Comparisons	<i>p</i> ^a		
	MCP-FL	PIP	DIP
Pre × post	0.0012	0.0013	0.0012
Pre- × post-late	0.0012	0.0013	0.0012
Post- × post-late	0.1020	0.0025	1.0000

PIP, proximal interphalangeal; DIP, distal interphalangeal.

p values less than 0.05 indicate significant difference at the 5% level.

^a *p* values corrected by the Bonferroni method for multiple comparison tests.

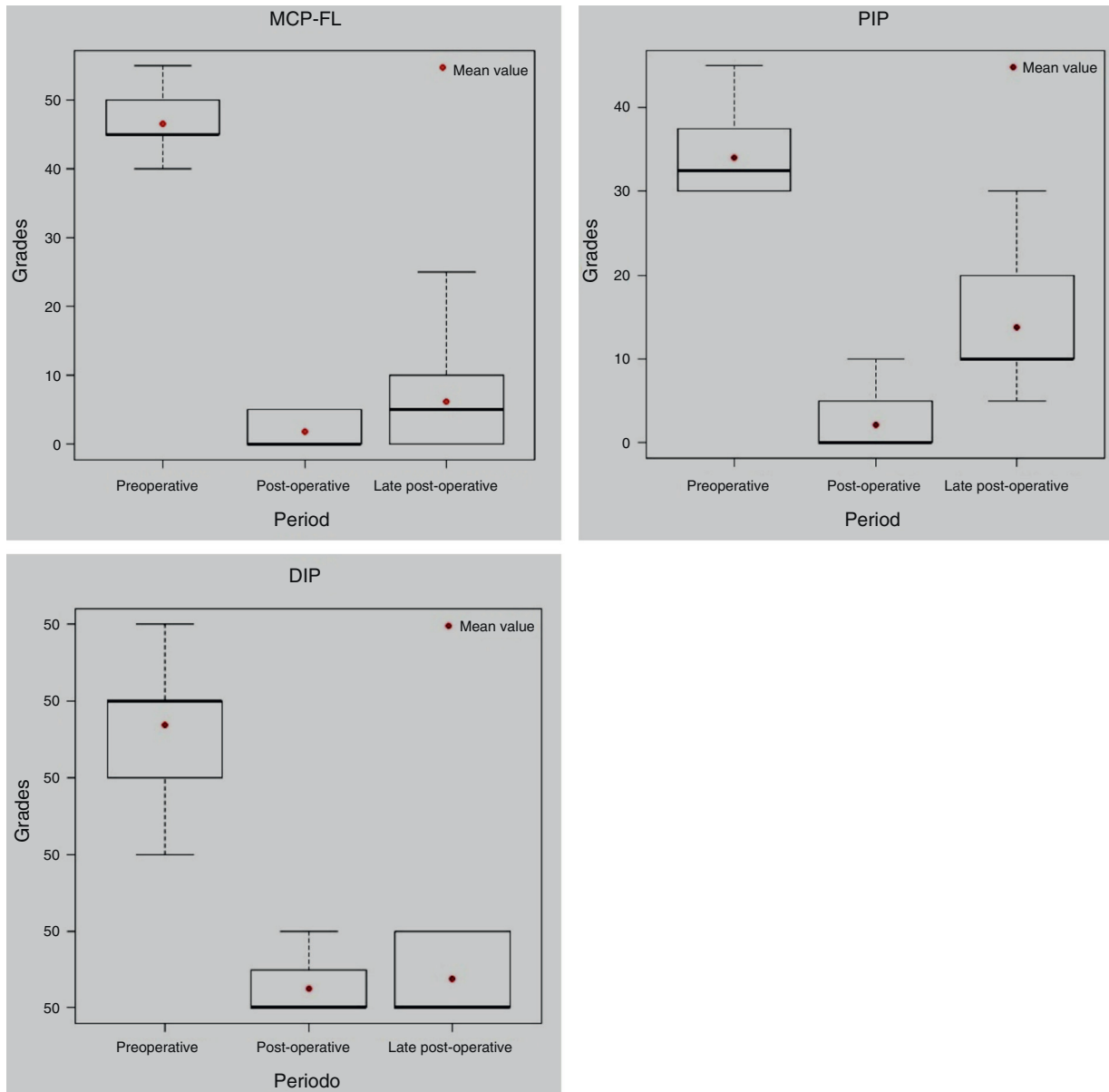


Fig. 1 – Boxes for the joint angulation, according to the joint and by period. In this figure the results of measurements of the extension deficits in each joint in the preoperative, post-operative, and late post-operative period are depicted.

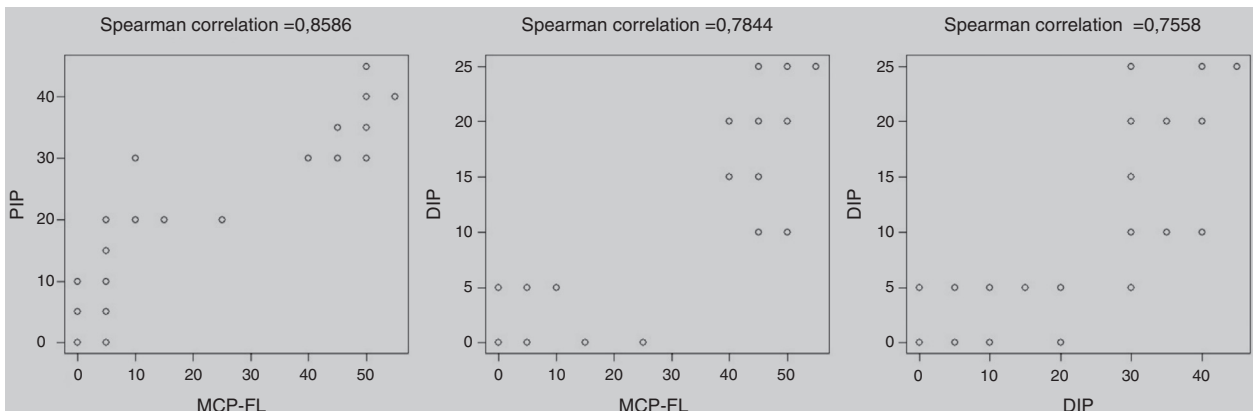


Fig. 2 – Dispersion for angulation measures among different joints.

Table 3 – Values of minimum, median, mean, maximum and standard deviation (SD) for the angulation of the joints, according to joint and period.

Joint	Period	Minimum	Median	Mean	Maximum	SD
MCP	Preoperative	40.0	45.0	46.6	55.0	4.4
	Post-operative	0.0	0.0	1.9	5.0	2.5
	Late post-operative	0.0	5.0	6.3	25.0	7.2
PIP	Preoperative	30.0	32.5	34.1	45.0	4.9
	Post-operative	0.0	0.0	2.2	10.0	3.1
	Late post-operative	5.0	10.0	13.8	30.0	7.2
DIP	Preoperative	10.0	20.0	18.4	25.0	5.1
	Post-operative	0.0	0.0	1.3	5.0	2.2
	Late post-operative	0.0	0.0	1.9	5.0	2.5

MCP, metacarpophalangeal, PIP, proximal interphalangeal, DIP, distal interphalangeal.

This table presents descriptive measures of deficits. Clearly occurs a decrease in the angle of the joints in all patients after surgery.

Discussion

The literature is controversial as to the advantages and disadvantages of the open palm technique, which determines more skin stretching, besides preventing complications such as hematoma, necrosis, skin ischemia, tension and pain. A disadvantage would be an increased risk of infection and the patient discomfort by having an “open” injury and by the necessity of more frequent dressings. Lubahn et al.¹³ conducted a comparative study between the two techniques and concluded that patients operated by techniques in which the palm was completely closed came to suffer greater residual contracture.^{8,13,14}

In the present study, 13 (81.25%) males and three (18.75%) females were recruited, all Caucasians, which is consistent with the literature, which reports 80% of male and dominance of Caucasians. In this study, the mean age of patients was 65 years (range, 54–75), similar to that of most studies.^{15,16}

In our study we found 37.5% of surgical recurrence. These rates vary widely (28–50%), regardless of the technique used. However, to obtain good results the patient must have an adequate post-operative care, and an stimulus for early active mobilization after removal of immobilization, under orientation of a chiropractor. McGrouther is most emphatic that, in a long-term post-operative period, the recurrence rate reaches 100% for some degree of contracture. This fact occurs because there is a residual pathological fascia, or what is called the extent of the disease, in which there is the formation of new fascia in a place near the surgical site.^{12,17,18}

Recurrence in MCP joint is very low. On the other hand, in PIP joint the incidence of recurrence is higher. Our study described six cases of surgical recurrence, all in the PIP joint, because of an angulation > 15° in the late postoperative period (5–8 years), which agrees with the literature.^{9,19}

Concerning MCP and DIP joints, no significant differences in the angulations between the post-operative period (three months) and late post-operative period (5–8 years) were observed. However, for the PIP joint there was a significant mean increase in angulation between the post-operative (mean, 2.2°) and late post-operative (mean, 13.8°) periods, which shows a higher rate of recurrence in the PIP joint—also observed in other works.^{9,19}

An extension deficit decrease for all patients in the two postoperative periods compared to the preoperative period was observed, which is shown in the boxes (Fig. 1). This demonstrates the effectiveness of the open palm technique (modified), provided there is an appropriate therapeutic plan, which is consistent with the literature.^{5,6}

In comparing the three joints in the three periods (Table 3), only the PIP joint showed significant mean increase between the post-operative and late post-operative periods, which demonstrate a higher recurrence in PIP, also evident in the literature.^{9,19}

Conclusion

The modified McCash technique is an effective option for severe cases (stages III and IV) of Dupuytren's disease.

Conflicts of interest

The authors declare no conflicts of interest.

REFERENCES

1. Dupuytren G. De la retraction des doigts par suite d'une affection de l'aponeurose palmaire Description de la maladie. Operation chirurgicale equivoquant dans de cas. *J Univ Hebd Med Chirprat.* 1831;5:352–65.
2. Barros F, Barros A, Almeida S. Enfermidade de Dupuytren: avaliação de 100 casos. *Rev Bras Ortop.* 1997;32(3):177–83.
3. Galbiatti JA, Fiori JM, Mansano RT, Durigan Junior A. Tratamento da moléstia de Dupuytren pela técnica de incisão longitudinal reta, complementada com z-plastia. *Rev Bras Ortop.* 1998;31(4):347–50.
4. Skoog I. Dupuytren's contracture: pathogenesis and surgical treatment. *Surg Clin North Am.* 1967;47(7):433–44.
5. Black ME, Blazar PE. Dupuytren disease an evolving understanding of an age-old disease. *J Am Acad Orthop Surg.* 2011;19(2):746–57.
6. Bryan AS, Ghorbal MS. Long term result of closed palmar fasciotomy in the management of Dupuytren's contracture. *J Hand Surg Br.* 1988;13(3):254–7.
7. McCash CR. The open palm technique in Dupuytren's contracture. *Br J Plast Surg.* 1964;17:271–80.

8. Hueston JI, Wolfe I. Digital grafts in recurrent Dupuytren's contracture. *Plast Reconstr Surg.* 1962;29:342-4.
9. McFarlane RM. Dupuytren's contracture. In: Green DP, editor. *Operative hand surgery.* New York: Churchill Livingstone; 1993.
10. Hamlin JR. Limited excision of Dupuytren's contracture. *Ann Surg.* 1952;135:94-7.
11. Tubiana R. The principles of surgical treatment of Dupuytren's contracture. *GEM Monography.* 1974: 123-8.
12. Tubiana R, Fahrner M, McCullough MA. Recurrence and other complications in surgery of Dupuytren's contracture. *Clin Plast Surg.* 1981;8(1):45-9.
13. Freitas AD, Pardini AG, Neder AL. Contratura de Dupuytren: tratamento pela técnica da palma aberta. *Rev Bras Ortop.* 1997;32(4):301-4.
14. Lubahn JD, Lister GD, Wolfe I. Fasciotomy and Dupuytren's disease: a comparison between the open palm and wound closure. *J Hand Surg.* 1984;9(1):53-8.
15. McFarlane RM. The current status of Dupuytren's disease. *J Hand Surg Am.* 1983;8 5 Pt 2:703-8.
16. Lamb DW. *The practice of hand surgery.* London: Blackwell Scientific Publication; 1981.
17. Hueston JI. Recurrent Dupuytren's contracture. *Plast Reconstr Surg.* 1962;31:66-9.
18. McFarlane RM. Patterns of the diseased fascia in the fingers in Dupuytren's contracture. *Plast Reconstr Surg.* 1974;54(1):31-44.
19. Tonkin MA, Burke FD, Varian JP. Surgical treatment of Dupuytren's contracture: a comparative study of fasciectomy and dermofasciectomy in one hundred patients. *J Hand Surg Br.* 1984;9(2):156-62.