



Original article

Analysis on the acromial curvature and its relationships with the subacromial space and types of acromion ^{☆, ☆☆}



José Aderval Aragão^{a,b,*}, Leonardo Passos Silva^c,
Francisco Prado Reis^b, Camilla Sá dos Santos Menezes^a

^a Department of Morphology, Universidade Federal de Sergipe (UFS), Aracaju, SE, Brazil

^b Medical School, Universidade Tiradentes (UNIT), Aracaju, SE, Brazil

^c Orthopedics and Traumatology Service, Hospital Santa Casa de Belo Horizonte, Belo Horizonte, MG, Brazil

ARTICLE INFO

Article history:

Received 13 September 2013

Accepted 24 October 2013

Available online 31 October 2014

Keywords:

Acromion/anatomy & histology

Shoulder collision syndrome

Rotator cuff

ABSTRACT

Objective: To correlate the acromial curvature, using the angles proposed, with the subacromial space and types of acromion.

Methods: Ninety scapulas were studied. The acromia were classified as types I, II or III. The acromial curvature was analyzed by means of the alpha, beta and theta angles. We also measured the distance between the anteroinferior extremity of the acromion and the supraglenoid tubercle (DA). The scapulas were grouped in relation to sex and age. The angles proposed were analyzed in relation to each type of acromion and also in relation to the measurements of the distance DA.

Results: Out of the total number of acromia, 39 (43.3%) were type I, 43 (47.7%) type II and eight (9%) type III. The mean ages for each type of acromion (I-III) were 45.6, 55.2 and 51.1 years, respectively. The proportions of the different types of acromion varied in relation to sex and age. The evaluations on the mean beta angle ($p=0.008$) and theta angle ($p=0.028$), with comparisons in relation to each type of acromion and measurements of the distance DA ($p=0.037$), were shown to be statistically significant.

Conclusion: The angles proposed in our study can be used for morphometric analysis on the acromion, especially regarding its curvature, and can contribute towards studies on diseases of the shoulder and aid in surgical planning and analysis of the acromial slope, by means of radiography or magnetic resonance.

© 2014 Sociedade Brasileira de Ortopedia e Traumatologia. Published by Elsevier Editora Ltda. All rights reserved.

[☆] Please cite this article as: Aragão JA, Silva LP, Reis FP, dos Santos Menezes CS. Análise da curvatura acromial e sua relação com o espaço subacromial e os tipos de acrômio. Rev Bras Ortop. 2014;49:636-641.

^{☆☆} Study was developed at Departments of Human Anatomy of the Federal University of Sergipe (UFS) and Tiradentes University (UNIT), Aracaju, SE, Brazil.

* Corresponding author.

E-mail: jaafelipe@infonet.com.br (J.A. Aragão).

<http://dx.doi.org/10.1016/j.rboe.2013.10.005>

2255-4971/© 2014 Sociedade Brasileira de Ortopedia e Traumatologia. Published by Elsevier Editora Ltda. All rights reserved.

Análise da curvatura acromial e sua relação com o espaço subacromial e os tipos de acrômio

R E S U M O

Palavras-chave:

Acrômio/anatomia & histologia
Síndrome de colisão do ombro
Bainha rotadora

Objetivo: Correlacionar a curvatura acromial, por meio dos ângulos propostos, com o espaço subacromial e os tipos de acrômio.

Métodos: Foram estudadas 90 escápulas. Os acrômios foram classificados em tipos I, II ou III. A curvatura acromial foi analisada por meio dos ângulos alfa, beta e teta. Mensuramos também a distância entre o extremo anteroinferior do acrômio e o tubérculo supraglenoidal (DA). As escápulas foram agrupadas em relação ao sexo e à idade. Os ângulos propostos foram analisados em relação a cada tipo de acrômio e também em relação à medida da distância DA.

Resultados: Do total de acrômios, 39 (43,3%) foram do tipo I, 43 (47,7%) do tipo II e oito (9%) do tipo III. A média de idade para cada tipo de acrômio I-III foi de 45,6 anos, 55,2 e 51,1, respectivamente. A proporção dos diferentes tipos de acrômio variou em relação ao sexo e à idade. A avaliação das médias dos ângulos β ($p=0,008$) e θ ($p=0,028$), comparadas em relação a cada tipo de acrômio e às medidas da distância DA ($p=0,037$), mostrou-se estatisticamente significativa.

Conclusão: Os ângulos propostos no nosso trabalho podem ser usados para análise morfométrica do acrômio, em especial de sua curvatura, contribuir para os estudos das doenças do ombro e auxiliar na programação cirúrgica e na análise da inclinação acromial por meio de radiografia ou ressonância magnética.

© 2014 Sociedade Brasileira de Ortopedia e Traumatologia. Publicado por Elsevier Editora Ltda. Todos os direitos reservados.

Introduction

Studies on the morphology of the acromion have gained importance since Neer's work. Based on analysis on human cadavers and clinical observations, Neer described the impact syndrome (IS), an association between acromial morphology and a clinical entity characterized by repeated mechanical shocks caused by the rotator cuff in the subacromial compartment.¹

Subsequently, other authors confirmed the association between the shape of the acromion and rotator cuff injuries (RCIs).²⁻⁴ There is a great variety of shapes of the acromion in the population. Bigliani et al.⁵ proposed a classification system for the acromion from a study on 140 shoulders from human cadavers. They identified three types of acromion: straight (type I), curved (type II) and hooked (type III). The more curved the acromion is, the greater the likelihood of diminished subacromial space, with consequent development of IS and RCIs.⁵

The classification system proposed by Bigliani et al.⁵ has been greatly used to analyze the prevalence of each type of acromion in the population and its relationship with age.⁶⁻⁸

Although greatly used, the classification of the acromion into straight, curved and hooked types is a subjective concept, especially with regard to distinguishing acromion types II and III, and there is scope for wide interobserver variability.^{9,10}

For this reason, some researchers have proposed using angles to understand the variation of the acromial curvature.^{4,11} However, the traditional classification of Bigliani et al.⁵ is still greatly used because it is easy to remember and to reproduce graphically, despite its subjectivity.

In the light of this situation, we created three angles in the present study, for correlation with the types of acromion. These would also provide an objective idea of the subacromial space. We measured the distance between the supraglenoid tubercle and the anteroinferior extremity of the acromion (DA), in order to understand the extent to which the acromial curvature is capable of interfering with this space and thus causing pinching of the structures included in this.

Materials and methods

This research project was approved by the Ethics Committee for Research Involving Human Beings of the Federal University of Sergipe, under protocol no. CAAE 0041.0.107.000-08. No free and informed consent statement was applied because this was a study on cadavers. The scapulas were obtained in accordance with Law 8501, of November 30, 1992, which makes provisions regarding the use of unreclaimed cadavers for the purposes of scientific studies or research.

Ninety scapulas from dry adult human skeletons were studied. These cadavers belong to the Human Anatomy Laboratories of Tiradentes University and the Federal University of Sergipe and are catalogued and identified in relation to sex and age. Among these 90 scapulas, 54 were from males and 36 were from females. The mean age was 51.9 years, ranging from 14 to 81.

The scapulas were grouped in relation to sex and age (≤ 49 years and ≥ 50 years).

The scapulas were digitized using an HP scanner (Deskjet F4180® model). The images were analyzed using the Image J 1.41 software (Wayne Rasband, Research Services

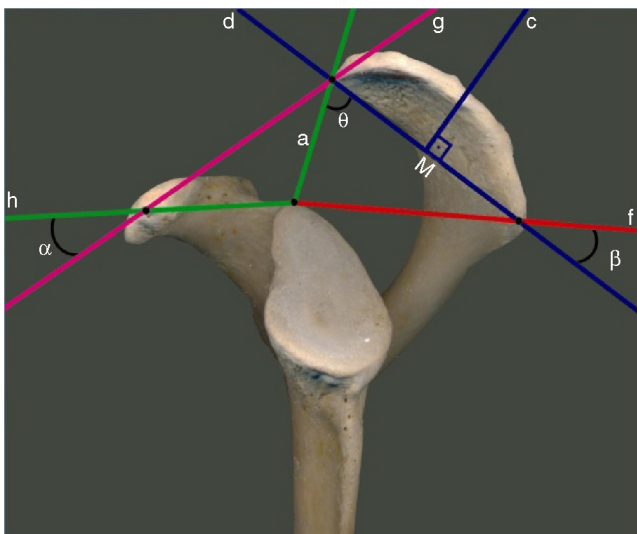


Figure 1 – Layout of straight lines and angles for analyzing the curvature of the acromion.

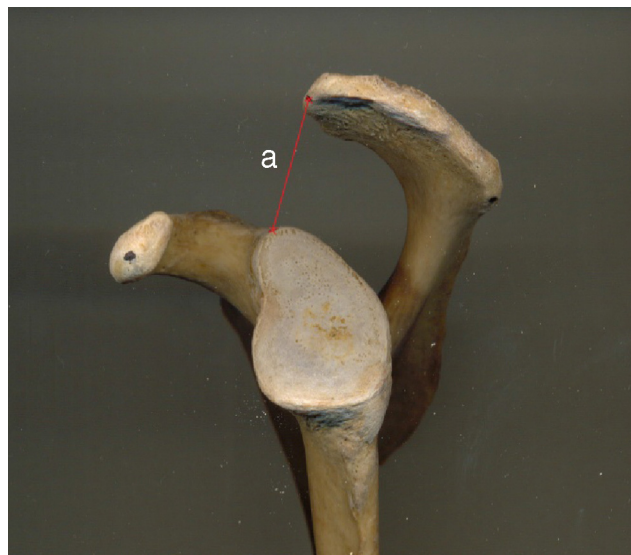


Figure 2 – Distance from the anteroinferior extremity of the acromion to the supraglenoid tubercle.

Branch, National Institute of Mental Health, Bethesda, MD, USA), which is available for download on the website <http://rsbweb.nih.gov>. This software enables precise measurement of distances on images, using a calibration parameter. A rule marked in millimeters was used for the calibration.

The curvature of the acromion was measured by means of three angles: alpha, beta and theta (Fig. 1). The angles were defined between five straight lines: A – between the anteroinferior extremity of the acromion and the midpoint of the supraglenoid tubercle; D – between the anteroinferior extremity and angle of the acromion; F – between the angle of the acromion and the midpoint of the supraglenoid tubercle; G – between the anteroinferior extremity of the acromion and the coracoid process; and H – between the coracoid process and the midpoint of the supraglenoid tubercle. The angle α was between the straight lines G and H; the angle β between F and D; and the angle θ between A and D. These angles provide detailed notions of the subacromial space. The variations in their measurements provide an idea of the behavior of the angling of the acromion and consequently of the narrowing or widening of the subacromial space. Thus, we also measured the distance DA (Fig. 2), which evaluated the distance between the bone structures (acromion and supraglenoid tubercle).

The acromia were also classified in accordance with the model proposed by Bigliani et al.⁵ (Fig. 3).

The data obtained were subjected to statistical analysis by means of the Tukey test, after the F test had shown significance for the analysis of variance, with a significance level of 5%. The distribution of the types of acromion in relation to sex and age was analyzed descriptively.

Results

Ninety dry scapulas from human cadavers (90 acromia) were studied. Out of this total, 39 (43.3%) were of type I, 43 (47.7%) of type II and eight (9%) of type III. The mean ages for the three types of acromion (I-III) were 45.6, 55.2 and 51.1 years, respectively.

In relation to sex, there was variation in the percentages relating to different types of acromion (Table 1).

Table 2 shows the distribution of the types of acromion in relation to age (≤ 49 and ≥ 50 years).

To analyze the curvature of the acromion, we used the angles α , β and θ that we proposed. We observed that the angles β and θ presented a decreasing pattern of means, in comparison with the acromion types I, II and III, respectively. On

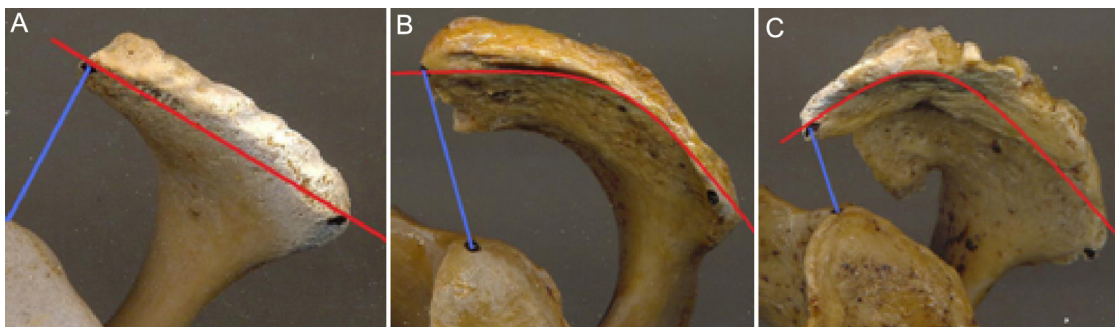


Figure 3 – Types of acromion: (A) type I, (B) type II and (C) type III.

Table 1 – Distribution of the types of acromion according to sex.

Sex	Type I	Type II	Type III
Female (n = 36)	20 (55.5%)	10 (27.7%)	6 (16.8%)
Right	10	5	3
Left	10	5	3
Male (n = 54)	19 (35.1%)	33 (61.1%)	2 (3.8%)
Right	11	15	1
Left	8	18	1
Total (n = 90)	39 (43.3%)	43 (47.7%)	8 (9%)

Table 2 – Distribution of the types of acromion in relation to age and sex.

Age	Type I	Type II	Type III
≤49 years (n = 40)	20 (50%)	15 (37.5%)	5 (12.5%)
Male	9	10	1
Female	11	5	4
≥50 years (n = 50)	19 (38%)	28 (56%)	3 (6%)
Male	10	23	1
Female	9	5	2

the other hand, for the angle α and its relationships with the acromion types, we did not observe any uniformity of behavior among its means.

In analyzing the behavior of the distance DA, we noticed that increasing curvature of the acromion (from type I to type III) reduced the space between the anteroinferior extremity of the acromion and the supraglenoid tubercle.

Angles β , θ and α and the distance DA were correlated with the types of acromion. This descriptive analysis is presented in Table 3.

The evaluation of the means for each of the angles and for the distance DA, in relation to each of the three acromion types (Table 4) showed that there were statistically significant differences in the means for the angle β ($p = 0.008$), the angle θ ($p = 0.028$) and the distance DA ($p = 0.037$). On the other hand, for the angle α , the differences were not statistically significant ($p = 0.810$).

According to the Tukey test, there were differences in the means for the angles β and θ , between acromion types I and III, and also between the means for the distance DA with regard to type III and the other types of acromion (I and II).

Table 4 – Means of the angles and the distance DA in relation to each type of acromion.

	Mean	Standard deviation	F	p-Value
β				
Type I	41.9	4.8	5.50	0.008
Type II	39.3	4.1		
Type III	33.6	6.9		
θ				
Type I	77.5	8.9	3.88	0.028
Type II	73.8	8.7		
Type III	63.7	13.9		
α				
Type I	40.3	8.6	0.21	0.810
Type II	41.7	8.2		
Type III	39.3	7.6		
Distance				
Type I	29.3	4.5	3.56	0.037
Type II	28.7	3.8		
Type III	23.1	6.1		

DA, distance from the anteroinferior extremity of the acromion to the supraglenoid tubercle.

Discussion

The subacromial impact syndrome is directly related to the degree of inclination of the acromion. Thus, variations in its curvature change the dimensions of the space below the coracoacromial arch and may cause lesions of the anatomical structures contained in this region, especially the tendons of the rotator cuff.³

In this regard, Bigliani et al.⁵ presented a scheme for classifying the acromion in accordance with the curvature of its lower surface. The hooked type was seen to have a close relationship with IS and RCIs.⁵ Subsequent studies have confirmed this correlation.^{4,8,12-16}

Other authors have recognized the importance of this classification and have used it to establish the frequency of each type of acromion in different populations. In the original description, Bigliani et al.⁵ found the following proportions for each type of acromion: straight, 17%; curved, 43%; and hooked, 39%.

Among the other authors who have used this classification, the proportions of each type of acromion in the different

Table 3 – Descriptive analysis on the angles and the distance DA in relation to acromion types I, II and III.

Type	Type I				Type II				Type III			
	β	θ	α	DA	β	θ	α	DA	β	θ	α	DA
Mean	41.9	77.5	40.3	29.3	39.3	73.8	41.7	28.7	33.6	63.7	39.3	23.1
Median	40.4	74.7	38.9	29.0	40.0	75.3	40.9	27.5	35.1	64.5	37.8	23.7
Variance	23.0	79.5	73.6	19.9	17.0	75.5	67.8	14.6	47.0	193.0	57.9	37.8
SD	4.8	8.9	8.6	4.5	4.1	8.7	8.2	3.8	6.9	13.9	7.6	6.1
Minimum	33.4	59.5	22.8	21.0	30.4	51.6	28.8	22.6	24.1	49.8	32.2	16.3
Maximum	51.8	92.7	63.4	36.0	47.3	84.5	57.5	37.7	40.2	76.2	49.3	28.6

SD, standard deviation; DA, distance from the anteroinferior extremity of the acromion to the supraglenoid tubercle.

studies have varied widely: 5.4–67.7% for type I; 24.2–83% for type II; and 0–42.4% for type III. These data are in the review of the literature by Natsis et al.¹⁰ In our study, the frequency of each type of acromion using the classification of Bigliani et al.⁵ was 43.3% for type I; 47.7% for type II; and 9% for type III.

This large variability between the different authors may reflect the subjective nature of the classification method, the type of sample (dry scapulas, scapulas from cadavers or scapulas from living individuals), the population studied and the method used for analyzing the acromion (direct inspection, radiography or magnetic resonance).¹⁰

In analyzing the frequencies of the types of acromion in relation to age, we saw that acromion types II and III together were more frequent among individuals aged 50 years and over than among those aged 49 years and under: 62% and 50%, respectively. Individuals aged ≤ 49 years accounted for 50% of the acromia of type I and ≥ 50 years, only 38%. Vähäkari et al.⁷ studied radiographs from asymptomatic individuals aged 21 to 71 years and did not perceive any statistically significant differences in the types of acromion between the age groups.

In analyzing the frequencies of the acromion types in relation to sex, we saw that the proportion of type III was higher among females (16.8% versus 3.8%), while Paraskevas et al.¹⁷ found a greater percentage of type III in men (56.2% versus 43.7%) and of type I in women (56.5% versus 43.4%), just like in our study (55.5% versus 35.1%).

The classification system of Bigliani et al.⁵ is very useful and widely used, but it is purely visual, given that the interpretation is guided only by the meanings of the words flat, curved and hooked. Thus, this system presents great interobserver variability.

Hence, several authors have independently formulated different modifications to the original scheme and have proposed analyses of greater accuracy for the acromial curvature.^{4,11,13}

Epstein et al.¹³ proposed, also on the basis of visual classification, that the acromion should be classified as type II if the curvature occurred in the middle third and as type III if it occurred in the anterior third. In a more objective manner than these authors, Toivonen et al.⁴ conducted a retrospective review of radiographs in order to determine an objective method for classifying the shape of the acromion. They compared the “objective angle” (named the acromial angle) with the acromial types of the classification of Bigliani et al.⁵ and concluded that acromion type I had an acromial angle of 0° to 12° ; type II, 13° to 27° ; and type III, greater than 27° .

Other parameters have been proposed by other authors in order to analyze the influence of the morphology of the acromion as an etiological factor for RCIs. Among these, the influence of the thickness of the anterior third of the acromion has been cited as an etiological factor relating to subacromial pathological conditions.¹⁸

Another morphometric parameter is the acromial index (AI), which is obtained as the ratio between the distance from the glenoid cavity to the lateral border and the distance from the glenoid cavity to the lateral border of the humerus.^{19–21} In a study on a Brazilian population, Miyazaki et al.²¹ concluded that RCIs may be associated with greater AI, i.e. greater lateral projection of the acromion. In a subsequent study, Miyazaki et al.²² compared the AI in two different populations (Brazilian and Japanese) and concluded that this index was a

predictive factor for RCIs in the Brazilian population but not in the Japanese population.

Edelson and Taitz¹¹ proposed an inclination angle for the acromion and stated that it was associated with degenerative alterations such that the more horizontal the acromion was, the greater the degeneration would be.

Differing from that study, the present study did not analyze the association between acromial curvature and degenerative alterations. In our view, the main parameter is the comparison between the acromial inclination and the alterations to the size of the subacromial space.

Edelson and Taitz¹¹ also analyzed the height of the height of the coracoacromial arch and perceived that this was also associated with degenerative alterations to the acromion. These authors did not find degeneration in arches that were more than 15 mm above the supraglenoid tubercle, but 75% of their sample with degenerative alterations had an arch height of less than 12 mm.

Like in the study by Edelson and Taitz,¹¹ we proposed to analyze the height of the coracoacromial arch, but by using the angles that we created, in order to understand the extent to which variation in acromial curvature is capable of altering the space between the anteroinferior extremity of the acromion and the supraglenoid tubercle. Our evaluation on the means for the distance DA between the three different types of acromion showed statistical significance ($p = 0.037$). In relation to each of the three types of acromion, we showed that there were differences in the means for the angles β ($p = 0.008$) and θ ($p = 0.028$). In other words, among the angles proposed in our study, β and θ maintained a strict relationship with the length of the subacromial space.

One important factor is that measurements similar to those on samples of dry bone can be obtained by means of radiographs in lateral view of the scapula, i.e. “outlet view”.^{11,23,24} Likewise, the angles and height of the coracoacromial arch can be calculated.

Conclusion

The beta and theta angles proposed in our study can be used for morphometric analysis on the acromion, especially regarding its curvature, thereby contributing towards studies on diseases of the shoulder and aiding in surgical planning and in analysis on acromial inclination by means of radiography and magnetic resonance.

Conflicts of interest

The authors declare no conflicts of interest.

REFERENCES

1. Neer CS. Anterior acromioplasty for the chronic impingement syndrome in the shoulder: a preliminary report. *J Bone Joint Surg Am.* 1972;54(1):41–50.

2. Balke M, Schmidt C, Dedy N, Banerjee M, Bouillon B, Liem D. Correlation of acromial morphology with impingement syndrome and rotator cuff tears. *Acta Orthop*. 2013;84(2):178-83.
3. Musil D, Sadvovský P, Rost M, Stehlík J, Filip L. Relationship of acromial morphology and rotator cuff tears. *Acta Chir Orthop Traumatol Cech*. 2012;79(3):238-42.
4. Toivonen DA, Tuite MJ, Orwin JF. Acromial structure and tears of the rotator cuff. *J Shoulder Elbow Surg*. 1995;4(5):376-83.
5. Bigliani LU, Morrison DS, April EW. The morphology of the acromion and its relationship to rotator cuff tears. *Orthop Trans*. 1986;10:228.
6. Ikemoto RY, Bezerra AD, Monte FA, Telles RB, Fujiki EN, Porto LCK. Acrômio em forma de gancho: uma variação anatômica ou um processo degenerativo? *Rev Bras Ortop*. 1995;40(8):454-63.
7. Vähäkari M, Leppilahti J, Hyvönen P, Ristiniemi J, Päivänsalo M, Jalovaara P. Acromial shape in asymptomatic subjects: a study of 305 shoulders in different age groups. *Acta Radiol*. 2010;51(2):202-6.
8. Spencer EE Jr, Dunn WR, Wright RW, Wolf BR, Spindler KP, McCarty E, et al. Interobserver agreement in the classification of rotator cuff tears using magnetic resonance imaging. *Am J Sports Med*. 2008;36(1):99-103.
9. Karas V, Cole BJ, Wang VM. Role of biomechanics in rotator cuff pathology: North-American perspective. *Med Sport Sci*. 2012;57:18-26.
10. Natsis K, Tsikaras P, Totlis T, Gigis I, Skandalakis P, Appell HJ, et al. Correlation between the four types of acromion and the existence of enthesophytes: a study on 423 dried scapulas and review of the literature. *Clin Anat*. 2007;20(3):267-72.
11. Edelson JG, Taitz C. Anatomy of the coraco-acromial arch: relation to degeneration of the acromion. *J Bone Joint Surg Br*. 1992;74(4):589-94.
12. Oh JH, Kim JY, Lee HK, Choi JA. Classification and clinical significance of acromial spur in rotator cuff tear: heel-type spur and rotator cuff tear. *Clin Orthop Relat Res*. 2010;468(6):1542-50.
13. Epstein RE, Schweitzer ME, Fnieman BG, Fenlin JN, Mitchell DG. Hooked acromion: prevalence on MR images of painful shoulders. *Radiology*. 1993;187(2):479-81.
14. Joseph CMG, Sundeeep A, Sandip B. Rotator cuff tears: association with acromion angulation on MRI. *Clin Imaging*. 2012;36(6):791-6.
15. Di Mario M, Fraracci L. MR study of the intrinsic acromial angle in 74 symptomatic patients. *Radiol Med*. 2005;110(3):273-9.
16. Nikolaos TR, Soheil M, Suketu V, Edward E, Theofilos SK, John MI. The influence of the acromioclavicular joint degeneration on supraspinatus outlet impingement and the acromion shape. *J Orthop Surg*. 2009;17(3):331-4.
17. Paraskevas G, Tzaveas A, Papaziogas B, Kitsoulis P, Natsis K, Spanidou S. Morphological parameters of the acromion. *Folia Morphol (Warsz)*. 2008;67(4):255-60.
18. Snyder SJ, Karzel RP, Del Pizzo W, Ferkel RD, Friedman MJ. SLAP lesions of the shoulder. *Arthroscopy*. 1990;6(4):274-9.
19. Nyffeler RW, Werner CM, Sukthankar A, Schmid MR, Gerber C. Association of a large lateral extension of the acromion with rotator cuff tears. *J Bone Joint Surg Am*. 2006;88(4):800-5.
20. Torrens C, López JM, Puente I, Cáceres E. The influence of the acromial coverage index in rotator cuff tears. *J Shoulder Elbow Surg*. 2007;16(3):347-51.
21. Miyazaki AN, Fregoneze M, Santos PD, Silva LA, Martel EM, Debom LG, et al. Estudo radiográfico do índice acromial e sua relação com as lesões do manguito rotador. *Rev Bras Ortop*. 2010;45(2):151-4.
22. Miyazaki AN, Itoi E, Sano H, Fregoneze M, Santos PD, Silva LA, et al. Comparison between the acromion index and rotator cuff tears in the Brazilian and Japanese populations. *J Shoulder Elbow Surg*. 2011;20(7):1082-6.
23. Hyvönen P, Päivänsalo M, Lehtiniemi H, Leppilahti J, Jalovaara P. Supraspinatus outlet view in the diagnosis of stages II and III impingement syndrome. *Acta Radiol*. 2001;42(5):441-6.
24. Mayerhoefer ME, Breitensteiner MJ, Roposch A, Treit C, Wurnig C. Comparison of MRI and conventional radiography for assessment of acromial shape. *Am J Roentgenol*. 2005;184(2):671-5.