


Answer to Letter to the Editor Regarding the Article “Ligamentous Reconstruction of the Interosseous Membrane of the Forearm in the Treatment of Instability of the Distal Radioulnar Joint”

Resposta à Carta ao Editor referente ao artigo “Reconstrução ligamentar da membrana interóssea do antebraço no tratamento da instabilidade da articulação radioulnar distal”

Marcio Aurelio Aita¹  Ricardo Carvalho Mallozi¹ Willian Ozaki¹ Douglas Hideki Ikeuti¹
Daniel Alexandre Pereira Consoni¹ Gustavo Mantovani Ruggiero¹

¹ Department of Surgery, Orthopaedic and Traumatology, Hand and Microsurgery Division, Faculdade de Medicina do ABC, Santo Andre, SP, Brazil

Address for correspondence Marcio Aurelio Aita, Department of Orthopaedic and Traumatology, Faculdade Medicina ABC, Av. Principe de Gales, 821-Principe de Gales - Santo André, SP, 09060-650, Brazil (e-mail: marcioaita@me.com).

Rev Bras Ortop 2020;55(3):387–388.

Actually, the Distal Oblique Band (DOB), described by Moritomo,¹ is in the opposite direction. However, we performed an anatomical study and observed that the reconstruction of the DOB in the direction described by Moritomo is not ideal for the stabilization of the distal radioulnar joint (DRUJ). It is the most unstable, when compared with the technique employed here or with transverse tunnels.

We have also found that there is a “distal tract” (► **Fig. 1**) of the interosseous membrane,² more dorsal and in the direction that we describe our technique³ (► **Fig. 3**), which is more robust than the DOB (► **Fig. 2**), and that its fibers terminate in the triangular fibrocartilage complex (TFCC).

We believe that the distal tract of the interosseous membrane, the oblique radius band for the ulna, from proximal to distal, has a higher value than the DOB, with respect to the stability of the DRUJ.

Maybe it is proper to correct our paper (► **Fig. 3**), checking if no one else has described this “distal tract.”

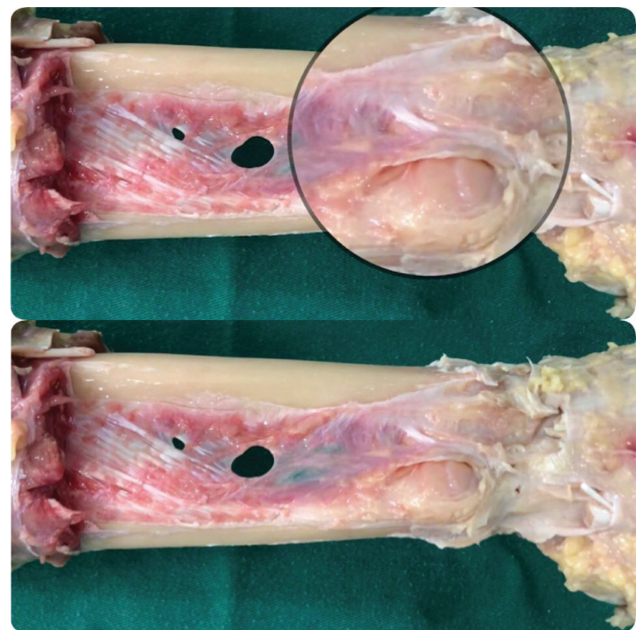


Fig. 1 Distal Tract of the interosseous membrane.

received
September 24, 2019
accepted
October 3, 2019

DOI <https://doi.org/10.1055/s-0039-3402466>.
ISSN 0102-3616.

Copyright © 2020 by Sociedade Brasileira de Ortopedia e Traumatologia. Published by Thieme Revinter Publicações Ltda, Rio de Janeiro, Brazil

License terms



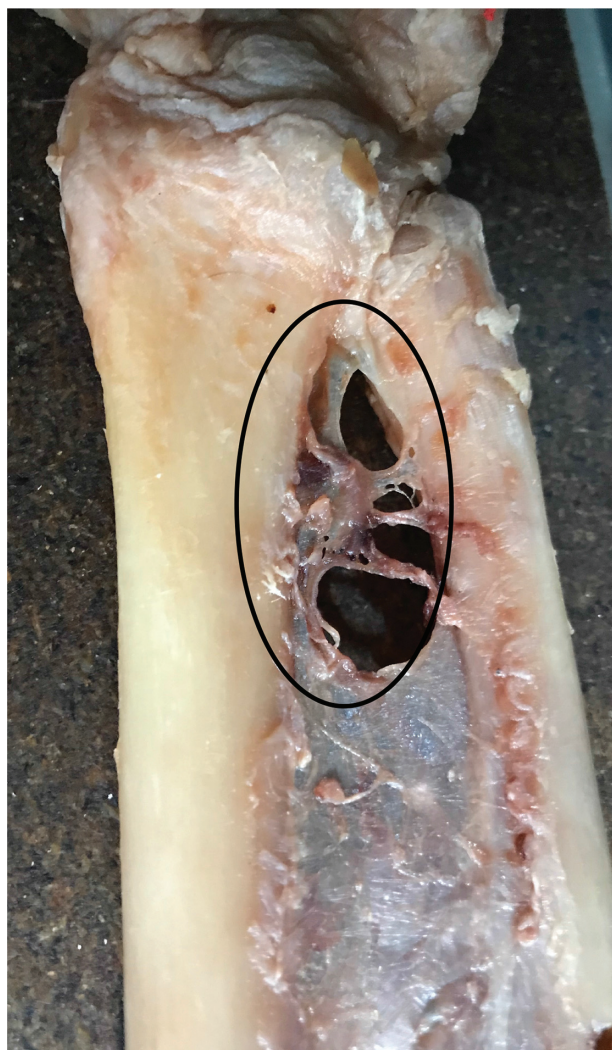


Fig. 2 Distal Oblique Band (DOB).

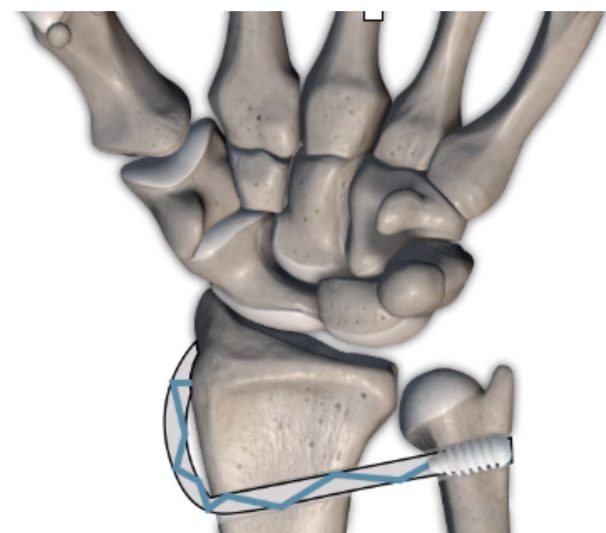


Fig. 3 Reconstruction of the distal interosseous membrane with braquiorradialis.

Conflict of Interests

The authors have no conflict of interests to declare.

References

- 1 Moritomo H. The distal interosseous membrane: current concepts in wrist anatomy and biomechanics. *J Hand Surg Am* 2012;37(07): 1501–1507
- 2 Gabl M, Zimmermann R, Angermann P, et al. The interosseous membrane and its influence on the distal radioulnar joint. An anatomical investigation of the distal tract. *J Hand Surg Br* 1998; 23(02):179–182
- 3 Aita MA, Mallozi RC, Ozaki W, Ikeuti DH, Consoni DAP, Ruggiero GM. Ligamentous reconstruction of the interosseous membrane of the forearm in the treatment of instability of the distal radioulnar joint. *Rev Bras Ortop* 2018;53(02):184–191