


# Clinical and Radiographic Evaluation of Patients Operated by the Bristow-Latarjet Technique with a Minimum Follow-Up of 20 Years\*

## *Avaliação clínica e radiográfica de pacientes operados pela técnica de Bristow-Latarjet com seguimento mínimo de 20 anos*

Jaime Guiotti Filho<sup>1</sup>  Marcelo Carvalho Leite<sup>1</sup> Antônio Carlos Wall Borges<sup>1</sup> Gabriel Terra de Souza<sup>1</sup> Otaniel Figueiredo do Prado<sup>1</sup>

<sup>1</sup> Shoulder and Elbow Service, Instituto Ortopédico de Goiânia, Goiânia, GO, Brazil

Address for correspondence Jaime Guiotti Filho, Instituto Ortopédico de Goiânia, Rua T-27, 819, setor Bueno, Goiânia, GO, 74210-030, Brazil (e-mail: jaimeguiotti@gmail.com).

Rev Bras Ortop 2020;55(4):455–462.

### Abstract

**Objective** To verify the results of 27 patients submitted to surgery from 1990 to 1997 by the Bristow-Latarjet technique for the treatment of anterior traumatic instability of the shoulder. The analysis included the possible complications, especially the appearance of arthropathy.

**Methods** The subjective clinical evaluation was performed through a questionnaire answered by the patients, and the objective evaluation was performed using the Rowe et al. score. The radiographic evaluation was performed using the anteroposterior (true) incidence to detect signs of shoulder arthrosis, according to the classification of Samilson and Prieto, as well as the apical oblique and the Bernageau and Patte incidences to verify the consolidation of the bone graft, the position of the screw and of the graft, and signs of the release of the synthesis material. These evaluations were performed by two examiners at different times without interference between them.

**Results** In the subjective assessment of the patients, 93% were fully recovered, and, in the objective evaluation, the average was 95 points on the Rowe et al. score. Complications related to coracoid placement were not found. The degree of arthropathy of the shoulders, according to the Samilson and Prieto classification, presented an average of seven mild cases, two moderate cases and one severe case. In total, 17 patients did not present arthropathy.

**Conclusion** Between the first and second evaluations, there was no change in the efficacy of the Bristow-Latarjet technique. The careful observation of the criteria of the technique was fundamental to avoid complications. The occurrence of arthropathy in

### Keywords

- ▶ shoulder dislocation
- ▶ joint instability
- ▶ shoulder joint
- ▶ follow-up studies

\* Study performed at the Center of Studies of Instituto Ortopédico de Goiânia, Goiânia, GO, Brazil.



the long term was not relevant in our evaluation. Based on the evidences of the present study, the surgical procedure alone is not the cause of the onset of the arthropathy, but the failure in its execution.

## Resumo

**Objetivo** Verificar os resultados do procedimento cirúrgico de 27 pacientes operados, durante o período de 1990 a 1997, pela técnica de Bristow-Latarjet para tratamento da instabilidade traumática anterior do ombro, considerando as possíveis complicações, e, principalmente, o aparecimento de artropatia.

**Métodos** A avaliação clínica subjetiva foi realizada por meio de um questionário respondido pelos pacientes, e a avaliação objetiva foi feita mediante o escore de Rowe et al. A avaliação radiográfica foi realizada usando as incidências anterioposterior (verdadeira), para visualizar a presença de sinais de artrose do ombro, segundo a classificação de Samilson e Prieto, e oblíqua apical e de Bernageau e Patte, para verificar a consolidação do enxerto ósseo, o posicionamento do parafuso, do enxerto, e os sinais de soltura do material de síntese. Estas avaliações foram realizadas por dois examinadores em tempos diferentes, sem interferência entre eles.

**Resultados** Na avaliação subjetiva dos pacientes, 93% estavam totalmente recuperados, e, na avaliação objetiva, a média foi de 95 pontos na escala de Rowe et al. Não foram encontradas as complicações relativas à colocação do enxerto de coracoide. O grau de artropatia dos ombros, de acordo com a classificação de Samilson e Prieto, apresentou uma média de sete casos suaves, dois casos moderados, e um caso grave. No total, 17 pacientes não apresentaram artropatia.

**Conclusão** Entre a primeira e a segunda avaliações, não houve alteração quanto à eficácia da técnica de Bristow-Latarjet. A observação cuidadosa dos critérios da técnica foi fundamental para evitar complicações. A ocorrência de artropatia em longo prazo não foi relevante em nossa avaliação. Pelas evidências do presente estudo, somente o procedimento cirúrgico não é a causa do surgimento da artropatia, mas a falha na sua execução.

## Palavras-chave

- ▶ luxação do ombro
- ▶ instabilidade articular
- ▶ articulação do ombro
- ▶ estudos de seguimento

## Introduction

Anterior dislocation of the shoulder occurs with great frequency in the general population, and especially among people who play contact sports.<sup>1</sup> The recurrence rate is higher in individuals aged  $\leq 20$  years, and approximately 50%<sup>2</sup> of the cases are surgically stabilized by various techniques. One of the surgical techniques employed to correct anterior shoulder instability is the Bristow-Latarjet technique. There are few long-term studies on complications, such as recurrence of instability, placement, non-consolidation, breakage of the graft fixation screw and, mainly, the occurrence of arthropathy.

For a long time, anterior instability of the shoulder was corrected only by open surgery, until the development of the arthroscopic surgery. With the dissemination and evolution of the arthroscopic surgery, open surgery began to be indicated for specific cases, due to the presence of bone lesions in the head of the humeral and anterior edge of the glenoid, known today as a bipolar lesion, which, in most patients, causes poor results by the arthroscopic technique.

The most used open surgery is the transfer of the coracoid process that was initially performed by Bristow, as described

by Helfet,<sup>2</sup> placing the graft under the subscapular muscle. In 1954, Latarjet<sup>3</sup> described the fixation of the coracoid process with a screw on the glenoid neck. This technique was modified by Patte et al.<sup>4</sup> who used a larger part of the coracoid attached to the glenoid neck with two screws. May<sup>5</sup> described the placement of the coracoid process with a screw.

After the publication of the article by Helfet,<sup>2</sup> the open surgical technique with transfer of the coracoid process for the correction of anterior shoulder instability became known as the Bristow-Latarjet surgery. In Brazil, the Bristow-Latarjet technique was widely disseminated by Ferreira Filho,<sup>6</sup> because it was the object of study for his doctoral thesis presented to the department of orthopedics of the School of Medicine of Universidade de São Paulo in 1984.

In 1987, the Bristow-Latarjet technique was considered non-physiological by Young and Rockwood<sup>7</sup> as well as by other authors,<sup>8-19</sup> who defended the possibility of complications resulting from incorrect placement, displacement and breakage of the screw, in addition to neurovascular injury and arthritis, reactions that would already be sufficient for the contraindication of the surgical technique.

Weaver and Derkesh,<sup>20</sup> in a comparative study with the Bankart surgery, did not find the high rate of complications attributed to the Bristow-Latarjet technique.

In 1998, in order to evaluate the results and complications of the surgical technique, Guiotti Filho et al.<sup>21</sup> evaluated, for 7 years, 56 patients submitted to surgery by the Bristow-Latarjet technique for the treatment of anterior traumatic instability of the shoulder, and they concluded that the surgery was effective, which was corroborated the accumulated experience.

There are few studies published with a follow-up longer than 15 years on the Bristow-Latarjet surgery used for anterior shoulder instability. Gordins et al.<sup>22</sup> performed a comparison study of their first Bristow-Latarjet surgeries with a mean follow-up of 33 years, which motivated us to review our cases.

The objective of the present work was to perform a retrospective evaluation of the results and complications of the Bristow-Latarjet technique, with a minimum follow-up of 20 years, in patients operated by the same surgeon. To present the comparative data, the 56 participants of the study by Guiotti Filho et al.<sup>21</sup> were invited for a new assessment between 20 and 27 years since the date of the surgery to verify the current situation of the affected shoulder, considering the possible complications, and mainly regarding the onset of arthropathy.

## Materials and Methods

From 1990 to 1997, 80 patients were submitted to the Bristow-Latarjet surgery by the same surgeon for the treatment of traumatic and unidirectional anterior recurrent dislocation of the shoulder associated with Hill Sachs injury and Bankart bone injury. The Bristow-Latarjet surgery was indicated for patients whose radiographic exams presented evidence of these bone lesions.

The Bristow-Latarjet surgical procedure was performed by deltopectoral approach, opening the subscapular and "L" capsule for a judicious placement of the coracoid graft in the vertical position, with its inferior side facing the head of the humerus, anterior and below the equator of the glenoid, fixed with a screw parallel to the articular surface, reaching the posterior cortical and passing it by 2 mm. In total, 56 of these 80 patients had postsurgical follow-up between 1990 and 1997, and the results were published by Guiotti Filho et al;<sup>21</sup> in the short term, complications related to the graft and arthropathy were not found.

In continuity with the aforementioned study, the present work evaluated the postoperative period with a minimum follow-up of 20 years since the date of the surgery of these same patients; however, only 27 were found and accepted this evaluation. The 29 patients who did not reply to our contact were excluded from the study. The objective was to verify the current condition of these 27 patients and to evaluate the surgical procedure performed at the time. All 27 patients included in the present study were eligible for evaluation. Of the 27 patients, 1 had an axonal lesion of the axillary nerve before the surgery. The patient recovered, but evolved with deltoid atrophy.

Gender: Age at the time of the surgery: \_\_\_ Current age:

1. Did you recover? Yes( ) Almost( ) No( )
2. Do you feel pain during movement? Never( ) Sometimes( ) Daily( )
3. Do you feel any pain? Never( ) Sometimes( ) Daily( )
4. Do you feel any discomfort during daily activities? No( ) Sometimes( ) Yes( )
5. Do you think you need to have surgery again? Yes( ) I don't know( ) No( )
6. Have you regained your throwing ability? Yes( ) Not completely( ) No( ) My dominant arm wasn't the one to have surgery( )
7. Do you avoid any movement in fear that the shoulder will dislocate? Yes( ) No( ) I avoid external rotation( )
8. What is your satisfaction level regarding the surgery? Very satisfied ( ) Satisfied ( ) Not completely satisfied( ) unsatisfied( ).

**Fig. 1** Collection instrument – subjective questionnaire. Source: Gordins et al.<sup>22</sup>

The objective evaluation was performed through physical examination to verify the range of motion, the pain, and through apprehension tests, and the subjective evaluation was performed by means of a questionnaire answered by the patients (► **Figure 1**). The radiographic evaluation performed to visualize signs of arthropathy was made in the anteroposterior (AP) incidence (true), whose degrees were determined according to the classification of Samilson and Prieto<sup>23</sup> as mild arthropathy (osteophyte < 3 mm in the humerus and glenoid), moderate arthropathy (osteophyte between 3 mm and 7 mm in the humerus and glenoid) and severe arthropathy (osteophyte > 8 mm in the humerus and glenoid, with decreased articular space and sclerosis). The radiographic evaluation to verify bone graft consolidation, position of the screw and of the graft, and signs of laxity of the synthesis material was made using the Bernageau and Patte<sup>24</sup> and apical oblique<sup>25</sup> incidences. These assessments were performed only on the operated shoulder by two examiners identified in the present study as examiner 1 (E1) and examiner 2 (E2), at different times and without interference between them.

The interviews with the patients occurred between February and March 2018 after the approval of the Ethics Committee, under protocol no. 2,383,660, after the patients signed the free and informed form, and following a subjective questionnaire protocol. The functional scale of Rowe et al.<sup>17</sup> (► **Table 6**) was completed and evaluated postoperatively.

## Results

The present study evaluated 27 patients 20 years after they were submitted to the Bristow-Latarjet surgery. At the time of the surgery, the 27 patients were between 17 and 59 years of age, and 85% were male, and 15% were female. The age at the first dislocation ranged from 16 to 49 years. The sport practiced by the majority (41%) was soccer, and the affected shoulder was the right one in 55% of the cases, and the left in 45%. The mean time from the first dislocation until the surgery was performed was 48 months. The participants are currently aged 37 to 79 years (► **Table 1**).

In the subjective approach, according to their answers, 25 patients (93%) were considered recovered, and 2 (7%), not fully recovered. Of the 27 patients who were questioned about feeling pain, 4 (15%) reported feeling pain sometimes

**Table 1** Demographic index

Gender		
Gender		Results
Male		23
Female		4
Age		
Mean age of the patients (years)		52 (37-74)
Age group		Results
≤ 20		0
21 to 40		3
41 to 60		20
61 to 80		4
> 80		0
Age at the first dislocation		
Mean age at the first dislocation (years)		25 (16-49)
Age group		Results
≤ 20		8
21 to 40		17
41 to 60		2
61 to 80		0
> 80		0
Sports previously practiced		
Sports		Results
Gym workout		1
Basketball		1
Capoeira		1
Soccer		11
Judo		1
Horseback riding		1
Swimming		4
No		6
Not informed		1
Affected side		
Right		15
Left		12

when moving the affected arm, 2 (7%) said they felt pain when performing daily activities, 2 (7%) would like to have a better recovery, 10 (37%) reported having recovered the ability to throw, and 2 (7%) said they avoided certain movements due to fear of dislocating the shoulder. When questioned about the satisfaction with the results after surgery, 21 (78%) considered themselves very satisfied, 5 (18%) were satisfied, and 1 (4%) was not completely satisfied.

The degree of shoulder arthropathy assessed by the 2 examiners (► **Table 2**), according to the Samilson and Prieto classification, presented an average of 7 mild cases, 2 moderate cases, and 1 severe case (► **Figure 2**), who had his/her

**Table 2** Representation of the degree of arthropathy according to the Samilson and Prieto classification

Anteroposterior (true) incidence			
Classification	Examiner 1	Examiner 2	Average
Normal	17	17	17
Mild (3 mm)	7	7	7
Moderate (3-7 mm)	2	2	2
Severe (> 8 mm)	1	1	1

Note: Only one patient presented severe arthrosis according to the classification.<sup>16</sup>

first episode of dislocation after 22 years of age, and evolved with long-term deltoid muscle atrophy. This patient had been diagnosed with axillary nerve injury by electroneuromyography before the surgery was performed, a fact that may have contributed to the outcome of severe arthrosis. The remaining 17 patients did not present arthropathy, as seen in ► **Figure 3**.

► **Table 3** shows the correlation of age with the degree of arthropathy and the restriction of external rotation. In 12 patients who had the first dislocation before turning 22 years old, no case of severe arthropathy was observed. The 2 cases that presented more advanced arthropathy were considered by the 2 examiners moderate arthropathy, and both presented external rotation restriction > 10°.

Out of the 15 patients who dislocated the shoulder after turning 22 years old, 1 had a moderate degree of arthropathy, with restriction of the external rotation > 10°.

The 2 examiners observed a case of severe arthrosis, with restriction of external rotation > 15°.

In the objective and subjective evaluation (► **Table 4**) of the movements, there was recovery of the elevation and external rotation of the shoulder in most patients (22; 84%).

The apprehension sign became negative in the final evaluation in 24 (89%) of the patients, with no recurrence of instability. Out of the patients with positive apprehension, two had sporadic convulsions, and one had fracture of traumatic origin of the synthesis material (► **Figure 4**).

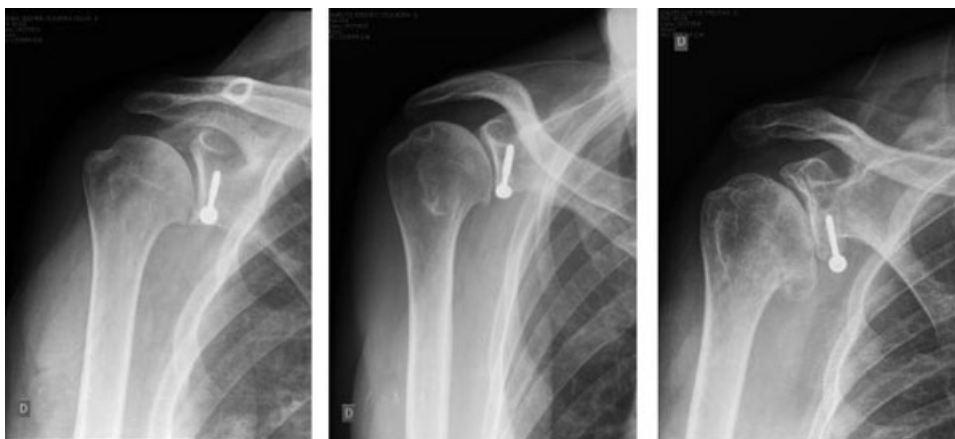In the evaluation of the Bernageau and Patte<sup>24</sup> and apical oblique<sup>25</sup> radiological incidences (► **Figure 5**), no patients showed signs of lack of bonegraft consolidation.

In one patient, the graft was placed more medially compared to the articular surface, a situation evaluated by E2 (► **Table 5**), but without clinical repercussion.

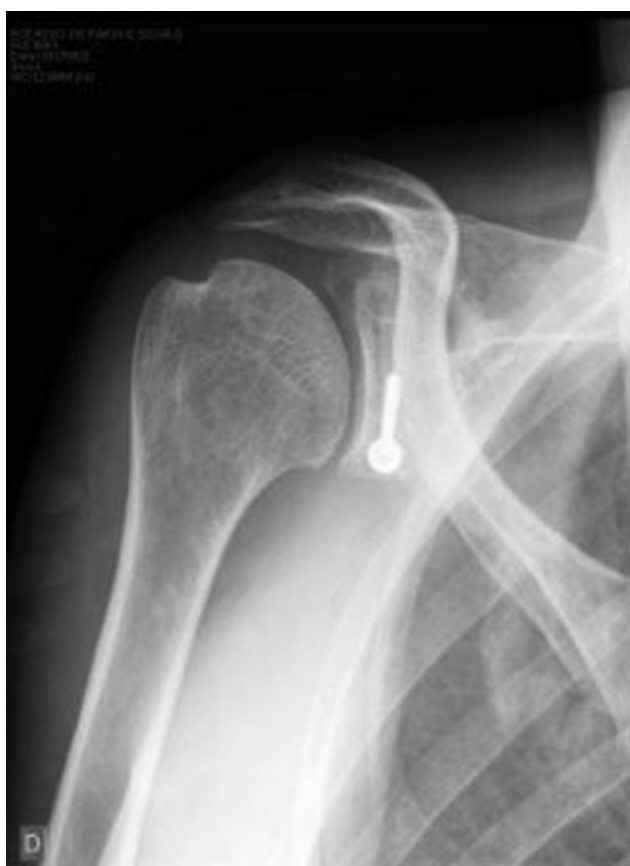There was no statistical difference between the assessments of the two examiners. The mean score in the Rowe et al.<sup>17</sup> scale (► **Table 6**) was significant: 95 points.

## Discussion

The present study had a mean follow-up of 24 years and included all patients operated by the Bristow-Latarjet procedure by the same surgeon from 1990 to 1997. Out of these



**Fig. 2** Degree of shoulder arthropathy.



**Fig. 3** Anteroposterior (AP) X-ray (Xr) of the shoulder. No arthropathy is observed. Consolidated graft and well-positioned screw.

patients, 26 (96%) were satisfied, and only 1 (4%) was not completely satisfied, with no alteration in comparison to the first study.<sup>21</sup>

The opening of the subscapular together with the L-shaped capsule was essential for the exposure of the glenoid, not influencing the final result of the external rotation, enabling the correct placement of the coracoid graft fixed with a screw parallel to the joints. This was considered of fundamental importance for the conclusive results, according to Guiotti Filho et al.<sup>21</sup>

In the objective evaluation of the movements, there was recovery of elevation and external rotation of the shoulder in most patients (22; 84%). Restriction of external rotation  $> 10^\circ$  was found in cases of moderate arthropathy, and, in cases of severe arthropathy, the restriction was  $> 15^\circ$ . Although the restriction of external rotation may influence arthropathy, it was not relevant in our evaluation.

Out of the 27 evaluated patients, only 3 had positive apprehension sign. From these, two had seizures without dislocation, and one had trauma with elevation and external shoulder rotation, evolving with a dislocation that, after reduction, was managed conservatively, without the need of a new surgery.

In the radiographic evaluation using the Bernageau and Patte<sup>24</sup> and apical oblique<sup>25</sup> incidences (– **Figure 6**), signs of non-consolidation of the coracoid graft were identified, as well as failure of the material of synthesis, as observed in the first study.<sup>21</sup>

In the present study, we dedicated special attention to the degree of arthropathy, mainly considering the time of postsurgical evolution. Our expectation was to find a higher incidence of arthropathy; however, we observed 17 (63%) cases of shoulders without signs of arthropathy, 7 (26%) cases of mild arthropathy, 2 (7%) of moderate arthropathy, and 1 (4%) case of severe arthropathy.

Gordins et al.<sup>22</sup> in a long-term study, used the age of 22 years as a parameter to assess patients who had dislocation before and after that age, and concluded that patients who had dislocations after the age of 22 years had a greater degree of arthropathy, even if it was difficult to explain, according to the conclusion of the work.

When we try to correlate the age with the degree of arthropathy and with the restriction of external rotation, we observe that 15 patients suffered their first episode of dislocation after the age of 22 years. However, only 1 presented severe arthropathy and associated external rotation restriction  $> 10^\circ$ ; therefore, in the present study, we did not find enough data to state that being older than 22 years of age in the first dislocation may be a determinant factor for the evolution of osteoarthritis.

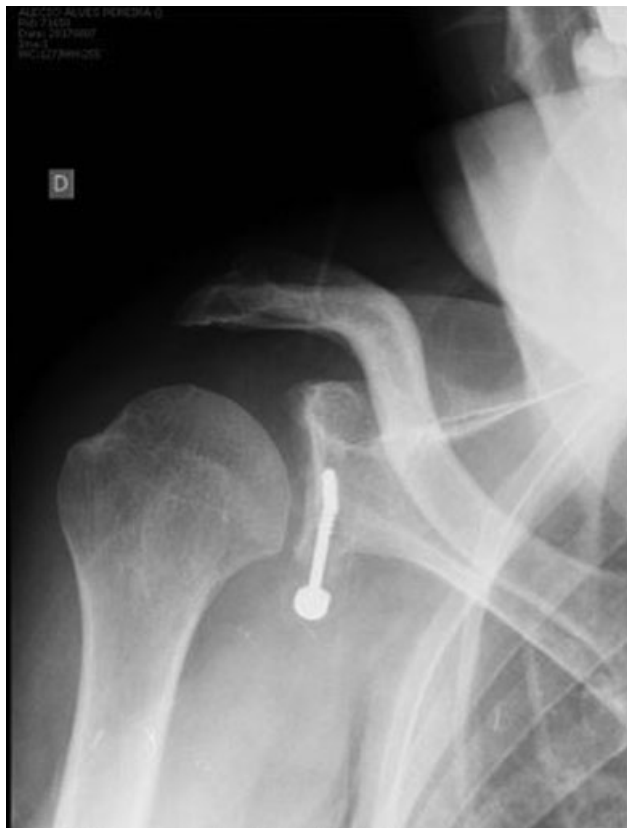**Table 3** Correlation of age with the degree of arthropathy and the restriction of external rotation

Age at the first dislocation	Degree of arthropathy								Rotation restriction > 10°							
	Normal		Mild		Moderate		Severe		Normal		Mild		Moderate		Severe	
	E1	E2	E1	E2	E1	E2	E1	E2	E1	E2	E1	E2	E1	E2	E1	E2
≤ 22	6	5	4	5	2	2	0	0	0	0	0	0	2	2	0	0
> 22	11	9	3	4	0	1	1	1	1	1	1	1	1	1	1	1

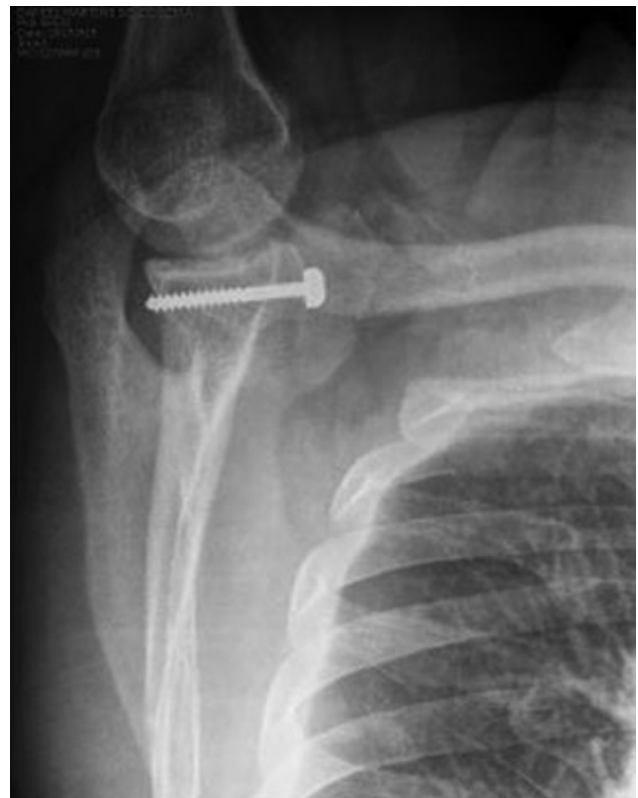Abbreviations: E1, examiner 1; E2, examiner 2.

**Table 4** Subjective and objective measurements of movements

Class	Tests	Average
Objective	External rotation (°)	83.8
	Elevation (°)	180
	Internal rotation in extension (cm)	1.8
Subjective	External rotation (°)	77.6
	Elevation (°)	180
	Internal rotation in extension (cm)	2.3



**Fig. 4** Anteroposterior Xr of the shoulder. Breakage of the screw, but a consolidated graft without signs of arthrosis, are observed.



**Fig. 5** Shoulder Xr in the Bernageau and Patte<sup>24</sup> incidence. The length of the screw, the position parallel to the glenoid, and the consolidated graft are observed.

Gordins et al.<sup>22</sup> reported that their arthropathy numbers in anterior shoulder dislocation are possibly inferior to those that could be expected, and they emphasized that arthropathy seen through the AP and axial incidences related to

anterior dislocation of the shoulder is a part of the natural history of this condition.

This puts into question whether the surgical procedure is the main etiological factor of arthropathy.<sup>26</sup> In addition, it

**Table 5** Results of the X-Ray in the Bernageau and Patte<sup>24</sup> and apical oblique incidences

Items	Examiner 1	Examiner 2	Average
<b>Was there consolidation of the bone graft?</b>			
Yes	27	27	27
No	0	0	0
<b>Proper positioning of the screws?</b>			
Yes	27	27	27
No	0	0	0
<b>Proper positioning of the grafts?</b>			
Yes	26	26	26
No	1	1	1
<b>Are there any signs of laxity of the synthesis material?</b>			
Yes	0	0	0
No	27	27	27

**Table 6** Result of the Rowe et al.<sup>17</sup> scale

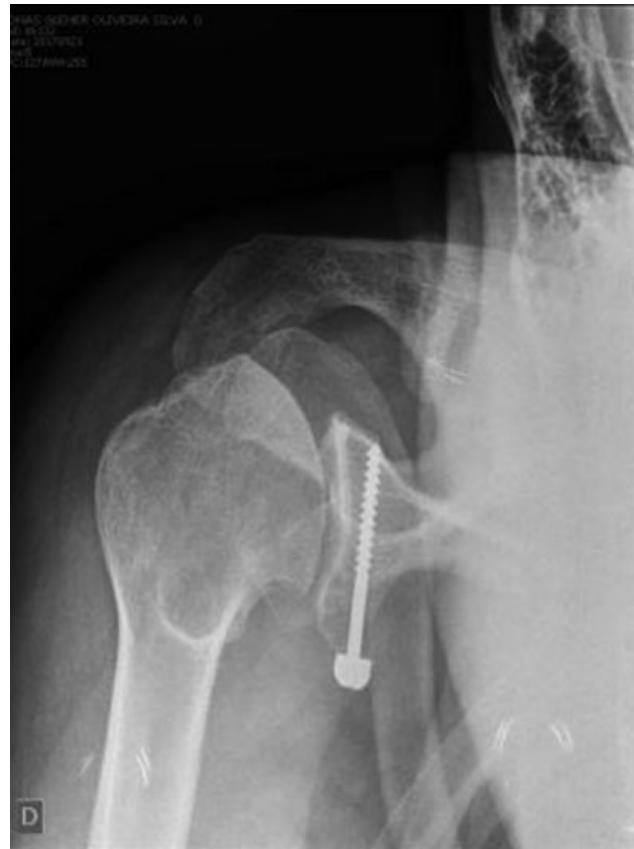Criteria	Average score	Rowe et al. <sup>17</sup> scale
Stability	49	0-50
Movement	18	0-20
Function	28	0-30
<b>Total</b>	<b>95</b>	<b>100</b>

was not possible to find any association between the degree of loss of external rotation after 2 years and arthropathy after 15 years. These findings are in accordance with the observations of Van der Zwaag et al.<sup>27</sup> who did not find a correlation between external rotation 6 months after surgery and the development of glenohumeral arthropathy 10 to 40 years later.

According to Gordins et al.<sup>22</sup> the degree of arthropathy after the Bristow-Latarjet procedure seems to follow the natural history of the shoulder instability in relation to common arthropathic degeneration over time. The postoperative restriction of external rotation does not increase the posterior arthropathy. The classification of arthropathy varies according to the radiologic observer, and this is in line with the previous studies by Gordins et al.<sup>22</sup>

It is suggested that further studies should be conducted, and a comparative study of the operated side with the opposite side is necessary to perform a better evaluation of the onset and evolution of the arthropathy. Only then it would be possible to conclude if the arthropathy found in these cases is part of the natural history or arises as a consequence of the surgical procedure.

Hovellius et al.<sup>28</sup> reported a satisfaction rate of 98% 15 years after the Bristow-Latarjet repair, and the results found by them in this study were better than those of the first study performed by the aforementioned authors 2 to 5 years after the repair. They also concluded that occasional subluxations are not uncommon after the Bristow-Latarjet procedure, but have little influence on the long-term global



**Fig. 6** X-ray in the apical oblique incidence. The correct and ideal position of the screw in the posterior cortical is observed, as well as the consolidated graft and screw parallel to the glenoid surface.

outcomes.<sup>20,29,30</sup> We observed that improvement in the long-term results could occur, but in our assessment of subluxation it did not.

In the present study, the negative results found in 3 (11%) patients may be correlated with seizure history in 2 patients, and, in 1 patient, the dislocation occurred due to a new trauma, a situation that changed the position of the screw. The patient identified with severe arthropathy and severe restriction of external rotation presented an axonal lesion of the axillary nerve before surgery. Despite this, this patient did not present recurrence of the dislocation.

It is important to highlight that currently the preferred method is the placement of the horizontal graft fixed with two parallel screws, using the coracoacromial ligament to be sutured in the articular capsule, with the goal remaining the same.

## Conclusion

Between the first and second assessments, there was no change in the efficacy of the Bristow-Latarjet technique. Careful observation of the criteria of technique reported by us was fundamental to avoid complications. The occurrence of arthropathy in the long-term was not relevant in our evaluation. Based on the evidences of the present study, the surgical procedure alone is not the cause of the emergence of arthropathy, but rather the failure in its execution.

**Conflict of Interests**

The authors have no conflict of interests to declare.

**References**

- 1 Hovelius L. Incidence of shoulder dislocation in Sweden. *Clin Orthop Relat Res* 1982;(166):127–131
- 2 Helfet AJ. Coracoid transplantation for recurring dislocation of the shoulder. *J Bone Joint Surg Br* 1958;40(02):198–202
- 3 Latarjet M. A propos du traitement des luxations récidivantes de l'épaule. *Lyon Chir* 1954;49(08):994–997
- 4 Patte D, Bernageau J, Rodineau J, Gardes JC. [Unstable painful shoulders (author's transl)]. *Rev Chir Orthop Repar Appar Mot* 1980;66(03):157–165
- 5 May VR Jr. A modified Bristow operation for anterior recurrent dislocation of the shoulder. *J Bone Joint Surg Am* 1970;52(05):1010–1016
- 6 Ferreira Filho AA. Tratamento de luxação anterior recidivante do ombro pela técnica Bristow-Latarjet [tese]. São Paulo: Faculdade de Medicina, Universidade de São Paulo; 1984
- 7 Young DC, Rockwood CA Jr. Complications of a failed Bristow procedure and their management. *J Bone Joint Surg Am* 1991;73(07):969–981
- 8 Artz T, Huffer JM. A major complication of the modified Bristow procedure for recurrent dislocation of the shoulder. A case report. *J Bone Joint Surg Am* 1972;54(06):1293–1296
- 9 Bach BR Jr. Arthroscopic removal of painful Bristow hardware. *Arthroscopy* 1990;6(04):324–326
- 10 Bach BR Jr, O'Brien SJ, Warren RF, Leighton M. An unusual neurological complication of the Bristow procedure. A case report. *J Bone Joint Surg Am* 1988;70(03):458–460
- 11 Clancy MJ. False aneurysm of the axillary artery as a complication of the modified Bristow procedure. *Injury* 1987;18(06):427–428
- 12 Fee HJ, McAvoy JM, Dainko EA. Pseudoaneurysm of the axillary artery following a modified Bristow operation: report of a case and review. *J Cardiovasc Surg (Torino)* 1978;19(01):65–68
- 13 Iftikhar TB, Kaminski RS, Silva I Jr. Neurovascular complications of the modified Bristow procedure. A case report. *J Bone Joint Surg Am* 1984;66(06):951–952
- 14 Lower RF, McNiesh LM, Callaghan JJ. Computed tomographic documentation of intra-articular penetration of a screw after operations on the shoulder. A report of two cases. *J Bone Joint Surg Am* 1985;67(07):1120–1122
- 15 Nielson AB, Nielsen K. The modified Bristow procedure for recurrent anterior dislocation of the shoulder. Results and complications. *Acta Orthop Scand* 1982;53(02):229–232
- 16 Richards RR, Hudson AR, Bertoia JT, Urbaniak JR, Waddell JP. Injury to the brachial plexus during Putti-Platt and Bristow procedures. A report of eight cases. *Am J Sports Med* 1987;15(04):374–380
- 17 Rowe CR, Zarins B, Ciuillo JV. Recurrent anterior dislocation of the shoulder after surgical repair. Apparent causes of failure and treatment. *J Bone Joint Surg Am* 1984;66(02):159–168
- 18 Strömqvist B, Wingstrand H, Egund N. Recurrent shoulder dislocation and screw failure after the Bristow-Latarjet procedure. A case report. *Arch Orthop Trauma Surg* 1987;106(04):260–262
- 19 Zuckerman JD, Matsen FA 3rd. Complications about the glenohumeral joint related to the use of screws and staples. *J Bone Joint Surg Am* 1984;66(02):175–180
- 20 Weaver JK, Derkash RS. Don't forget the Bristow-Latarjet procedure. *Clin Orthop Relat Res* 1994;(308):102–110
- 21 Guiotti Filho J, Borges AC, Rabelo LW, Daher WR. Instabilidade anterior do ombro: tratamento cirúrgico pela técnica de Bristow-Latarjet. *Rev Bras Ortop* 1998;33(09):724–730
- 22 Gordins V, Hovelius L, Sandström B, Rahme H, Bergström U. Risk of arthropathy after the Bristow-Latarjet repair: a radiologic and clinical thirty-three to thirty-five years of follow-up of thirty-one shoulders. *J Shoulder Elbow Surg* 2015;24(05):691–699
- 23 Samilson RL, Prieto V. Dislocation arthropathy of the shoulder. *J Bone Joint Surg Am* 1983;65(04):456–460
- 24 Bernageau J, Patte D. Le profil glenoïde. *J Traumatol Sport* 1984;1(01):15–19
- 25 Garth WP Jr, Slappeg CE, Ochs CW. Roentgenographic demonstration of instability of the shoulder: the apical oblique projection. A technical note. *J Bone Joint Surg Am* 1984;66(09):1450–1453
- 26 Hawkins RJ, Angelo RL. Osteoarthrosis Glenohumeral. A late complication of the Putti-Platt repair. *J Bone Joint Surg Am* 1990;72(08):1193–1187
- 27 Van der Zwaag HM, Brand R, Obermann WR, Rozing PM. Osteoarthrosis glenohumeral after Putti-Platt. *J Shoulder Elbow Surg* 1999;8(03):252–258
- 28 Hovelius L, Sandström B, Sundgren K, Saebö M. One hundred eighteen Bristow-Latarjet repairs for recurrent anterior dislocation of the shoulder prospectively followed for fifteen years: study I—clinical results. *J Shoulder Elbow Surg* 2004;13(05):509–516
- 29 Hill JA, Lombardo SJ, Kerlan RK, et al. The modification Bristow-Helfet procedure for recurrent anterior shoulder subluxations and dislocations. *Am J Sports Med* 1981;9(05):283–287
- 30 Uhorchak JM, Arciero RA, Huggard D, Taylor DC. Recurrent shoulder instability after open reconstruction in athletes involved in collision and contact sports. *Am J Sports Med* 2000;28(06):794–799