

# Long-Term Outcome of Valgus Osteotomy and Fixation with Double Angled Dynamic Hip Screw for Nonunion Fracture of the Neck of the Femur in Young Adults

## *Desfecho a longo prazo da osteotomia valgizante e fixação com parafuso dinâmico de quadril de ângulo duplo de fratura não consolidada do colo femoral em adultos jovens*

Anmol Sharma<sup>1</sup> Sandeep Gupta<sup>1</sup> Rajeev Kansay<sup>1</sup> Bharath Patil<sup>1</sup>

<sup>1</sup>Department of Orthopedics, Govt. Medical College and Hospital, Chandigarh, India

**Address for correspondence** Anmol Sharma, MS, DNB Orthopaedics, 5728, Modern Housing Complex, Manimajra, Chandigarh, India – 160101 (e-mail: anmolsharma13@gmail.com).

Rev Bras Ortop 2022;57(6):962–967.

### Abstract

**Objective** To evaluate the long-term results of valgus intertrochanteric osteotomy fixed with double angled dynamic hip screw for nonunion fracture of the neck of the femur in young adults. This implant allows more freedom of fixation in the sagittal plane. Very few studies have evaluated the long-term outcome for treatment of nonunion in fractures of the neck of the femur.

**Methods** This is a prospective interventional study that included 20 patients with nonunion of the fracture of the neck of the femur aged < 60 years old without avascular necrosis of the head and significant resorption of the neck of the femur. A lateral closing wedge osteotomy was performed just above the lesser trochanter after inserting the Richard screw across the nonunion site, and it was fixed with a double-angle 120° barrel plate. The outcome was evaluated using union rate and the Harris Hip Score for functional outcome.

**Results** The average postoperative decrease in the Pauwels angle was of 28.9°. A total of 80% of the cases progressed to union within a mean duration of 7.53 months. The mean Harris Hip Score at the final follow-up was 86.45.

### Keywords

- ▶ femoral neck fractures
- ▶ femur neck fractures, ununited
- ▶ osteotomy

*Work developed at Department of Orthopedics, Govt. Medical College and Hospital, Chandigarh, India*

received  
December 1, 2020  
accepted  
March 8, 2021  
published online  
June 1, 2022

DOI <https://doi.org/10.1055/s-0041-1732391>.  
ISSN 0102-3616.

© 2022. Sociedade Brasileira de Ortopedia e Traumatologia. All rights reserved.

This is an open access article published by Thieme under the terms of the Creative Commons Attribution-NonDerivative-NonCommercial-License, permitting copying and reproduction so long as the original work is given appropriate credit. Contents may not be used for commercial purposes, or adapted, remixed, transformed or built upon. (<https://creativecommons.org/licenses/by-nc-nd/4.0/>)

Thieme Revinter Publicações Ltda., Rua do Matoso 170, Rio de Janeiro, RJ, CEP 20270-135, Brazil

**Conclusion** Valgus intertrochanteric osteotomy and fixation with a double angled dynamic hip screw is a reliable and effective method for preservation of head and promoting union in an ununited fractured neck of the femur in young patients.

## Resumo

**Objetivo** Avaliar os resultados a longo prazo da osteotomia intertrocantérica valgizante, fixada com parafuso dinâmico de quadril (DHS, na sigla em inglês) de ângulo duplo, em fraturas não consolidadas do colo femoral em adultos jovens. Este implante permite uma liberdade maior de fixação no plano sagital. Muito poucos estudos avaliaram o desfecho do tratamento a longo prazo da fratura não consolidada do colo femoral.

**Métodos** Trata-se de um estudo prospectivo de intervenção que incluiu 20 pacientes com fratura não consolidada do colo femoral com idade < 60 anos, sem necrose avascular da cabeça femoral e significativa reabsorção do colo femoral. Foi realizada uma osteotomia em cunha de fechamento lateral logo acima do trocânter menor após a inserção do parafuso tipo Richard no sítio do retardo da consolidação óssea, sendo fixada com uma placa cilíndrica de ângulo duplo de 120°. O resultado foi avaliado com o uso da taxa de consolidação e da escala Harris Hip Score quanto ao desfecho funcional.

**Resultados** Foi obtida uma redução pós-operatória média de 28,9° do ângulo de Pauwels. Os casos que evoluíram para a consolidação alcançaram 80%, em um período médio de 7,53 meses. A média da escala Harris Hip Score foi de 86,45 no acompanhamento final.

**Conclusão** A osteotomia intertrocantérica valgizante e a fixação com DHS de ângulo duplo é um método confiável e eficaz para a preservação da cabeça do fêmur, promovendo a consolidação de uma fratura não consolidada do colo femoral em pacientes jovens.

## Palavras-chave

- ▶ fraturas do colo femoral
- ▶ colo do fêmur
- ▶ fraturas não consolidadas
- ▶ osteotomia

## Introduction

Nonunion in fractures of the neck of the femur in young patients is a challenging complication to address and treat for any orthopedic surgeon. In developing countries like India, with most of the population living in rural areas, delayed presentation and nonunion of this fracture is not uncommon due to causes like lack of awareness, unavailability of proper treatment facility or faith in local bone setters for primary treatment. Hip replacement surgery in such cases is a difficult choice to make due to financial constraints, social habits like squatting/sitting cross legged and increasing life expectancy, which require the native head to be preserved for the maximum possible duration. Head preservation surgeries are aimed at improving either the biology, the biomechanics or both at the fracture site. The former group includes surgeries like muscle pedicle grafts<sup>1</sup> and vascularized fibula grafts.<sup>2</sup> These surgeries are technically very demanding, time consuming, and require a lot of expertise.

Fracture of the neck of the femur is caused by a shearing type of force that increases as the vertical inclination of the fracture line increases. It was postulated that if the vertical shear forces are converted to compressive forces by means of a valgus angulation osteotomy distal to the fracture, the healing at the fracture ends improves and the limb length shortening due to varus at the fracture and resorption of neck is also compensated.<sup>3</sup>

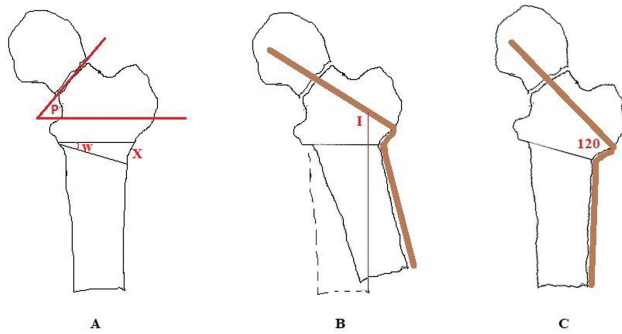
Most authors in the past have described internal fixation of the osteotomy site by a double angle blade plate.<sup>4-8</sup> This

requires a very precise insertion angle in the head, and even a minimal change in the direction of the blade may change the direction of the plate in the sagittal or in the coronal plane relative to the shaft of the femur, thus causing a displacement of the fracture fragments. Thus, we have used a double angled dynamic hip screw (DHS) that allows more freedom of fixation in the sagittal plane. Only a few studies have evaluated the long-term outcome for treatment of nonunion in fractures of the neck of the femur using this implant.<sup>9-13</sup>

## Materials and Methods

This was a prospective interventional study that included 20 patients with nonunion of fractures of the neck of the femur admitted to our institution that included 13 males and 7 females with a mean age of 40 years old (18-55 years old). Our inclusion criteria were any patient < 60 years old with nonunion in an intracapsular fracture neck with or without any previous fixation. The exclusion criteria were presence of changes of avascular necrosis (AVN) on plain radiography or magnetic resonance imaging (MRI) and significant resorption of the femoral neck with proximal fragment < 2.5 cm. Patients meeting the above criteria were investigated and, after preanesthetic clearance, were submitted to surgery.

Preoperatively, a lateral closing wedge osteotomy was planned just above the lesser trochanter using tracing paper over radiographs of 100% magnification and a radio-opaque marker placed over the lateral aspect of the thigh to confirm

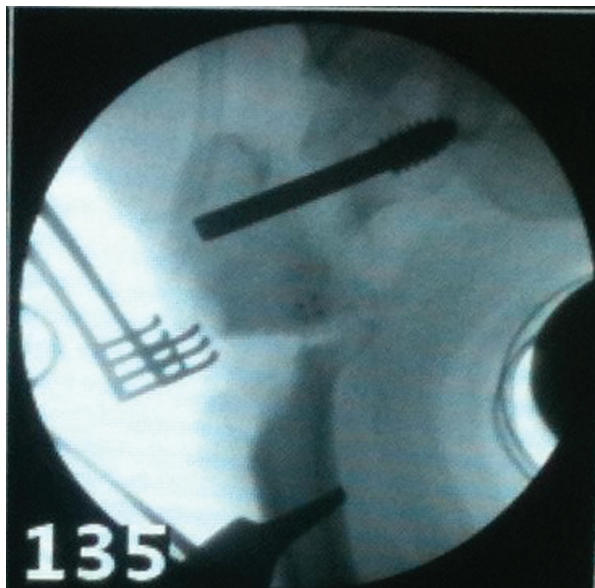


**Fig. 1** Calculation of insertion angle (I); W – wedge angle, X – wedge size; P – Pauwels Angle.

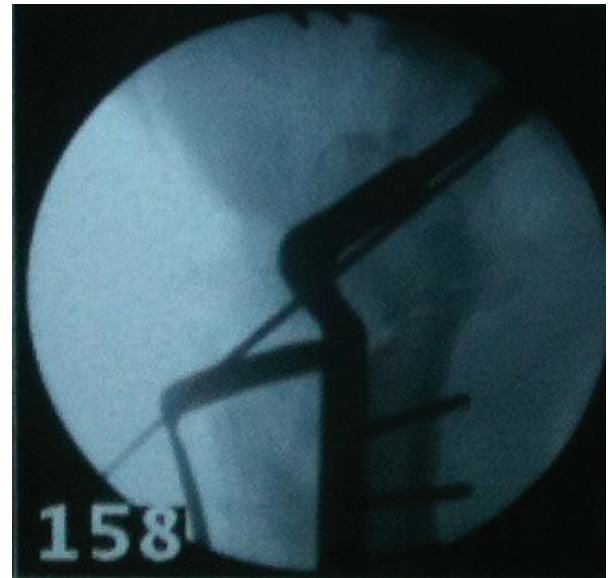
the magnification factor. The desired wedge angle (W) and wedge size (X) at the lateral femoral cortex were calculated so that the final angle at the fracture site after the osteotomy turned out to be  $\sim 30^\circ$ . The angle for insertion (I) of the guide pin for the Richard screw with a line parallel to the vertical axis of the body was also calculated by subtracting the wedge angle from  $120^\circ$ , that is, the implant angle ( $\rightarrow$  **Figure 1**).

All patients were operated on a standard traction table in the supine position under C-arm control. A standard lateral approach for the proximal femur was utilized for the osteotomy and for removal of any previous implants without opening the fracture site. A lateral closing wedge osteotomy was performed just above the lesser trochanter at the predetermined angle after inserting the guide pin and the Richard screw across the nonunion site aimed towards the center of the head and at the previously measured insertion angle from the vertical axis ( $\rightarrow$  **Figure 2**). A medial periosteal hinge was left intact at the osteotomy and the distal fragment was abducted in order to close the osteotomy site, which was further fixed with a double angle  $120^\circ$  barrel plate ( $\rightarrow$  **Figure 3**). Bone grafting was not done in any of the patients.

Postoperatively, active exercises of the hip and knee were started on the 1<sup>st</sup> postoperative day, and non-weight bearing



**Fig. 2** Intraoperative image after insertion of Richard screw.



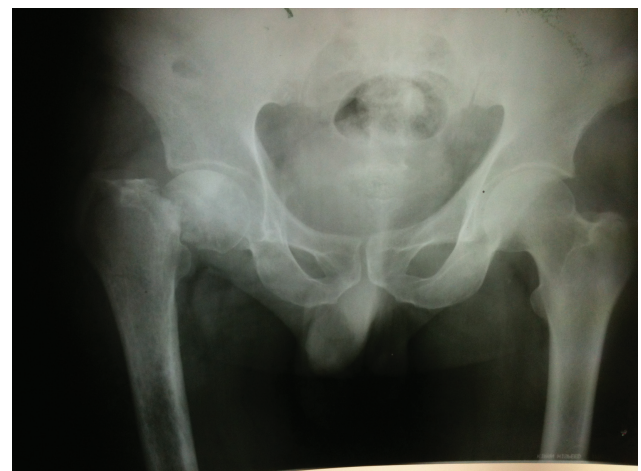**Fig. 3** Intraoperative image after completion of fixation of valgus osteotomy.

walking with a walker was started on the 2<sup>nd</sup> to the 3<sup>rd</sup> postoperative day according to the tolerance of the patient. The patients were followed-up monthly for 3 months and then every 2 months until 1 year, and then biannually (**figure 4–7**). Weight bearing was delayed until any radiographic signs of fracture healing were seen, and then, gradually, progressed to full weight bearing.

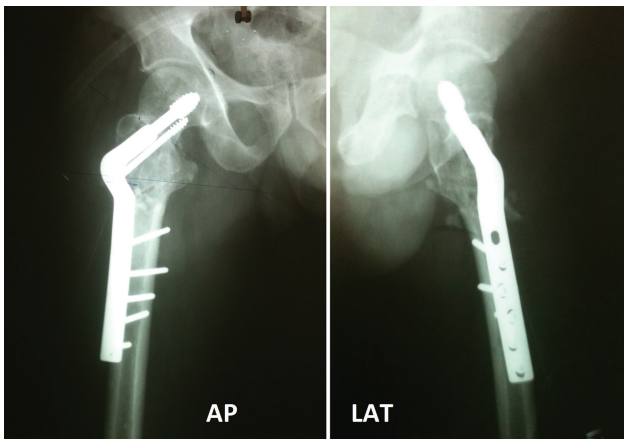
The present study complies with the ethical standards for experiments and studies on human subjects of our country, and the study was carried out after approval from the ethics committee of our institution. A written and informed consent was taken from every subject for participation in the present study before enrollment.

## Results

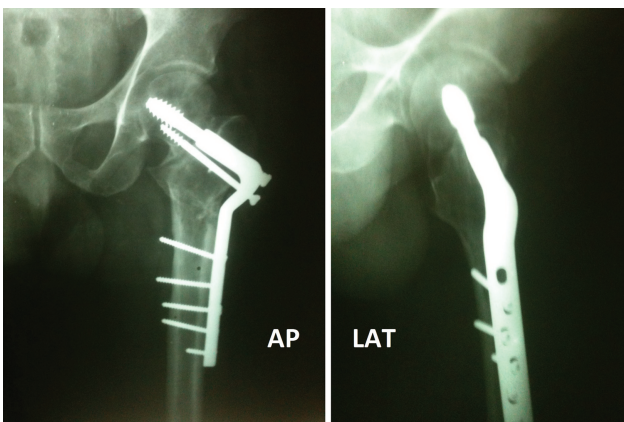
The mean duration since the injury was 9.2 months (5–14 months). Two of the fractures (10%) were located in the



**Fig. 4** Preoperative X-ray of the pelvis, anteroposterior view.



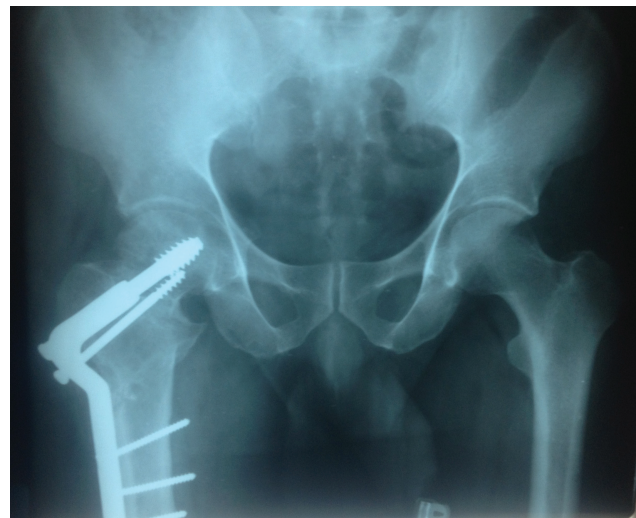**Fig. 5** Immediately postoperative X-rays.



**Fig. 6** Follow-up X rays at 3 months.

subcapital region of the neck, 6 (30%) in the basicervical area, and the remaining 12 (60%) were transcervical type fractures. The mean preoperative Pauwels angle was  $57.35^\circ$  ( $40\text{--}85^\circ$ ), and the mean limb shortening was 2.12 cm (1–4.5 cm). Five patients had undergone a previous surgery elsewhere (multiple cannulated screws in all 5 patients), leading to nonunion. The average postoperative Pauwels angle was  $28.45^\circ$  ( $20\text{--}45^\circ$ ), with a reduction of  $\sim 28.9^\circ$  after surgery. All patients had a reduction in limb shortening with an average postoperative shortening  $< 1$  cm. The mean follow up duration was of 3.9 years (4–7 years). A total of 16 cases progressed to union (80% union rate), with a mean time to union of 7.53 months (4.5–12 months), with 4 cases (20%) progressing to failure in the form of screw cut-out in 3 cases and head collapse with AVN in 1 patient. Out of these four failure cases, only one patient was previously operated with screw fixation. One patient, after healing at the osteotomy site progressed to develop type III AVN and screw backout. There were no other significant complications such as infection, thromboembolism etc.

The functional outcome was measured by the Harris Hip Score (HHS). The mean HHS at final follow-up was 86.45 (range 77–94). An excellent score was observed in 6 patients (30%), good in 12 (60%), fair in 2 (10%), and poor in none. Both patients with a fair outcome had an implant failure with



**Fig. 7** X ray of the pelvis at the final follow-up at 6 months, anteroposterior view.

screw cut-out in one and head collapse with AVN in the other patient.

## Discussion

Femoral neck fractures are associated with high rates of AVN and nonunion. The complication rate is affected by the geometry of the fracture and by any delay in treatment.<sup>14,15</sup> Fractures that remain untreated after 3 to 6 weeks are defined as neglected, and after  $> 90$  days as nonunion. Fractures untreated after 3 weeks have less chance of bone union after internal fixation alone.<sup>16</sup>

An intertrochanteric osteotomy is the procedure of choice for such cases in young patients. Pauwels described a V-Y shaped lateral closing intertrochanteric osteotomy in which a wedge is removed from the lateral half or  $2/3^{\text{rd}}$  of femur, and the distal fragment is fixed in abduction.<sup>3</sup> This converts the vertical fracture line to horizontal, thus converting the shearing forces into compressive forces. However, this osteotomy reduces the surface area of contact and is technically challenging.

Another alternative is a simple lateral closing wedge valgus intertrochanteric osteotomy, which provides a broader surface area for bony contact and is technically less demanding.<sup>4</sup> It also causes lateralization of the distal fragment, resulting in lengthening. Lengthening is usually desirable to compensate for the shortening that is present in these cases.

Fixation of the valgus intertrochanteric osteotomy has usually been described in the past with an angled blade plate, which is a technically more demanding procedure and has some disadvantages. Hammering the blade can displace the fracture, perforate or split the femoral head, and even a slight change in the direction of the blade makes fixation of the plate to the shaft very difficult. Also, the blade cannot be used to achieve compression across the fracture.<sup>7,8</sup>

The aforementioned drawbacks of the angled blade plate are overcome by the DHS, and the procedure is technically

simpler. But there is a theoretical higher risk of AVN of the head with the DHS due to rotatory motion, thermal necrosis, and disruption of intraosseous vascularity due to a larger diameter screw placement.<sup>11-13</sup> There have been very few studies in the past that have evaluated the long-term results of the valgus intertrochanteric osteotomy fixed with a double angled DHS.

Sharma et al.,<sup>9</sup> in a study of 22 cases of nonunion of the neck of the femur, evaluated the results of treatment with valgus intertrochanteric osteotomy (VITO) and fixation with a double angle DHS with a mean follow up of 18 months (12-38 months). The union rate at the nonunion site was 82%, and the mean duration of healing was 20 weeks (12-40 weeks). Two patients with pre-existing osteoarthritis of the knee with mild pain had no change in pain or deformity at the knee after osteotomy. Excellent results were seen in 4 patients, good in 10 patients, and fair in 2 patients. Poor outcome was seen in six patients, of which four had nonunion at the fracture site and two had AVN with collapse of the head after union of the fracture.

Pruthi et al.<sup>10</sup> evaluated the results of 28 cases of a repositioning intertrochanteric osteotomy and fixation with a 120° double angled barrel plate with a mean follow-up of 26.5 months. In 26 out of 28 cases, union at the fracture site occurred at an average of 5.2 months, and 2 cases had nonunion, of which 1 showed fair results, and the other case showed poor results. Results evaluated according to the Larson method of functional assessment were deemed good in 26 patients, fair in 1, and poor in 1 patient. Factors related to fair and poor outcome included subcapital fracture (poor in 1 out of 6), basicervical fracture (fair in 1 out of 8), type III Pauwels fracture (1 fair and 1 poor out of 22 cases), inability to achieve Pauwels angle up to 250° intraoperatively (1 fair and 1 poor out of 14), and surgery after 12 weeks of injury (1 fair and 1 poor out of 7 cases). Complications included cut-out in 1 case, nonunion in 2, superficial infection in 2, and limb length discrepancy in 6 cases. These findings were similar to those of our series.

Khan et al.<sup>11</sup> monitored the results of 16 patients of neglected and nonunion fracture of the neck of the femur who were treated with VITO and double angled DHS for a duration of 19 months (11-36 months). The average HHS increased from 66.6 points (range 55-75 points) before surgery to 88 points (range 75-95 points). Excellent results were achieved for 14 patients; 2 patients had poor results due to cut-out of the implant. In 14 of the 16 patients, the fracture progressed to satisfactory union after an average of 14.7 weeks (10-26.7 weeks)

Gill et al.,<sup>13</sup> in a prospective interventional study comprising of 36 patients of nonunion fracture of the neck of the femur were treated with VITO and double angled barrel plate and were followed-up for a duration of 3 years. Fracture union occurred in 32 cases over an average duration of 12 weeks (10 to 18 weeks). Of these 36 cases, 13 (36%) cases showed excellent result and 19 (53%) cases showed good result according to the modified Askin and Bryan criteria. The remaining 4 cases went on to develop implant failure and were classified as having a fair result due to loss of reduction,

implant cut-out and AVN of the femoral head. Avascular necrosis was observed in 7 cases, out of which 3 went on to develop union at the fracture site and even reversal of AVN. A total of 30 out of 36 cases were able to perform squatting after 3 years of follow-up.

In our study, satisfactory outcome was achieved in 90% of the patients with HHS calculated in the range of excellent and good score. This was similar to the results of most other studies. Factors associated with a fair outcome included implant cut-out, head collapse with AVN, preoperative Pauwels angle of 75°, subcapital fracture, and previous screw fixation for the fracture neck femur. An 80% union rate was achieved in a mean duration of 7.53 months (4.5-12 months). This was comparable to most of the other studies. A possible limitation of our study is the lack of any control group for comparison of outcomes.

## Conclusion

Valgus intertrochanteric osteotomy and fixation with a double angled DHS is a reliable and effective method for the preservation of the head and the promotion of union in an nonunited fracture of the neck of the femur in young patients. The implant is more forgiving than the blade plate in its placement in the sagittal plane, and the surgical technique is easily reproducible with a small learning curve.

### Contribution of the Authors

Sharma A. and Gupta S. were responsible for the conception and design of the study. Data acquisition was done by Sharma A., Gupta S. and Patil B.. Data analysis and interpretation was done Kansay R. and Gupta S.. Drafting of the article was done by Sharma A. and Patil B.. Critical revision was done by Gupta S. and Kansay R.. All authors have approved the final version of the manuscript.

### Financial Support

There was no financial support from public, commercial, or non-profit sources.

### Conflict of Interests

The authors have no conflict of interests to declare.

## References

- 1 Meyers MH, Harvey JP Jr, Moore TM. Delayed treatment of subcapital and transcervical fractures of the neck of the femur with internal fixation and a muscle pedicle bone graft. *Orthop Clin North Am* 1974;5(04):743-756
- 2 Hou SM, Hang YS, Liu TK. Ununited femoral neck fractures by open reduction and vascularized iliac bone graft. *Clin Orthop Relat Res* 1993;(294):176-180
- 3 Pauwels F. *Der Schenkelhalsbruch ein mechanisches Problem: Grundlagen des Heilungsvorganges, Prognose and kausale Therapie.* Stuttgart: Ferdinand Enke Verlag; 1935
- 4 Marti RK, Schüller HM, Raaymakers EL. Intertrochanteric osteotomy for non-union of the femoral neck. *J Bone Joint Surg Br* 1989; 71(05):782-787

- 5 Anglen JO. Intertrochanteric osteotomy for failed internal fixation of femoral neck fracture. *Clin Orthop Relat Res* 1997;(341): 175–182
- 6 Ballmer FT, Ballmer PM, Baumgaertel F, Ganz R, Mast JW. Pauwels osteotomy for nonunions of the femoral neck. *Orthop Clin North Am* 1990;21(04):759–767
- 7 Magu NK, Rohilla R, Singh R, Tater R. Modified Pauwels' intertrochanteric osteotomy in neglected femoral neck fracture. *Clin Orthop Relat Res* 2009;467(04):1064–1073
- 8 Sringari T, Jain UK, Sharma VD. Role of valgus osteotomy and fixation by double-angle blade plate in neglected displaced intracapsular fracture of neck of femur in younger patients. *Injury* 2005;36(05):630–634
- 9 Sharma M, Sood LK, Kanojia RK, et al. Valgus osteotomy for nonunion fracture neck femur. *Indian J Orthop* 2004;38(01): 88–91
- 10 Pruthi KK, Chandra H, Goyal RK, Singh VP. Repositioning osteotomy with dynamic hip screw with 120° double angled barrel plate fixation in fracture neck femur. *Indian J Orthop* 2004;38(01): 92–95
- 11 Khan AQ, Khan MS, Sherwani MK, Agarwal R. Role of valgus osteotomy and fixation with dynamic hip screw and 120 degrees double angle barrel plate in the management of neglected and ununited femoral neck fracture in young patients. *J Orthop Traumatol* 2009;10(02):71–78
- 12 Bansal P, Singhal V, Lal H, Mittal D, Arya RK. A convenient way to do valgus osteotomy for neglected fracture neck of femur. *Kathmandu Univ Med J (KUMJ)* 2013;11(42):147–151(KUMJ)
- 13 Gill S, Raj M, Singh P, Kumar D, Singh J, Rastogi P. Long term outcomes of neglected intracapsular fracture neck in young adults managed by modified double angle barrel plate (DABP) with intertrochanteric valgus osteotomy. *Afr J Trauma* 2015;4(02):35–44
- 14 Asnis SE, Wanek-Sgaglione L. Intracapsular fractures of the femoral neck. Results of cannulated screw fixation. *J Bone Joint Surg Am* 1994;76(12):1793–1803
- 15 Banks HH. Nonunion in fractures of the femoral neck. *Orthop Clin North Am* 1974;5(04):865–885
- 16 Sandhu HS, Sandhu PS, Kapoor A. Neglected fractured neck of the femur: a predictive classification and treatment by osteosynthesis. *Clin Orthop Relat Res* 2005;(431):14–20