

Induction of osteogenesis by demineralized homologous and xenograft bone matrix¹

Rosiris Dall'Agnol²

Marcos Brasilino de Carvalho³

Abraão Rapoport⁴

Maria Antonieta Longo Galvão Silva⁵

Dall'Agnol R, Carvalho MB, Rapoport A, Silva MALG. Induction of osteogenesis by demineralized homologous and xenograft bone matrix. *Acta Cir Bras* [serial online] 2003 May-Jun;18(3). Available from URL: <http://www.scielo.br/acb>.

ABSTRACT - The osteogenesis induction by demineralized bone matrix grafts remains as a challenge in the reconstructions of the mandible through homologous and xenografts or in implants in abdominal muscle. **Purpose:** Observed the behaviour of implants of demineralized bone matrix at the mandible (right side with homologous graft and left side with xenograft of pig). **Methods:** Experimental study with homologous and heterologous implants of demineralized bone matrix at the mandible and in ectopic muscle at the Center of Experimental Surgery of Heliópolis Hospital, Hospel, São Paulo, Brazil. In 6 white New Zeland rabbits, 46 grafts were performed being 23 with homologous (rabbit) and 23 with xenograft (pig). 12 homologous implants (6 at the right side of the mandible and 6 at abdominal muscle of the rabbit) and 12 heterologous implants of pigs (6 at the left side of the mandible and 6 at abdominal muscle rabbit) were performed with demineralized bone matrix. **Results:** Osteogenesis was assessed through histologic features after 30 and 60 days. After 1 rabbit dead, osteogenesis (mandible) were detected in 9 of 11 (82%) rabbits that received homologous matrix, in spite of heterologous implants showed osteogenesis in 6 out of 11 (54%) ($p=0,18$). The abdominal muscle showed induced osteogenesis in 3 out of 11(27%) animals with homologous and 0% with heterologous implants ($p=0,10$). **Conclusions:** Osteogenesis induction through homologous grafts in rabbit mandible and abdominal muscle were more effective than xenografts.

KEY WORDS - Osteogenesis. Homologous. Heterologous. Implants.

Introduction

The segmental resection is routine for primary and metastatic tumors of the mandible. The reconstructive options are very limited due to the large amount of soft tissues resected which may lead to serious damage to local vascularization. The repair of jaw defects using demineralized bone matrix grafts may overcome such inconveniences, as the reorganization of the bone is

done by alteration of the phenotypic expression of the fibroblasts at the place where it was implanted and, theoretically, independent of local vascularization. In repair and neof ormation by auto-induction of bone tissue, the degradation products of the dead matrix stimulate the growth of the inflammatory cells of the connective tissue and histiocytes. This process of neosteogenesis by auto-induction is conducted by cells derived from the host bed tissue, and the induced cell

-
1. Trabalho realizado no Departamento de Cirurgia Experimental do Hospital Heliópolis. São Paulo, Brasil.
 2. Cirurgiã – Dentista. Hospital Heliópolis. São Paulo, Brasil.
 3. Cirurgião do Serviço de Cirurgia de Cabeça e Pescoço do Hospital Heliópolis. São Paulo, Brasil.
 4. Cirurgião do Serviço de Cirurgia de Cabeça e Pescoço do Hospital Heliópolis. São Paulo, Brasil.
 5. Patologista pelo Departamento de Patologia da Santa Casa. São Paulo, Brasil.

is a fixed histiocyte or a young cell of the perivascular connective tissue. This differentiation of osteo-progenitor cells is caused by local alterations in cellular metabolic cycles that had not been known up to now.¹ Osteogenesis in experimental study was observed (1931) also in places other than the bone tissue, as it has been described that demonstrated intra-membranous ossification in the muscular fascia of guinea pigs after urinary tract epithelium grafting. Afterwards (1970), demineralized bone matrix was used in mice muscles, inducing bone formation.²

The aim of this work is to evaluate the competence of homologous and heterologous demineralized bone matrix grafts in stimulating osteogenesis by means of osteo-induction in the jaw and, ectopically, in rabbits abdominal muscle.

Methods

Twelve healthy albino rabbits of the New Zealand breed, males, weighing from 2,6 to 3,0 kilograms, an average age of six months were selected in two groups, chosen at random: the first group were sacrificed on the 30th post-operative day, and the second group on the 60th post-operative day, numbered from one to twelve following the sequence surgery submission.

The preparation of the bone matrix graft followed the technique described by Huggins & cols.,² and two types of grafts were prepared: homologous demineralized from the rabbit jaw also of the New Zealand breed, and xenograft demineralized bone of pig's jaw. The bone tissue donor animals were sacrificed mechanically without using any chemical process, with immediate removal, or within 8 hours, of the donor bone. In the rabbit the mandible was resected and in the pig, a bony section of 8 cm, free of soft tissues were washed with cold water and fragmented into smaller particles. The bone pieces were kept in a temperature of -4°C , and the demineralized was got by immersion in hydrochloric acid 0.6M until they became softened and translucent, the time ranged from 24 to 50 hours, depending on the size of the fragment and its bone density. The acid was changed every 24 hours and, after demineralization, the implants were washed with a sterile 0.9% serum solution for removing the acid, neutralizing the pH, and stored completely immersed in alcohol at 70%, at room temperature for the maximum period of 21 days. Immediately before the implants location were washed with a sterile 0.9% serum solution for removing the alcohol. The sterilization process of the material to be grafted was obtained chemically by the immersion in hydrochloric acid 0.6M for at least 24 hours. In the surgical

procedures, the animals were sedated with variable doses, depending on weight (0,5ml/kg on an average), of Acepran ® 1% (Acepromazina) intramuscularly and anesthetic induction with 1 ml to 2 ml of intravenous Thiopental ® (tiopental) depending on sensitivity.

The animal was immobilized on an operating table and a careful cleaning of the right and left sub-mandibular regions, as well as the abdominal region was performed with polyvinyl iodine pirrolidona 1%. Then the mandible was exposed through a right sub-mandibular incision of 1.5 cm in extent, and musculature divulsion up to the inferior edge of the bone and its angle were exposed, creating a bony defect by the removal of a segment 0.7cm in extent by 0.7cm height without interruption of mandibular integrity. The mandible defect was filled with the xenograft of a heterologous demineralized bone fragment of the same size fixed by mechanical impactation and recovered with masseter muscle and neighboring soft tissues. The operating wound was closed with mono-nylon (MN)5-0 and continuous suture of the skin. The same technique was repeated for the left side followed by a homologous demineralized bony matrix graft.

In the abdominal procedure, after asepsis and antisepsis 1cm incision was made in the skin, divulsion up to the abdominal musculature and a 0.5 X 0.5 X 0.5cm block of xenograft demineralized bone matrix was implanted on the right side followed by suture in muscle with MN 5-0. By same procedure, a homologous decalcified bone of matrix block was implanted on the left side.

With regard to postoperative period the animals received prophylactic antibiotic with 2,5 ml of Cefalotin Sodic of 1g, soluble, intramuscularly, immediately after surgery, and analgesic with Dipirona in drinking water for three days, with feeding restrictions.

The animals were randomly sacrificed, at time intervals of 30 and 60 days, with a lethal dose of intra peritoneal and intra cardiac thiopental. As soon as the death of each animal was verified, an incision was made to expose the operated places and location of the bone matrix of the left and right sides. The material was removed and immediately immersed in a 10% formol solution, and the blocks for histological analysis were identified with letters and numbers in the following manner:

CM: removed from the homologous bone matrix graft (rabbit bone) done on the left side of the mandible.
PM: removed from the xenograft bone matrix graft (pig bone) done on the right side of mandible.

CA: removed from the homologous bone matrix graft (rabbit bone) done in the abdominal musculature on the left side.

PA: removed from the xenograft bone matrix graft (pig bone) done in the abdominal musculature on the right side.

Then each block, for histological evaluation received a number and two letters, as well as a histological slide.

Results

It happened one post operative death due to probable stress after 12 hours. Within the post-operative period the animals light erythemas and edemas around the surgical wound. No secretions, dehiscence or infection was observed in any animals. Lack of appetite occurred in the first three days, controlled with analgesics and feeding based on honey and shredded carrot diluted in 20 ml water for hydration every two hours.

Macroscopically, it was observed if the reparation process had been occurred, if the implant was mobile or had integrated with the host bone or not. If had happened correction of the defect with an increase of bone tissue at the site of surgery, it was reported as an overlapping. In the cases where the defect was still present or the graft was mobile, not integrated to the host bone, non-repair was reported (one in 30 and 3 in 60 days).

In the cases in which there was macroscopic repair, normal host bone tissue, demineralized matrix with few cells, the presence of young, non mineralized bone matrix, and a large quantity of osteoblasts were histologically observed. These findings characterized a periostoid neoangiogenesis with an intra-membranous ossification pattern. (Figures 1 and 2).

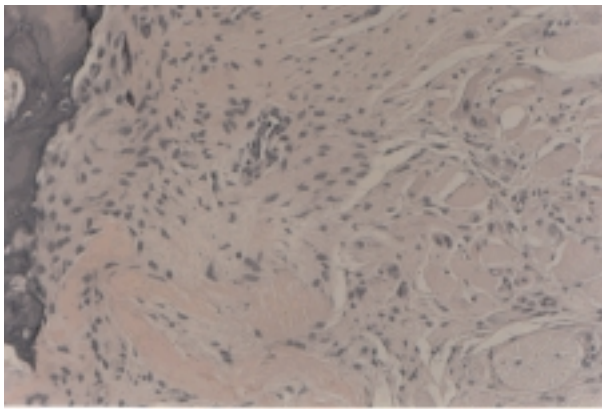


FIGURE 1 - Osteogenesis, osteoid matrix, with bone bridges non mineralized (HE) 160XAO.

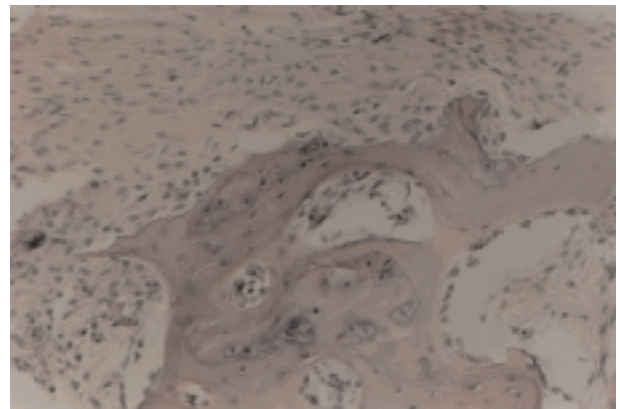


FIGURE 2 - Osteogenesis, osteoid matrix, with bone bridges non mineralized, within muscle tissue with inflammatory reaction (HE) 160XAO – 30 days.

With regard to the macroscopic results of the homologous implants in the jaw, we observed reparation in 3 of the 11 animals (27%) and in 5 an overlapping, (45%), was reported. With regard to the histological results of the homologous jaw graft, osteogenesis induction was observed in 9/11 (82%). Macroscopically the xenografts implants in the jaw presented reparation

in 4/11 (36%) individuals. In the homologous implants in abdominal muscle, it was observed a hardened consistency in 5 of the 11 cases (45%).

In the xenografts in the jaw, there was osteogenesis in 54% (6/11). Reabsorption occurred in 9% (1/11) and sequestrum in 36% (4/11). (Table 1)

TABLE 1 – Histological results of homologous and heterologous mandibular implant of rabbit and pig.

Days	CM 60 n(%)	PM60 n(%)	CM30 n(%)	PM30 n(%)	Total = CM	PM
Osteogenesis	6/6 (100%)	3/6 (50%)	3/5 (60%)	3/5(60%)	9/11 (82%)	6/11 (54%)
Reabsorption of Bone Matrix	0/6 (0%)	1/6 (17%)	2/5 (40%)	0/5 (0%)	2/11 (18%)	1/11 (9%)
Sequestrum of Bone Matrix	0/6 (0%)	2/6(33%)	0/5 (0%)	2/5(4%)	0/11 (0%)	4/11 (36%)

P = 0.18

With regard to the homologous and heterologous grafts of the abdomen, we observed osteogenesis of 27% in the homologous and 0% in the heterologous, sequestrum of 9% in the homologous and 82% in the

heterologous, fibrosis and hyalinization of 54% in the homologous and 18% in the heterologous, mixoid tissue of 9% and 0%, respectively (Table 2).

TABLE 2 – Histological results of homologous and heterologous implants in abdominal muscle.

Days	CA	PA	30 n(%)	PA	CA	PA
	60 n(%)				Total=60+30	
Osteogenesis	0/6 (0%)	0/6 (0%)	3/5 (60%)	0/5 (0%)	3/11 (27%)	0/11 (0%)
Sequestrum of Bone Matrix	0/6 (0%)	6/6 (1 0%)	1/5 (20%)	3/5 (60%)	1/11 (9%)	9/11(82%)
Fibrosis and Hyalinization	5/6 (83%)	1/6 (17%)	1/5 (20%)	1/5(20%)	6/11 (54%)	2/11(18%)
Mixoid Tissue	0/6 (0%)	0/6(0%)	1/5 (20%)	0/5 (0%)	1/11 (9%)	0/11(0%)

* P = 0.10

Discussion

Demineralized bone matrix grafts, considered immunologically inert can induce osteogenesis and bone repair by tissue regeneration. Through the better knowledge of the osteo-induction mechanism, many papers have shown good results with demineralized bone grafts in repairing cranio-facial defects.^{1,7} The results in this study show that demineralized bone matrix can really stimulate osteogenesis as, already referred others authors^{3,4,7,8,9,10,11}. At the beginning of the process, local mesenchymal cells were transformed into chondroblasts and afterwards, cartilage was substituted by bone tissue and bone marrow with endochondral ossification.^{5,13}

The use of bone matrix implant still difficult to solve the problem of the sterilization, considering that conventional methods destroy the bone matrix factors that induce osteogenesis. Sterilization^{7,14} in order to preserve the osteogenesis inducing factors should be made by immersion in hydrochloric acid at a concentration of 0.6M for one hour, and washed with 70% alcohol, or exposure in an ethylene oxide chamber for 30 minutes^{7,14}. The method of demineralization by immersion in hydrochloric acid gives the requirements of chemical sterilization of bone grafts with the preservation of the tissue's biological activity. No infection was observed in the 44 surgical approaches performed in the present study^{6,7,14}. The ectopical osteo-induction was observed in 3 of 22 animals (13,64%), that can be explained by the poor local vascularization. Only 2 cases of the 44 implants performed in the jaw or in abdominal muscle, showed foreign body reaction, which is suggestive of the rejection, and the two were heterologous implants, which raises the hypothesis of an immunogenic reaction, although this type of graft is admitted as being inert¹⁵.

We did not observe endochondral ossification in the cases of osteo-induction with demineralized bone matrix implantation, and that suggests the influence of the donor bone of its embriologicall endochondral or intra-membranous, in spite of the controversial of this selection of bone donor, brings advantages and disadvantages for cranio-facial repairs,^{12,13}. In a recent study, the authors say that the phenotypic differentiation of the cells into chondroblast or osteoblast, depends on the origin of the bone from which the matrix is prepared⁴. Thus a bone tissue of endochondral ossification will stimulate a differentiation into chondroblasts forming cartilage and, on the other hand, the bone tissue of intra-membranous ossification will stimulate differentiation into osteoblasts and new bone would be formed. In our histological results we observed intra-membranous ossification in both homologous and heterologous implants. The choice of donor bone intra-membranous origin for preparing the demineralized bone matrix was based on classic papers^{12,15,16,17} that report that they are preferable for submitting to and to the demineralization and keeping its physical properties.

Conclusions

Demineralized bone matrix graft in a jaw defect is the inductor of osteogenesis in rabbits, and apparently the homologous is more effective than the heterologous. In abdominal muscle, induction with a homologous graft occurs, which was not evidenced in the xenograft.

References

1. Urist MR. Bone: formation by autoinduction. *Science* 1965;150:893-9.

2. Huggins C, Wiseman S, Reddi H. Transformation of fibroblasts by allogenic and xenogenic transplants of demineralized tooth and bone. *J Exp Med* 1970;132:1250-8.
3. Axhausen W. The osteogenetic phases of regeneration of bone. *J Bone Joint Surg Am* 1956;38:593-600.
4. Mulliken JB, Glowacki J, Kaban LB, Folkman J, Murray JS. Use of demineralized allogenic bone implants for the correction of maxillocraniofacial deformities. *Ann Surg* 1981;194:366-72.
5. Mulliken JB, Glowacki J. Induced osteogenesis- the histological principle and clinical applications. *J Surg Res* 1984;37:487-96.
6. Salyer KE, Bardach J, Squier CA. Long-term outcome of extensive skull reconstruction using demineralized perforated bone in siamese twins joined at the skull vertex. *Plast Reconstr Surg* 1997;99:1721-6.
7. Tuli SM, Singh AD. The osteoinductive property of decalcified bone matrix. *J Bone Joint Surg Am* 1978;60:116-23.
8. Lacroix P. Organizers and growth of bone. *J Bone Joint Surg Am* 1955;37:742-58.
9. Siffert RS. Experimental bone transplants. *J Bone Joint Surg Am* 1955;37:742-58.
10. Glowacki J, Mulliken JB. Demineralized bone implant. *Clin Plast Surg* 1985;12:233-41.
11. Feighan JE, Davy D, Prewett AB, Stevenson S. Induction of bone by a demineralized bone matrix gel: a study in a rat femoral defect model. *J Orthop Res* 1995;13:881-91.
12. Salyer KE, Bardach J, Prewett AB, Stevenson S. Induction of bone by a demineralized bone matrix gel: a study in a rat femoral defect model. *J Orthop Res* 1995;13:881-91.
13. Rabie AB, Chay SH, Wong AMK. Healing of autogenous intramembranous bone in the presence and absence of homologous demineralized intramembranous bone *Am J Orthod Dentofacial Orthop* 2000;117:288-97.
14. Schwarz N, Redl H, Schiesser A, Schlag G, Thurnher M, Lintner F, Dinges HP. Irradiation-Sterilization of rat bone matrix gelatin. *Acta Orthop Scand* 1988;59:165-67.
15. Urist MR. Surface-decalcified allogenic bone (SDAB) implants. *Clin Orthop* 1968;56:37-50.
16. Neigel JM, Ruzicka PO. Use of demineralized bone implants in orbital and craniofacial reconstruction and a review of the literature. *Ophthal Plast Reconstr Surg* 1996;12:108-20.
17. Rabie AB, Deng YM, Samman N, Hagg U. The effect of demineralized bone matrix on the healing of intramembranous bone grafts in rabbit skull defects. *J Dent Res* 1996;75:1045-51.

Dall' Agnol R, Carvalho MB, Rapoport A, Silva MALG. Indução da osteogênese por implante de matriz óssea homóloga e heteróloga desmineralizada. *Acta Cir Bras* [serial online] 2003 Maio-Jun;18(3). Disponível em URL: <http://www.scielo.br/acb>.

RESUMO - A indução da osteogênese com matriz de enxerto ósseo desmineralizado continua a ser um desafio na reconstrução mandibular com enxerto homólogo e heterólogo ou em implantes em músculo abdominal. **Objetivo:** Observar o comportamento dos implantes desmineralizados de matriz óssea na mandíbula (lado direito com enxerto homólogo e esquerdo com heterólogo de porco) e em músculo abdominal. **Métodos:** Experimental com enxerto homólogo e heterólogo de matriz óssea desmineralizada na mandíbula e em músculo ectópico no Centro de Cirurgia Experimental do Hospital Heliópolis, Hosphel, São Paulo, Brasil. 6 coelhos brancos da raça Nova Zelândia, 46 procedimentos cirúrgicos sendo 23 com enxerto homólogo (coelho) e 23 com heterólogo (porco). 12 implantes homólogos (6 no lado direito da mandíbula e 6 na musculatura abdominal) foram feitos com matriz óssea desmineralizada. **Resultados:** Osteogênese avaliada através de histologia 30 e 60 dias após a cirurgia. Excluído 1 coelho morto, a osteogênese mandibular foi detectada em 9/11 (82%) coelhos que receberam matriz homóloga e 6/11 (54%) com heteróloga ($p=0,18$). No músculo abdominal, houve indução da osteogênese em 31/1 (27%) nos enxertos homólogos e 0% nos heterólogos ($p>0,20$). **Conclusões:** A indução da osteogênese através de implantes homólogos em mandíbula e musculatura abdominal de coelho foi mais eficiente que através dos heterólogos.

DESCRITORES - Osteogêneses. Homólogos. Heterólogos. Implantes.

Conflict of interest: none

Financial source: none

Correspondence:

Abrão Rapoport

Rua Iramaia, 136

01450-020 São Paulo – SP

Tel/Fax: (11)273-8224

cpgcp.hosphel@attglobal.net

Data do recebimento: 12/01/2003

Data da revisão: 27/01/2003

Data da aprovação: 06/02/2003