

DESIGN OF BUTTERFLY-SHAPED PLATE AND ITS APPLICATION IN TREATMENT FOR CALCANEAL FRACTURES

GUANGRONG YU, KAI CHEN, TAO YU

ABSTRACT

Objective: To introduce the design of a butterfly-shaped plate and its application in the treatment of calcaneal fractures, and to discuss its clinical indications, advantages and disadvantages. **Methods:** From February 2008 to April 2010, 22 patients with 26 intra-articular calcaneal fractures were treated by open reduction and internal fixation with a butterfly-shaped plate. Sixteen patients were male and six patients were female, with a mean age of 36.8 years. Eleven were left feet and 15, right. According to the Sanders classification, 12 were calcaneal fractures Type II (including three Type IIa, seven Type IIb and two Type IIc) and 14 were Type III (including five Type IIIab, seven Type IIIac and two Type IIIbc). **Results:** Seventeen patients

(21 feet) were followed-up for an average of 19.2 months. The functional outcomes were assessed using the Maryland Foot Score system. Among the nine feet with Type II fractures, seven feet were scored excellent, two were good. Among the 12 Type III fractures, six were scored excellent, five were good, and one was scored fair. **Conclusion:** The butterfly-shaped plate is applicable in the treatment of Sanders Type II and Type III calcaneal fractures, with the advantages of ensuring reliable fixation, facilitating the surgery, producing fewer postoperative complications, and generating better overall clinical outcomes.

Level of Evidence IV, Case Series.

Keywords: Calcaneus. Fracture Fixation, internal. Bone plates.

Citation: Yu G, Chen K, Yu T. Design of butterfly-shaped plate and its application in treatment for calcaneal fractures. *Acta Ortop Bras.* [online]. 2012;20(6):324-8. Available from URL: <http://www.scielo.br/aob>.

INTRODUCTION

Open reduction and internal fixation is a clinically proven method for the treatment of intra-articular calcaneal fracture.¹ However, due to relatively weak soft tissue coverage in the hindfoot area, much higher rates of complication were reported in comparison to the nonsurgical and percutaneous methods. Nonsurgical methods hardly obtain good anatomical reduction, and often result in malunion of fractures, eventually affecting the patients' ability to wear normal shoes and walk. Therefore, it is still unclear which treatment, surgical or nonsurgical, is better for intra-articular calcaneal fracture generating much academic controversy. Minimally invasive surgery is proposed as a new treatment method for intra-articular calcaneal fractures, combining the strengths of surgical and nonsurgical methods, while avoiding their drawbacks. From February 2008 to April 2010, 22 patients with 26 intra-articular calcaneal fractures were treated by open reduction and internal fixation using a butterfly-shaped plate designed by the authors and a minimally invasive method. The clinical efficacy was positive.

MATERIAL AND METHOD

The plate was designed to suit the anatomical characteristics of the calcaneus, as well as the characteristics of Sanders Type II and Type III fractures. A titanium plate with 1.5 mm thickness was used, undergoing different processing steps such as cutting, drilling, polishing, coating, etc. The finished plate is shaped like a butterfly, with a total length of 3 cm, anterior width of 1.8 cm, and posterior width of 2.5 cm. The plate has an upper front wing, an upper back wing, a lower front wing, a lower back wing, and a body. On each wing there is a circular screw hole, to be used for the fixation of the larger calcaneal bone fragments; the screw hole of the body is oval to facilitate the penetration of the screw upward into the sustentaculum tali to the calcaneus at an angle of 20°. (Figures 1 to 3) The material of the screws is TC4 titanium alloy, which is machined as a full-thread cancellous bone screw with a length of 20-50 mm. The design of the hexagonal nut has a diameter of 1.9 mm and thread depth of 1.05 mm; this design has shown quite good retention force for the bone fragments. (Figure 1)

All the authors declare that there is no potential conflict of interest referring to this article.

Department of Orthopaedic Surgery, Tongji Hospital, Tongji University School of Medicine, Shanghai, China

Study conducted at the Department of Orthopaedic Surgery, Tongji Hospital, Tongji University School of Medicine, Shanghai, China.

Mailing address: Dr. Guangrong YU, Department of Orthopaedic Surgery, Tongji Hospital, Tongji University School of Medicine, No. 389 Xincun Road, Shanghai 200065, China.
Email: yuguangrong2002@126.com

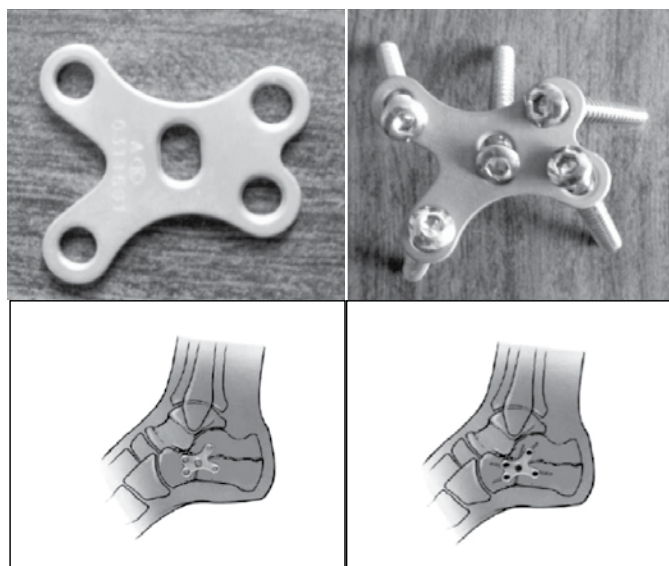


Figure 1. Design of the plate and fixation mode.

Testing of Mechanical Properties of Plate and Screws

The plate was able to resist vertical compressive load up to 2700N, compressive strength up to 150N/mm², bending load up to 210N, bending strength $\sigma_b=422\text{N/mm}^2$, tensile force between the fixed arms up to 1850N, tensile strength $\sigma_b=225\text{N/mm}^2$, and plastic deformation between the arms up to 10.22 mm. According to the previous testing data, the plate design showed very good mechanical properties; it resisted the internal stress passing along the calcaneus and its stiffness satisfied the stiffness requirements of the calcaneus. As accessories, the screws were also tested in dry calcaneus, and were capable of resisting a stretching force of 596N and a bending strength of 390N/mm², while the relative displacement was 3.2 mm.

Anatomical Study of Surgical Incision for the Plate

In order to perfect the reduction and fixation via a small incision, we used 20 fresh cadaver feet for anatomical analysis, measurement and to determine the best type of incision. (Figure 2) The four measurement lines were determined using the lateral malleolus as the center with the following path: a horizontal connecting line from the lateral malleolus to the posterior edge of the calcaneal tendon (Line LA); a connecting line from the lateral malleolus tip to the calcaneus tip (Line LB); a vertical line from the lateral malleolus to the bottom of the foot (Line LC); and a connecting line from the tip of the lateral malleolus to the fifth metatarsal base (Line LD). Then the intersection points of the saphenous vein, dorsal lateral sural cutaneous nerve, long peroneal muscle tendon and peroneus brevis tendon together with the above-mentioned four measurement lines were identified, and the distances from the intersection points to the lateral malleolus tip were respectively measured. (Table 1) Based on the previous measurement data and the fracture conditions, opted for an oblique incision measuring about 5cm in length, starting 2 cm below the posterior border of the lateral malleolus, thus enabling us to pull the tendon nerve upward and avoid potential trauma; the position was good for exposure, reduction and fixation of the fracture.

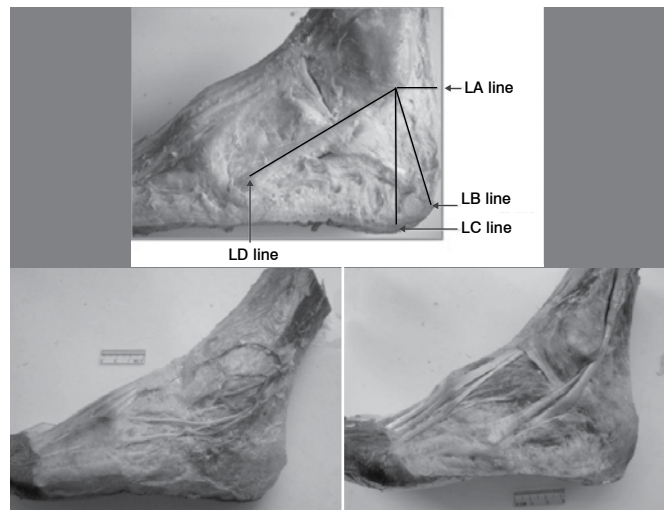


Figure 2. Anatomy around the incision.

Table 1. Distance from intersections of important tissues and four measurement lines to the tip of the lateral malleolus ($\bar{x} \pm S$ mm).

Measurement Line	No. of Samples	Saphenous Vein	Dorsal lateral sural cutaneous nerve	Long peroneal muscle tendon	Peroneus brevis tendon
Line LA	20	17.29±5.06 (7.84 ~ 26.5)	15.68±4.26 (8.26 ~ 27.62)	6.18±1.48 (3.08 ~ 9.38)	2.88±0.97 (1.24 ~ 4.54)
Line LB	20	15.91±5.44 (2.62 ~ 26.8)	14.36±3.51 (7.82 ~ 22.18)	7.28±1.39 (3.72 ~ 9.64)	3.63±1.29 (1.22 ~ 6.12)
Line LC	20	18.15±5.54 (2.24 ~ 26.72)	17.19±3.87 (11.12 ~ 9.34)	10.70±2.49 (6.18 ~ 15.92)	5.93±1.72 (3.26 ~ 8.86)
Line LD	20	36.49±5.91 (21.68 ~ 44.32)	41.35±6.39 (29.46 ~ 56.20)	Under the connecting line	38.18±7.06 (28.42 ~ 66.64)

CLINICAL DATA

General Information

The group included 22 patients with 26 intra-articular calcaneal fractures. In this group, 16 patients (19 feet) were male and 6 patients (7 feet) were female. The average age was 36.8 years. Eighteen patients had unilateral and 4 patients had bilateral fractures; 11 feet were left and 15 were right. The cause of injury was falling from height in 20 patients (24 feet), and car accident in 2 patients (2 feet). The average preoperative time was 4.2 days, ranging from 3 to 7 days. Two patients had thoracic and lumbar fractures as well. All patients underwent frontal and lateral radiographs of the feet, calcaneal axial radiograph, radiograph in Broden's position on the affected side; all patients also underwent CT in horizontal and coronal planes, of these, 18 patients (22 feet) had three-dimensional reconstruction image by CT. According to the Sanders classification, there were 12 Type II calcaneal fractures (3 feet of Type IIa, 7 feet of Type IIb, 2 feet of Type IIc), and 14 Type III fractures (5 feet of Type IIIab, 7 feet of Type IIIac, 2 feet of Type IIIbc).

Surgical Procedures

Under epidural anesthesia, the patients were placed in the supine position when the fracture was unilateral and in the prone position when the fracture was bilateral. Using a point 2 cm

below the lateral malleolus as the center, a 4-5 cm long arc-shaped or oblique incision was made, parallel to the posterior articular surface. From the incision, the lateral sural cutaneous nerve was exposed and protected; at the lateral side of the tendon sheath, the dissociated peroneus longus tendon and peroneus brevis tendon were exposed, and then the fracture was also exposed; the calcaneofibular ligament was cut, and the subtalar joint was exposed. With the help of forceps and under direct vision, reduction of the calcaneus was carried out, and 2-3 Kirschner pins were used for temporary fixation; a C-arm X-ray device was used to analyze the calcaneus shape and various indications of reduction, which should be used to determine the quality of the reduction. If the X-ray result is satisfactory, an arthroscope of 2.7 mm in diameter is used to verify the quality of the reduction of the bone fragments at the posterior articular surface, particularly in Sanders types fractures, closely observing Line B and Line C. When the displacements and gaps at the fracture line were ≤ 1 mm, the 5-hole butterfly-shaped titanium plate was introduced for fixation. At the upper front or body hole, a screw was driven towards the sustentaculum tali, while the outer front fragments were fixed; at the lower front hole, the screw fixed the anterior part of the calcaneus, and the anterior fragments of the calcaneocuboid joint at the same time; the upper back screw fixed the bone fragments on the posterior articular surface, or tongue-shaped fragment; the lower back screw fixed the bone fragments of the calcaneal tuberosity; the screw at the plate body was fixed to the sustentaculum tali. The C-arm X-ray device was used again to confirm if all reductions were satisfactory; next, a drainage strip was applied at the wound and the incision was sutured layer by layer. Usually, no external fixation is required. Forty-eight hours after the surgery, active exercises of toes and ankle were initiated; 6 to 8 weeks later, the patients could walk with load on the forefoot and 10 to 12 weeks later, they could walk with full weight-bearing on the whole foot.

RESULTS

In this group, 21 feet had postoperative follow-up; the total time ranged from 12 to 34 months, with mean duration of 19.2 months. (Figure 3) Examinations were performed with lateral and axial radiographs, and major reduction indicators were measured. Data from the measurements before and after surgery were compared by the paired t-test to assess postoperative improvement. (Table 2) The Maryland Foot Score² system in Table 3 was used for functional evaluation. Of the 9 cases of Type II fractures, 7 were rated excellent and 2 good; of the 12 cases of Type III fractures, 6 were rated excellent, 5 good, and 1 fair. (Table 4) All treated feet achieved good shape, were adapted to ordinary shoes, and no patient presented any limping. There were no healing complications or infections. In one case, there were symptoms of transient lesion in the sural cutaneous nerve.

DISCUSSION

Advantages of Fixation with a Small Plate and a Minimal Incision in the Treatment of Fractures of the Calcaneus

Nonsurgical treatment methods for calcaneal fractures usually result in many deformities, such as widened heel, uneven subtalar articular surfaces, collapse of the arch of the foot, hindfoot

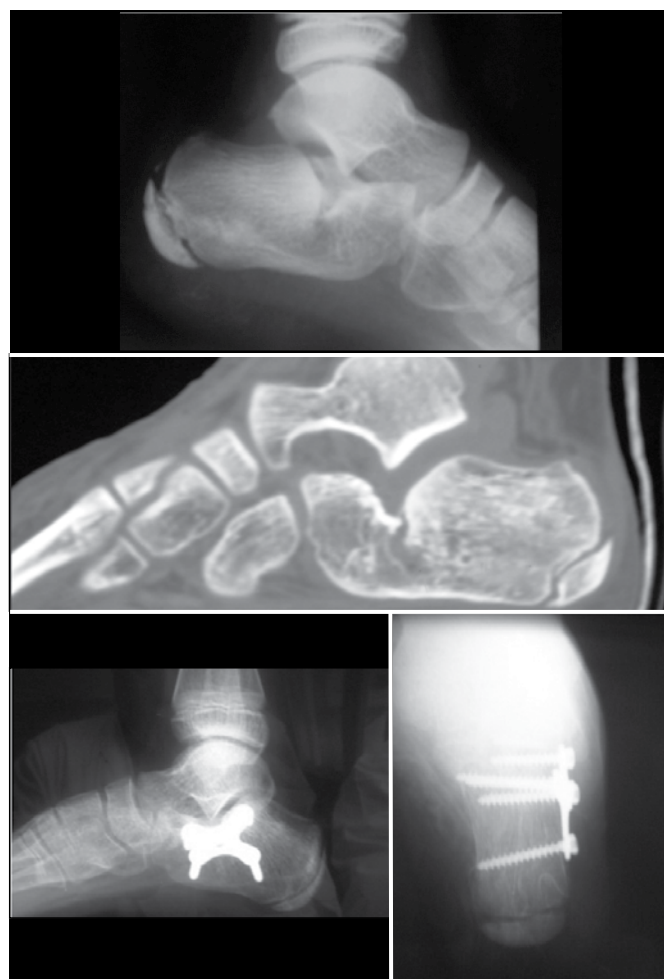

Figure 3. Comparison between preoperative aspect and one year after surgery.

Table 2. Comparison of relevant indicators before and after surgery ($\bar{x} \pm s$).

Indicator	No. of Cases	Preop	Postop	T Value	P Value
Böhler angle (°)	21	-17.6 \pm 1.5	29.0 \pm 2.2	32.52	<0.01
Gissane angle (°)	21	103.4 \pm 4.9	121.8 \pm 3.8	12.98	<0.01
Calcaneus axial length (mm)	21	52.5 \pm 3.8	57.1 \pm 3.2	3.67	<0.01
Calcaneus horizontal length (mm)	21	70.0 \pm 3.5	71.4 \pm 2.1	2.12	>0.05
Tuberalis height (mm)	21	47.8 \pm 1.9	48.2 \pm 1.8	0.61	>0.05
Calcaneal height at thalamus (mm)	21	36.8 \pm 2.3	38.6 \pm 1.2	2.84	<0.01
Calcaneus width (mm)	21	40.2 \pm 3.0	33.4 \pm 1.7	6.27	<0.01
Talar tilt angle (°)	21	10.9 \pm 1.0	14.6 \pm 1.4	12.78	<0.01

force line anomalies, etc.; these deformities result in calcaneofibular impact, traumatic arthritis at subtalar joint or calcaneocuboid joint, heel pain, walking difficulties, and apparently lower quality of life and problems at work.^{3,4} Open reduction and internal fixation can achieve better clinical efficacy, as reported by some researchers,⁵ with an average rate of functional recovery in the surgical group of 86.7%, while in the nonsurgical control group it is 55%. At present, open reduction and internal fixation has become the most widely adopted treatment method.

Table 3. Maryland Foot Score system.

Parameter	Score
1. Pain	
None: including with sports	45
Slight: no change in ADL or work	40
Mild: minimal change in ADL or work	35
Moderate: significant decrease in ADL	30
Marked: during minimal ADL, e.g., using the bathroom, performing simple housework	
Stronger, more frequent analgesic	10
Disabled: unable to work or shop	5
2. Gait	
1. Distance	
Unlimited	10
Slight limitation	8
Moderate limitation (2-3 blocks)	5
Severe limitation (2-3 blocks)	2
Indoors only	0
2. Stability	
Normal	4
Weak feeling – no true giving way	3
Occasional giving way (1-2 months)	2
Frequent giving way	1
Orthotic device use	0
3. Support	
None	4
Cane	3
Crutches	1
Wheelchair	0
4. Limp	
None	4
Slight	3
Moderate	2
Severe	1
Unable to walk	0
5. Shoes	
Any type	10
Minor concessions	9
Flat, laced	7
Without orthotics	5
Larger shoes	2
Unable to wear shoes	0
6. Stairs	
Normally	4
With bannister	3
Any method	2
Unable	0
7. Terrain	
No problem with any surface	4
Problems on stones, hills	2
Problems on flat surfaces	0
Esthetics	
Normal	10
Mild deformity	8
Moderate	6
Severe	0
Multiple deformities	0
Motion (ankle, subtalar, midfoot, metatarsophalangeal)	
Normal	5
Slightly decreased	4
Markedly decreased	2
Ankylosed	0

Excellent, 90-100; good, 75-89; fair, 50-74; failure, < 50.

Table 4. Results compared by fracture type.

Fracture/Type	Excellent	Good	Fair	Failure	Total
II	7	2	0	0	9
III	6	5	1	0	12
Total	13	7	1	0	21

However, the conventional L-shaped incision at the lateral calcaneus usually has poor healing and/or infections.⁶ Howard, et al.⁷ compared 206 cases (226 calcaneal fractures) and found that the open reduction and internal fixation group showed greater efficacy of treatment than the nonsurgical group; however, the former group had 28% of complications while the latter had only 19%. Moreover, calcaneal lateral L-shaped incision requires a larger area of calcaneal dissociation, which can further damage the bone fragments and their blood supply, especially at the posterior articular surface; later on it can cause poor fracture healing, osteonecrosis and early occurrence of osteoarthritis at the subtalar joint. Besides, for Sanders Type II and some Type III calcaneal fractures, conventional plates are quite large, placement surgery and subsequent removal require a large area of soft tissue dissociation, and because of their size they tend to cause skin damage and tendon and nerve irritation; as a matter of fact, 10 to 21% patients reported local postoperative pain.⁸ In order to guarantee good reduction and fixation, to minimize the surgical trauma and complications, to enhance functional recovery of the hindfoot and to improve clinical efficacy, a new method needs to be identified which combines the advantages of surgical and nonsurgical procedures while avoiding their disadvantages. The method of small incision and small plate is a possible solution for clinical treatment of fractures of the calcaneus, and this is precisely the purpose and purport of our working years.

Design Rationale, Advantages, Disadvantages & Indications of the Small Butterfly-Shaped Titanium Plate

In spite of a few reports regarding small plate fixation method in fractures of the calcaneus, until now no plate used in such places had shown high overall reliability of the fixation of the major bone fragments. In a report by Fernandez and Koella⁹, small internal fixation with minimally invasive surgery method was used to fix calcaneal bone fragments, reaching rates of excellent and good performance in 50 to 85%. In a report by Zwipp et al.¹⁰, a small H-shaped plate was used in the treatment of 123 cases of calcaneal fractures, with excellent and good performance rate of 61%. In a report by Tornetta¹¹, a small minifragment plate of 2.7 mm thickness was used on 35 calcaneal fractures by open reduction and internal fixation; Tornetta believed that this kind of plate might reduce skin trauma and tendon irritation. In a report by Huang et al.¹², a small T-shaped AO plate was used for fixation of Sanders Type II and Type III calcaneal fractures, and the clinical outcomes were quite satisfactory. However, none of the previously mentioned plates was able to integrate the posterior articular surface or the major bone fragments; additional standard staples (Solustaple[®]) or lag screws were always required for fixation to be acquired. In an article by Lin et al.¹³, two methods were compared and discussed from a biomechanical point of view: In Group A only screws were used for fixation of the posterior articular surface, while in Group B screws and plates were jointly used; the study results confirmed that the fixation performance in Group A was comparatively better than that in Group B; the average fixation strength was (131±70)N/mm in Group A, and (581±181)N/mm in Group B (P=0.02). In order to achieve better reliability of plate, since 2008 we have been using a small lateral incision combined with a butterfly-shaped titanium plate created by us for the

treatment of 12 Sanders Type II calcaneal fractures and 14 Type III. The reduction, fixation and clinical efficacy were quite satisfactory, with a rate of excellent and good performance up to 95%. One of the major advantages of the butterfly-shaped plates was a reduction in local exposure and dissociation, resulting in fewer complications in the site of the incision and osteonecrosis, in addition to better healing. Moreover, the smaller incision and faster healing helped to reduce healthcare costs. The plate design was optimized in terms of shape and tissue compatibility; higher overall reliability was achieved through the fixation in three key positions, namely sustentaculum tali, calcaneal tuberosity and anterior calcaneus. In addition, the fixation screws were well positioned in a radial direction using the plate as the center, so that all screws were tightened and compressed next to each other, which had an effect of enhancing resistance to stress and preventing further displacement. When designing the same screw length, just to penetrate the contralateral cortex of the calcaneus, the mechanical strength of the fixation could be enhanced.¹³ No external fixation was used in this group; 48 hours after the surgery, all patients started functional exercises of the ankle joint on the treated side to help with recovery of function. No secondary fracture displacement, abnormal incision healing, or necrosis of incision edge was found. The major disadvantage of this method was the limited exposure, requiring greater surgical skills as well as the use of C-arm X-Ray device and arthroscopy to improve visibility. Compared to the titanium plates with good plasticity, the fixation of the butterfly-shaped plate was relatively inferior. Due to shorter plate length and fewer screw holes, the fixation performance on comminuted fractures or Sanders Type IV fractures needs to be improved. Therefore, its application is mainly suitable for Sanders Type I, II, and III fractures, simple tongue-type fractures, compression fractures and shearing fractures; it is better for patients with brittle soft

tissue or with medical conditions such as diabetes that can hinder surgery with common incisions, etc.¹⁴

In short, the fixation method of the small butterfly-shaped plate and small incision has many advantages such as less invasive procedure, high reliability, easier operation, facilitation of early postoperative exercises, fewer complications, etc., which was consistent with the concept and purpose of the minimally invasive surgery. The authors would recommend this method as a treatment of choice for Sanders Type II and Type III intra-articular fractures of the calcaneus, provided there is careful selection of cases and sufficient preparation for surgery.

Reduction and Fixation Skills during Operation

We encourage sufficient preoperative preparation to have an accurate idea of the extent and type of fracture, dislocation and number of bone fragments before determining the surgical method. The location of the small incision has to be carefully calculated so that the exposure will not damage the sural cutaneous nerve, the peroneus longus tendon, or the peroneus brevis tendon. The anatomical reduction of the articular surface of the calcaneus should be performed as close as possible, and the gap and displacement on the reduced fracture should not exceed 1 mm. Testing had proved that a 1-2 mm displacement on the posterior articular surface would lead to remarkable changes in the load pattern and contact characteristics at the subtalar joint.¹⁵ The 5-hole plate should be placed in an appropriate position so that the bone fragments of the calcaneal tuberosity can be securely attached to the sustentaculum tali. The key is the reduction of the collapse of the posterior articular surface, the strong attachment of the tongue-type fragments or posterior fragments to the sustentaculum tali and also the reduction and fixation of the anterior lateral fragments to prevent valgus deformity and other disorders after surgery.

REFERENCES

- Potter MQ, Nunley JA. Long-term functional outcomes after operative treatment for intra-articular fractures of the calcaneus. *J Bone Joint Surg Am*. 2009;91(8):1854-60.
- Sanders R, Fortin P, DiPasquale T, Walling A. Operative treatment in 120 displaced intraarticular calcaneal fractures. Results using a prognostic computed tomography scan classification. *Clin Orthop Relat Res*. 1993;(290):87-95.
- Lim EV, Leung JP. Complications of intraarticular calcaneal fractures. *Clin Orthop Relat Res*. 2001;(391):7-16.
- Aşık M, Sen C. Surgical management of intraarticular fractures of the calcaneus. *Arch Orthop Trauma Surg*. 2002;122(6):354-9.
- Thordarson DB, Krieger LE. Operative vs. nonoperative treatment of intra-articular fractures of the calcaneus: a prospective randomized trial. *Foot Ankle Int*. 1996;17(1):2-9.
- Rak V, Ira D, Masek M. Operative treatment of intra-articular calcaneal fractures with calcaneal plates and its complications. *Indian J Orthop*. 2009;43(3):271-80.
- Howard JL, Buckley R, McCormack R, Pate G, Leighton R, Petrie D, et al. Complications following management of displaced intra-articular calcaneal fractures: a prospective randomized trial comparing open reduction internal fixation with nonoperative management. *J Orthop Trauma*. 2003;17(4):241-9.
- Elgafy H, Ebraheim NA. Subtalar arthroscopy for persistent subfibular pain after calcaneal fractures. *Foot Ankle Int*. 1999;20(7):422-7.
- Fernandez DL, Koella C. Combined percutaneous and "minimal" internal fixation for displaced articular fractures of the calcaneus. *Clin Orthop Relat Res*. 1993;(290):108-16.
- Zwipp H, Tschern H, Thermann H, Weber T. Osteosynthesis of displaced intraarticular fractures of the calcaneus. Results in 123 cases. *Clin Orthop Relat Res*. 1993;(290):76-86.
- Tornetta P 3rd. Open reduction and internal fixation of the calcaneus using mini-fragment plates. *J Orthop Trauma*. 1996;10(1):63-7.
- Huang PJ, Huang HT, Chen TB, Chen JC, Lin YK, Cheng YM et al. Open reduction and internal fixation of displaced intra-articular fractures of the calcaneus. *J Trauma*. 2002;52(5):946-50.
- Lin PP, Roe S, Kay M, Abrams CF, Jones A. Placement of screws in the sustentaculum tali. A calcaneal fracture model. *Clin Orthop Relat Res*. 1998;(352):194-201.
- Stapleton JJ, Kolodienker G, Zgonis T. Internal and external fixation approaches to the surgical management of calcaneal fractures. *Clin Podiatr Med Surg*. 2010;27(3):381-92.
- Mulcahy DM, McCormack DM, Stephens MM. Intra-articular calcaneal fractures: effect of open reduction and internal fixation on the contact characteristics of the subtalar joint. *Foot Ankle Int*. 1998;19(12):842-8.