

ANATOMIC ASPECTS OF EPIDIDYMIS AND TUNICA VAGINALIS IN PATIENTS WITH TESTICULAR TORSION

LUCIANO A. FAVORITO, ANDRÉ G. CAVALCANTE, WALDEMAR S. COSTA

Urogenital Research Unit, State University of Rio de Janeiro, and Service of Urology, Souza Aguiar Municipal Hospital, Rio de Janeiro, Brazil

ABSTRACT

Objective: To analyze the morphology of epididymis and tunica vaginalis as well as their anatomical anomalies in patients with testicular torsion.

Materials and Methods: We studied 25 patients (50 testes) aged between 12 and 23 years (mean 15.6). Torsion length ranged from 2 hours to 2 days (mean 8 hours). Epididymal anatomy was classified in 6 groups: Type I - epididymis united to the testis by its head and tail; Type II - epididymis totally united to the testis; Type III - disjunction of epididymal tail; Type IV - disjunction of epididymal head; Type V - total disjunction between testis and epididymis, and Type VI - epididymal atresia. The type of torsion was classified in 3 groups: Group A – intravaginal torsion; Group B – extravaginal torsion and Group C – torsion due to long mesorchium.

Results: Of the 50 analyzed testes, 40 (80%) presented bell clapper deformity (with 21 presenting intravaginal torsion); 8 testes (16%) had long mesorchium (4 with torsion), and only 2 (4%) presented normal anatomy in the tunica vaginalis. The most frequently found anatomical relationship between testis and epididymis was Type I - 38 cases (76%); Type II relationship was found in 6 cases (12%) and Type III relationship was found in 6 cases (12%).

Conclusions: Intravaginal torsion is the most frequent type, and torsion due to long mesorchium is associated with cryptorchidism. The most frequently found anatomical relation between testis and epididymis in the study group was Type I.

Key words: testis; epididymis; spermatic cord torsion; cryptorchidism
Int Braz J Urol. 2004; 30: 420-4

INTRODUCTION

Testicular torsion is a urologic urgency. The testis will present irreversible damage if the torsion is not resolved within up to 6 hours. Testicular torsion can occur at any age; however, it is more frequent in teenagers and young adults (1). This pathology is responsible for approximately 90% of acute testicular pain in patients between 13 and 21 years old (2).

Signs and symptoms of torsion include acute scrotal pain and testicular ascent, and the testis can lie horizontally with or without inflammatory signs

(3). The diagnosis is made mainly through clinical examination, however, in doubtful cases Doppler ultrasonography of the spermatic cord and testicular scintigraphy can be used to assess testicular perfusion (4). Often these tests are not promptly available, thus in doubtful cases following clinical examination, when complementary exams cannot be performed, urgency scrotal exploration is the treatment of choice (3).

The testicular torsion is an anomaly resulting from changes in the implantation of the tunica vaginalis or epididymal disjunction (5). Normally, the testis is united to the tunica vaginalis, and if the tu-

nica is implanted too high, the testis can present excessive mobility (bell clapper testis) (5). Mesorchium is the ligament that unites the testis to the epididymis (5,6). In cases of epididymal disjunction or elongated epididymis, conditions that are highly frequent in cryptorchism (7-10) the mesorchium is long and can contribute to the testicular torsion (6).

Several clinical and experimental studies on testicular torsion are described in the literature (1-4,11). Studies on the anatomic aspects of the tunica vaginalis and the association with epididymal anatomy and its anomalies in patients with testicular torsion are scarce (5,12). The objective of this work is to analyze the morphology of epididymis and tunica vaginalis, as well as their anatomic anomalies in patients with testicular torsion.

MATERIALS AND METHODS

In the period from May 2002 to May 2004 we studied 25 patients (50 testes and epididymis) with testicular torsion. All patients were admitted to our institution with symptoms of testicular pain. Following the clinical examination, a Doppler ultrasonography of the scrotal region was performed, in order to confirm the diagnosis. Patients were aged between

12 and 23 years (mean 15.6) and torsion duration ranged from 2 hours to 2 days (mean 8 hours).

All cases were operated by the same surgeon, who performed orchiopexy (or orchiectomy) in the twisted testis and orchiopexy in the contralateral testis. During surgical exploration, the anatomy of the tunica vaginalis and the relationships between testis and epididymis were classified according to the following system, previously described (6,12-14): Type I - epididymis united to the testis by its head and tail; Type II - epididymis totally united to the testis; Type III - disjunction of epididymal tail; Type IV – disjunction of epididymal head; Type V - total disjunction between epididymis and testis and Type VI – epididymal atresia.

The type of testicular torsion was classified in 3 groups according to the anatomy of the tunica vaginalis and the relationship between testis and epididymis (Figure-1): Group A – bell clapper testicular deformity (leading to intravaginal torsion); Group B – torsion of spermatic cord (leading to extravaginal torsion) and Group C – torsion due to long mesorchium.

We used qui-square statistical tests for contingency analysis of the populations under study ($p < 0.05$).

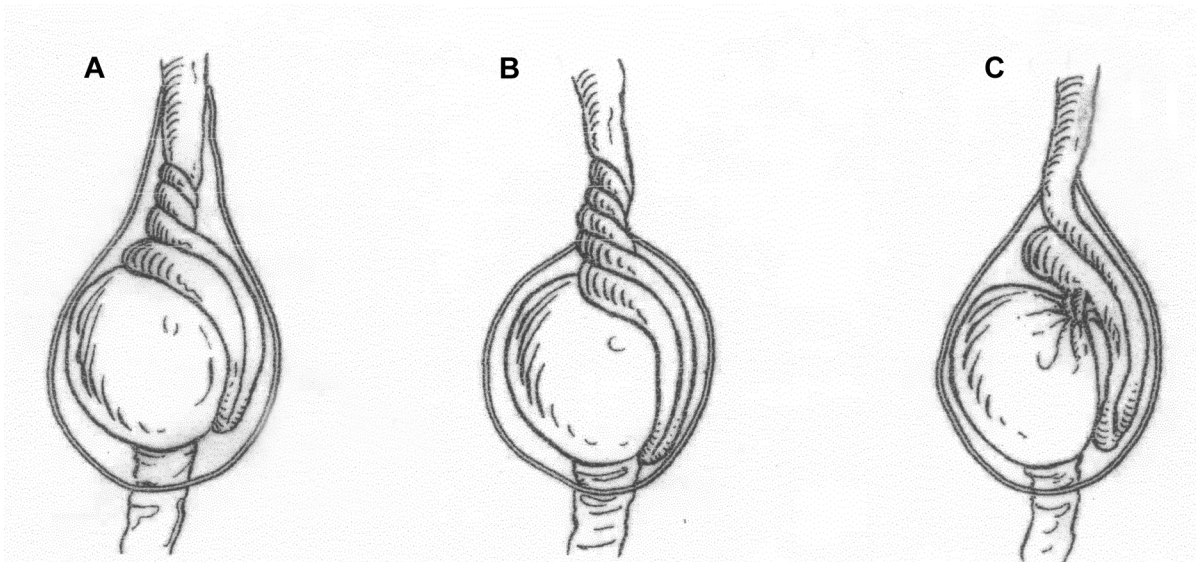


Figure 1 – Classification of types of testicular torsion. A) Intravaginal torsion; B) Extravaginal torsion; C) Torsion due to long mesorchium.

RESULTS

The type of testicular torsion found in the 25 patients is shown in (Table-1). Of the 25 studied patients, 13 (52%) presented torsion of the right testis and 12 (48%) of the left one, with no significant difference between the side of torsion. We did not find bilateral testicular torsion in any patient.

Of the 50 analyzed testes, 40 (80%) presented bell clapper deformity (with 21 presenting intravaginal torsion); 8 testes (16%) presented long mesorchium (4 with torsion), and only 2 (4%) of the 50 testes under analysis, presented normal anatomy of the tunica vaginalis. These data are exposed in (Table-2). Among the 25 cases of torsion, orchiectomy was performed in 8 cases, testis fixation was performed in the remainder.

Table 1 – Types of testicular torsion found during surgical exploration in the 25 patients studied.

Torsion	Number of Cases (%)
Intravaginal	21 (84)
Long mesorchium	4 (16)
Total	25 (100)

The most frequently found anatomic relation between testis and epididymis was type I - 38 cases (76%); type II relation was found in 6 cases (12%) and type III relation was found in 6 cases (12%) (Table-3).

Of the 8 cases with long mesorchium, 3 testes (37.5%) were cryptorchid. One patient with torsion due to long mesorchium presented bilateral cryptorchism and elongated epididymis bilaterally. In another case, the patient presented unilateral cryptorchism with disjunction of epididymal tail.

Table 3 – Incidence of types of anatomical relation between testis and epididymis observed in 25 patients (50 testes). Type I - Epididymis united to the testis by its head and tail; Type II - Epididymis totally united to the testis; Type III – Disjunction of epididymal tail; Type IV – Disjunction of epididymal head; Type V – Total disjunction between epididymis and testis and Type VI – Epididymal atresia.

Types of Anatomic Relation	Number of Testes (%)
Type I	38 (76)
Type II	06 (16)
Type III	06 (8)
Type IV, V and VI	-
Total	50 (100)

A third patient with torsion due to long mesorchium presented disjunction of the epididymal tail in the twisted testis. This patient presented normal epididymal anatomy and normal layering of tunica vaginalis in the testis without torsion. Two patients presented bilateral disjunction of epididymal tail.

COMMENTS

Testes present a normal layering of tunica vaginalis. They are involved by this structure on both sides and on their upper portion. The posterior region of testis is not covered by tunica vaginalis. United to the lower pole region of the testis and the epididymal tail, there is the testicular gubernaculum or its remnant, the testicular ligament, which is covered by tunica vaginalis only in its anterior and lateral portions (6). Intravaginal testicular torsion does not occur in testes presenting normal anatomy as described above, because the posterior testicular segment is

Table 2 – Cases presenting bell clapper deformity of tunica vaginalis or long mesorchium in relation to the twisted and normal sides.

Anatomy of Tunica Vaginalis	Twisted Testis	Contralateral Testis	Total
Bell clapper	21	19	40
Long mesorchium	4	4	8
Normal testis	-	2	2

firmly united to the scrotum, preventing the organ to move (5,6).

Testicular torsion occurs due to anatomic anomalies of tunica vaginalis or epididymis that allow excessive testicular mobility inside the scrotum. Due to this excessive mobility, testis can present medial rotation that ranges from 360° to 720° in its own axis, which can cause interruption of the organ's vascularization (2).

Based on our findings, a normal anatomy of tunica vaginalis or epididymis at the side contralateral to the torsion is rare (2 cases - 4%), and anatomic anomalies occur bilaterally in the vast majority of cases. These findings stress the need for bilateral orchiopexy in cases of testicular torsion.

Bell clapper deformity (intravaginal torsion) was the most commonly found type of anomaly (80%). The relation between the presence of full covering of testis and spermatic cord by tunica vaginalis (bell clapper deformity) and testicular torsion is well known. Parker & Robinson (5) in a study conducted with 40 patients found this deformity in 35% of studied cases.

Cases of torsion due to long mesorchium most often occur as a consequence of anomalies of epididymal disjunction or elongated epididymis, conditions that are highly frequent in cryptorchism (5-10). Of the 8 cases with long mesorchium, 3 (37.5%) had cryptorchid testes. These findings are similar to those of Parker & Robinson (5) who found long mesorchium in 33% of studied cases.

Approximately 20% of cases of testicular torsion occur in patients with cryptorchism (6). Epididymal anomalies associated with long mesorchium are frequent in patients with cryptorchism, with an incidence ranging from (36 to 72%) (7-10) and rare in individuals with topic testes (less than 4%) (14). Due to these changes in mesorchial region, the possibility of testicular torsion must be considered in cryptorchid patients presenting acute scrotal or inguinal pain.

Anatomical relations between testis and epididymis in patients with testicular torsion evidenced a pattern that is not different from patients without anomalies (12, 13-15). Type I and type II relations were observed in approximately 90% of cases of tes-

ticular torsion. In 2 patients with torsion with long mesorchium found in type I anatomy with elongated epididymis.

Elongated epididymis is a condition included in type I, according to the classification used in this paper (6,13-15). However it is known that patients with cryptorchism present a high index of epididymal anomalies (Types III, IV and V), as well as elongated epididymis (7-10). However, the present classification includes elongated epididymis in the normal group. Probably a subdivision of type I anatomic relation with elongated epididymis in a separate group will be necessary in the future.

We concluded that intravaginal torsion (bell clapper tunica vaginalis) is the most frequent type of torsion, and torsion due to long mesorchium is associated with cryptorchism. The most frequently found anatomical relation between testis and epididymis in the study group was type I (epididymis united to the testis by its head and tail).

The present research was supported by Rio de Janeiro Foundation for Research Support (FAPERJ) and National Council for Scientific and Technological Development (CNPQ).

REFERENCES

1. Cummings JM, Boullier JA, Sekhon D, Bose K: Adult testicular torsion. *J Urol.* 2002; 167: 2109-10.
2. Ben-Chaim J, Leibovitch I, Ramon J, Winberg D, Goldwasser B: Etiology of acute scrotum at surgical exploration in children, adolescents and adults. *Eur Urol.* 1992; 21: 45-7.
3. Kass EJ, Stone KT, Cacciarelli AA, Mitchell B: Do all children with an acute scrotum require exploration? *J Urol.* 1993; 150: 667-9.
4. Middleton WD, Siegel BA, Melson GL, Yates CK, Andriole GL: Acute scrotal disorders: prospective comparison of color Doppler US and testicular scintigraphy. *Radiology.* 1990; 177: 177-81.
5. Parker RM, Robison JR: Anatomy and diagnosis of torsion of the testicle. *J Urol.* 1971; 106: 243-7.
6. Scorer CG, Farrington GH: *Congenital Deformities of the Testis and Epididymis.* London, Butter Worths e Co, 1971.

7. Elder JS: Epididymal anomalies associated with hydrocele/hernia and cryptorchidism: implications regarding testicular descent. *J Urol.* 1992; 148: 624-6.
8. Gill B, Kogan S, Starr S, Reda E, Levitt S: Significance of epididymal and ductal anomalies associated with testicular maldescent. *J Urol.* 1989; 142: 556-8; discussion 572.
9. Gill B, Kogan S: Cryptorchidism. Current concepts. *Pediatr Clin North Amer.* 1997; 44: 1211-27.
10. Marshall FF: Anomalies associated with cryptorchidism. *Urol Clin North Amer.* 1982; 9: 339-47.
11. Noske HD, Kraus SW, Altinkilic BM, Weidner W: Historical milestones regarding torsion of the scrotal organs. *J Urol.* 1998; 159:13-6.
12. Caesar RE, Kaplan GW: Incidence of the bell-clapper deformity in an autopsy series. *Urology.* 1994; 44: 114-6.
13. Favorito LA, Sampaio FJ: Anatomical relationships between testis and epididymis during the fetal period in humans (10-36 weeks postconception). *Eur Urol.* 1998; 33: 121-3.
14. Turek PJ, Ewalt DH, Snyder HM 3rd, Duckett JW: Normal epididymal anatomy in boys. *J Urol.* 1994; 151: 726-7.
15. Favorito LA, Sampaio FJ, Javaroni V, Cardoso LE, Costa WS: Proximal insertion of gubernaculum testis in normal human fetuses and in boys with cryptorchidism. *J Urol.* 2000; 164: 792-4.

Received: July 6, 2004

Accepted after revision: October 13, 2004

Correspondence address:

Dr. Luciano Alves Favorito
 Unidade de Pesquisa Urogenital
 Universidade do Estado do Rio de Janeiro
 Av. 28 de Setembro, 87, fundos, FCM, térreo
 Rio de Janeiro, RJ, 20551-030, Brazil
 Fax: + 55 21 2587-6121
 E-mail: favorito@uerj.br