

## Lung ultrasound in critically ill patients: a new diagnostic tool\*

Ultrassom pulmonar em pacientes críticos: uma nova ferramenta diagnóstica

Felippe Leopoldo Dexheimer Neto, Paulo de Tarso Roth Dalcin,  
Cassiano Teixeira, Flávia Gabe Beltrami

### Abstract

The evaluation of critically ill patients using lung ultrasound, even if performed by nonspecialists, has recently garnered greater interest. Because lung ultrasound is based on the fact that every acute illness reduces lung aeration, it can provide information that complements the physical examination and clinical impression, the main advantage being that it is a bedside tool. The objective of this review was to evaluate the clinical applications of lung ultrasound by searching the PubMed and the Brazilian Virtual Library of Health databases. We used the following search terms (in Portuguese and English): ultrasound; lung; and critical care. In addition to the most relevant articles, we also reviewed specialized textbooks. The data show that lung ultrasound is useful in the differential diagnosis of pulmonary infiltrates, having good accuracy in identifying consolidations and interstitial syndrome. In addition, lung ultrasound has been widely used in the evaluation and treatment of pleural effusions, as well as in the identification of pneumothorax. This technique can also be useful in the immediate evaluation of patients with dyspnea or acute respiratory failure. Other described applications include monitoring treatment response and increasing the safety of invasive procedures. Although specific criteria regarding training and certification are still lacking, lung ultrasound is a fast, inexpensive, and widely available tool. This technique should progressively come to be more widely incorporated into the care of critically ill patients.

**Keywords:** Ultrasonography; Lung; Critical care; Intensive care units.

### Resumo

A avaliação pulmonar através do ultrassom é um tema de crescente interesse na avaliação de pacientes críticos, muitas vezes aplicado por não radiologistas. Como essa técnica baseia-se no fato de que todas as agressões agudas reduzem a aeração pulmonar, o ultrassom pulmonar pode fornecer informações complementares ao exame físico e à impressão clínica, com a principal vantagem de ser realizado à beira do leito. O objetivo dessa revisão foi avaliar as aplicações clínicas do ultrassom pulmonar, através da pesquisa das bases de dados PubMed e Biblioteca Virtual em Saúde dos seguintes termos, em português e em inglês: ultrassom, pulmão e cuidados críticos. Além dos artigos mais relevantes, estendeu-se a busca a livros especializados. Dados da literatura mostram que o ultrassom pulmonar é útil na interpretação de infiltrados pulmonares, tendo boa acurácia na identificação de consolidações e de síndrome intersticial. Além disso, ultrassom pulmonar tem sido amplamente utilizado na avaliação e abordagem de derrames pleurais, assim como na identificação de pneumotórax. Essa técnica pode também ser útil na avaliação imediata de pacientes com dispneia ou insuficiência respiratória aguda. Outras aplicações descritas são a monitorização da resposta ao tratamento e o aumento da segurança na realização de procedimentos invasivos. Embora ainda haja a necessidade de uma padronização dos critérios de treinamento e certificação, esse é um método rápido, barato e amplamente disponível, e a incorporação dessa nova tecnologia deve tornar-se progressivamente maior no cuidado de doentes críticos.

**Descritores:** Ultrassonografia; Pulmão; Cuidados intensivos; Unidades de terapia intensiva.

---

\* Study carried out at the Ernesto Dornelles Hospital; at the Moinhos de Vento Hospital; at the Federal University of Health Sciences of Porto Alegre; and in the Department of Internal Medicine, Federal University of Rio Grande do Sul, Porto Alegre, Brazil. Correspondence to: Felippe Leopoldo Dexheimer Neto, Departamento Médico Judiciário, Avenida Borges de Medeiros, 1565, Centro/Praia de Belas, CEP 90110-906, Porto Alegre, RS, Brasil.

Tel. 55 51 3210-6400. E-mail: fldneto@tj.rs.gov.br

Financial support: None.

Submitted: 24 February 2012. Accepted, after review: 28 March 2012.

## Introduction

Air is a barrier to ultrasound waves, which is why lung ultrasound was long considered impossible.<sup>(1,2)</sup> However, an increasing number of studies have broken that paradigm, demonstrating that lung ultrasound can be useful in the pulmonary evaluation of critically ill patients, lung ultrasound findings complementing other imaging findings.<sup>(3-7)</sup>

Although ultrasound is traditionally used by radiologists, there are many studies reporting the use of lung ultrasound by nonspecialists, including emergency room physicians, intensivists, and pulmonologists.<sup>(4,6-10)</sup> The main advantage of lung ultrasound is that it is a bedside tool, meaning that it can be applied immediately, lung ultrasound findings complementing physical examination findings and clinical impression.<sup>(6)</sup> In addition, lung ultrasound is especially attractive for the evaluation of critically ill patients (Chart 1).

Lung ultrasound is based on the fact that every acute disease reduces lung aeration, changing the lung surface and generating distinct, predictable patterns; this allows the diagnosis of conditions and the monitoring of therapeutic interventions (Figure 1).<sup>(1,4,11)</sup>

Several studies have argued that lung ultrasound should be essentially simple and focused on critically ill patients, having suggested the use of a standardized technique with simple equipment, i.e., with a single transducer.<sup>(1,4,12)</sup>

In this context, the objective of the present review article was to evaluate the clinical applications of lung ultrasound in critically ill patients.

## Methods

We searched the PubMed and the Brazilian Virtual Library of Health databases using the search terms “ultrasound”, “lung”, and “critical

care”, as well as combinations thereof. We also used the MeSH terms “ultrasonography”, “critical care”, and “lung”. The review was conducted on January 17, 2012. We included Portuguese-language and English-language articles published between January of 2001 and the date of the electronic search. We also reviewed textbooks on pulmonology, as well as those on the use of ultrasound in intensive care settings, together with related articles published in specialized journals.

The electronic search returned 8 articles. Of those, 6 were considered relevant. Another 22 articles/texts were selected from among those found in the textbooks and specialized journals reviewed.

## Ultrasound examination and normal lungs

Before addressing the clinical use of lung ultrasound in critically ill patients, we present a brief review of the lung ultrasound technique, as well as of the lung ultrasound findings that are considered normal.

Ultrasound is a form of inaudible sound energy used for diagnostic purposes at a frequency range of 2-20 MHz. The ultrasound pulse is generated by piezoelectric crystals in the transducer of the device, generating waves that are transmitted, attenuated, and reflected by tissues.

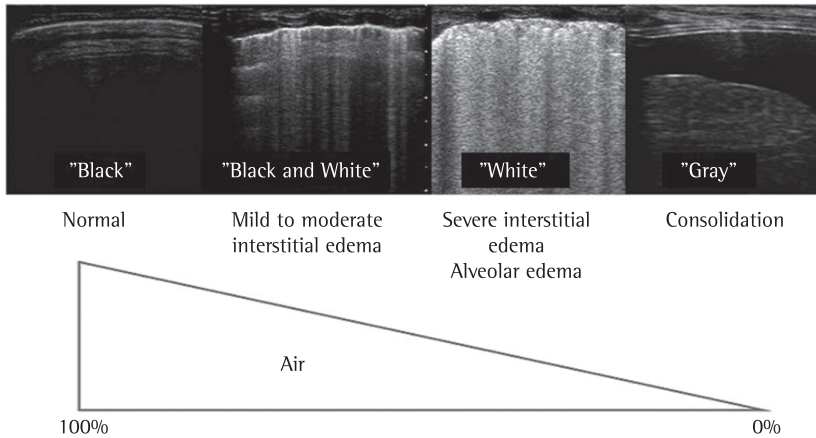
Although nearly all of the energy is reflected, the difference in acoustic impedance among tissues changes the ultrasound signal strength; this provides information regarding the location and characteristics of tissues, which are processed into grayscale images, on which ultrasound technology is based.<sup>(5)</sup>

The way in which the reflected signals are processed determines image formation. When brightness-mode (B-mode) ultrasound is used,

**Chart 1** – Advantages of lung ultrasound in the evaluation of critically ill patients.

Easy to learn
Fast, noninvasive, and easily reproducible
Portable device; bedside evaluation eliminates the need for transporting the patient and the risks thereof
Widely available
Reduces exposure to radiation
Good accuracy
Aids in establishing the diagnosis and in monitoring the response to treatment
Low cost

Sources: Lichtenstein; Bouhemad et al.; Mayo, Anantham & Ernst; Koenig et al.; and Soldati & Sher.<sup>(1,3-6,11)</sup>



**Figure 1** – Physical principles of lung ultrasound. A less aerated lung translates to easier detection of abnormalities by the method. Adapted from Gargani,<sup>(2)</sup> with the permission of the author.

the amplitude of energy is shown as dots of varying intensity, which allows conventional two-dimensional image formation; when motion-mode (M-mode) ultrasound is used, the image of a given object is monitored over time (Figure 2).<sup>(5)</sup>

Although their specifications can vary, the recommended ultrasound systems are generally common and widely available. A 3-7-MHz curved-array transducer, preferably small (for better adaptation to the intercostal spaces), is appropriate.<sup>(3,4,6)</sup>

For satisfactory image acquisition, two parameters need to be adjusted: depth (generally less than 10 cm, depending on the objective of the examination) and gain (which amplifies the signals, making the image lighter or darker as needed).<sup>(5,10)</sup>

For the purposes of the present review, lung ultrasound includes the evaluation of the chest wall, pleural space, diaphragm, and lungs.<sup>(6)</sup> Although the estimated duration of the examination is approximately 15 min, experienced operators perform it more rapidly.<sup>(3)</sup>

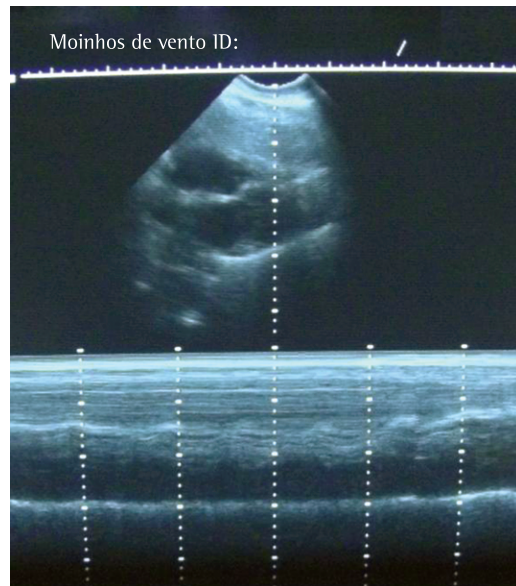
In general, patients are examined in the supine position, with the head of the bed elevated. The anterior and posterior axillary lines are the reference points for the examination, dividing the thorax into three zones, which are generally subdivided into upper and lower sections.<sup>(3,5)</sup>

By convention, lung ultrasound is performed in the longitudinal plane, with the transducer perpendicular to the skin surface.<sup>(4)</sup>

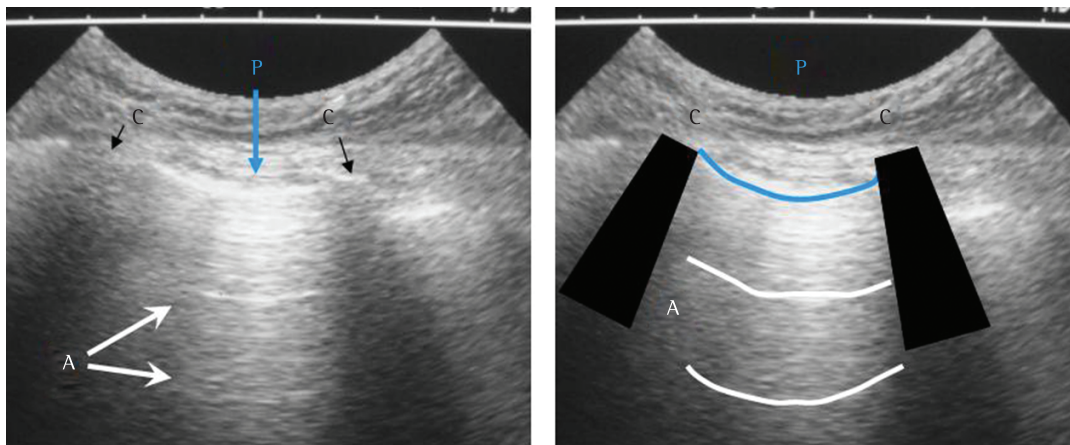
Initially, for B-mode ultrasound, the transducer is positioned with its marker directed to the head of the patient and perpendicular to the

ribs, the typical lung ultrasound image being therefore obtained.<sup>(4,6)</sup> The adjacent intercostal spaces are examined by sliding the transducer vertically (Figure 3).<sup>(10)</sup>

The ribs block the ultrasound waves and are identified by their posterior acoustic shadowing (letter C in Figure 3), which precludes the visualization of deeper structures. Approximately 0.5 cm below the ribs, a light (hyperechoic) horizontal line, known as the pleural line, is seen



**Figure 2** – Ultrasound modes. Cardiac ultrasound (subxiphoid view). Brightness-mode ultrasound (top) and motion-mode ultrasound (bottom). In the latter, the image of the object is monitored over time, which allows the evaluation of movement amplitude.



**Figure 3** – Ultrasound images of a normal lung. In the figure on the left, note an intercostal space, formed by two adjacent ribs (dark images indicated by letter C), and the pleural line (light, approximately 0.5 cm below the ribs and indicated by letter P). Note also the A-lines (horizontal and light, indicated by letter A). In the figure on the right, the findings are illustrated.

(letter P in Figure 3). The pleural line is made up of the visceral and parietal pleura surfaces. During respiration, the two pleural surfaces slide against each other (air displacement), and this appears as a shimmering white line.

The normal lung parenchyma (as well as any anatomical structure filled with gas) cannot be seen beyond the pleura, given that the presence of air prevents ultrasound wave propagation. This generates an artifact known as A-lines, i.e., light (hyperechoic) horizontal lines that are static and repeat at regular intervals (letter A in Figure 3).

Lung sliding is the key lung ultrasound finding; it corresponds to the regular movement of the pleural line (described as a shimmering or bright white line) in regular cycles in synchrony with respiratory movements.<sup>(1,4,5)</sup>


Lung sliding is easily identified on B-mode ultrasound; on M-mode ultrasound, lung sliding appears as a specific sign, known as the seashore sign, which is characterized by a linear pattern—corresponding to the chest wall (no movement)—above the pleural line (light or hyperechoic) and a homogeneous granular pattern—an artifact generated by respiratory cycles and air movement—below the pleural line (Figure 4).

Lung sliding is found in normal lungs, being absent in pathologies that affect lung mobility, including pleurisy, pleurodesis, pneumothorax, subcutaneous emphysema, apnea, severe bronchospasm, COPD, and acute respiratory distress syndrome.<sup>(5)</sup>

For the evaluation of lung regions, it is recommended that the examiner identify the diaphragm and lungs, pleural effusions and consolidations being generally identified in the dependent regions.<sup>(3)</sup> It is always useful to evaluate the contralateral lung in order to compare the findings.<sup>(7)</sup>

## Clinical applications

Lung ultrasound can aid in the interpretation of pulmonary infiltrates, being able to differentiate



**Figure 4** – Mode-movement lung ultrasound. On the left (a), a normal lung pattern, as evidenced by the seashore sign (superficial linear image), the pleural line (light, indicated by the arrow), and, below the pleural line, a homogeneous granular pattern, corresponding to lung sliding. The composition of the image (a + b region) shows the lung point (P), together with the granular pattern. On the right (b), the findings are linear, no lung sliding being shown (the stratosphere sign). This combination of findings is 100% specific for pneumothorax. Adapted from Bouhemed et al.,<sup>(3)</sup> with the permission of the authors.



normal lung from consolidations, interstitial infiltrate, alveolar infiltrate, and pleural effusion.<sup>(2,3)</sup>

### **Pleural effusion**

Pleural effusion is a common problem in critically ill patients. It is known that ultrasound is more sensitive than clinical examination and chest X-rays for the diagnosis of pleural effusion, being especially effective in the differential diagnosis between effusions and pulmonary atelectasis.<sup>(5,13,14)</sup>

Pleural effusion can be easily detected by lung ultrasound, corresponding to a dark (hypoechoic) and homogeneous image in the dependent regions of the lung.<sup>(2,3,6)</sup>

For an adequate evaluation of pleural effusion, it is necessary to identify three findings<sup>(10)</sup>:

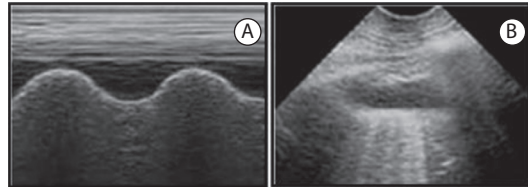
- anatomical boundaries—chest wall, lung, diaphragm, and adjacent solid organs (liver/spleen)—confirming the intrathoracic location of the collection, especially if a thoracentesis has been planned
- anechoic space—the pleural effusion itself
- dynamic changes—intermittent lung aeration, compressed lung, or both (atelectasis); diaphragmatic movement; and sinusoidal inspiratory movement (Figure 5)

In a study evaluating emergency room patients complaining of dyspnea, lung ultrasound was found to be more accurate than X-rays in those who subsequently underwent chest CT scans. In that study, the sensitivity and specificity of lung ultrasound for identifying pleural effusion were 90% and 73%, respectively.<sup>(14)</sup>

Pleural effusion can also be identified by the quad sign (Figure 5) and differentiated from solid organs by the sinusoid sign (Figure 5), i.e., sinusoidal inspiratory movement, as seen on M-mode ultrasound, with a specificity of 97%.<sup>(1)</sup>

Although the estimation of pleural effusion volume is still a controversial issue, one option is to evaluate the distance between the lung and the posterior chest wall with the transducer placed in the posterior axillary line. A distance  $\geq 50$  mm is highly suggestive of  $\geq 500$  ml of pleural effusion.<sup>(3)</sup> Pleural effusion volume (in mL) can also be estimated by multiplying the maximum distance in that position by 20.<sup>(15,16)</sup>

In cases of complicated pleural effusion, lung ultrasound is superior to other imaging modalities,<sup>(6,10)</sup> showing shimmering points amid anechoic fluid (debris spinning freely) or even septations (hyperechoic linear images).<sup>(5,17)</sup> In



**Figure 5** – Findings indicative of pleural effusion. In A, motion-mode ultrasound showing a hypoechoic (dark) image. Note the sinusoid sign. The cyclic motion of the underlying lung parenchyma confirms the finding of pleural effusion. In B, the quad sign, a quadrangular image limited laterally by the posterior acoustic shadowing created by the ribs; superiorly by the limit created by the chest wall; centrally by an anechoic (dark) image (indicating pleural effusion); and, more deeply, by a hyperechoic (light) image (corresponding to the lung parenchyma). Modified from Lichtenstein.<sup>(1)</sup>

addition, a pleural effusion that does not show these changes can be ruled out as a source of infection in febrile patients.<sup>(17)</sup>

### **Pneumothorax**

Lung ultrasound is extremely effective in ruling out pneumothorax, the presence of lung sliding (or the seashore sign) excluding the diagnosis of pneumothorax (negative predictive value, 100%).<sup>(1,4)</sup>

The evaluation of pneumothorax should begin in nondependent lung regions, the interposition of air between the layers of the pleura preventing them from sliding and therefore precluding the presence of B-lines (see Interstitial syndrome below), lung ultrasound showing A-lines only.<sup>(2,5)</sup> In a study evaluating residual pneumothorax after chest tube removal in postoperative patients, performing lung ultrasound was reported to be faster than taking chest X-rays, lung ultrasound findings having correlated well with chest X-rays findings.<sup>(18)</sup> In addition, multiple studies have demonstrated the superiority of lung ultrasound over chest X-rays taken in the supine position in ruling out pneumothorax.<sup>(19-21)</sup> However, the definitive diagnosis of pneumothorax is considered difficult because the absence of lung sliding is not enough to establish it; there is a need to identify an ultrasound sign known as the lung point (intermittent lung sliding point), an experienced examiner being therefore required.<sup>(3,4)</sup> The lung point consists of a normal lung area

in contact with an area with no lung sliding or A-lines. This finding indicates that the lung parenchyma is partially collapsed, being 100% specific for pneumothorax.<sup>(1)</sup> Likewise, when there is no lung sliding, M-mode ultrasound findings change; below the pleural line, rather than a granular pattern, a linear pattern is seen, a finding that is known as the stratosphere sign (Figure 4).

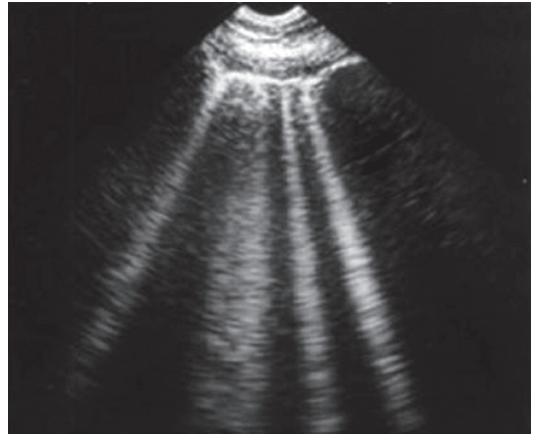
### ***Interstitial syndrome***

The presence of pulmonary edema or interstitial infiltrate is characterized by interlobular septal thickening and reduced peripheral aeration, generating artifacts known as B-lines. B-lines are light (hyperechoic) vertical artifacts that can be multiple in the same intercostal space and that arise from the pleural line and extend to the edge of the screen, erasing the A-lines at their intersections.

B-lines move in synchrony with the respiratory cycle, and their presence excludes the diagnosis of pneumothorax.<sup>(4)</sup> Although B-lines can be detected in normal lungs, the number of B-lines is directly related to the degree of interlobular septal thickening, as well as to the reduction in lung aeration (Figure 6).<sup>(5)</sup>

Studies have demonstrated that the presence of B-lines 7 mm apart is associated with interlobular septal thickening caused by venous congestion, whereas B-lines  $\leq 3$  mm apart are associated with areas of alveolar edema (corresponding to the CT finding of ground-glass opacity).<sup>(3)</sup>

For practical purposes, the identification of more than three B-lines in a given intercostal space in nondependent lung regions is considered an abnormal finding.<sup>(4,6)</sup> In addition, the number of B-lines is directly proportional to the worsening of functional class of heart failure; to the extravascular lung water content; to brain natriuretic peptide levels; and to the severity of diastolic dysfunction for any degree of systolic dysfunction.<sup>(2,5,9,22)</sup> Therefore, the presence of B-lines in nondependent lung regions is useful for the differential diagnosis between cardiogenic and noncardiogenic dyspnea; this has been validated by studies comparing lung ultrasound findings and brain natriuretic peptide levels.<sup>(2,5)</sup> In addition, the diagnosis of pulmonary edema can be confirmed by the disappearance of B-lines on lung ultrasound after appropriate treatment for heart failure.<sup>(5,22)</sup>



**Figure 6** – B-lines on lung ultrasound. Although B-lines are seen in normal individuals, the number and intensity of B-lines are directly proportional to the degree of pulmonary, septal, or alveolar edema. Adapted from Lichtenstein et al.<sup>(23)</sup>

### ***Atelectasis and pulmonary consolidation***

The finding of atelectasis or pulmonary consolidation consists of a loss of aeration, which generates a visible area of parenchyma, similar to the liver texture, with irregular, ill-defined borders.<sup>(5)</sup> Comparison with the solid abdominal organs (liver and spleen) allows the identification of a clear similarity between the structures (tissue density)—the tissue-like sign—with a specificity of 98.5% for the diagnosis of consolidations (Figure 7A).<sup>(1,5)</sup> In addition, the presence of irregularities in the margins of the lesion (i.e., in the pleural line itself) constitutes the shred sign (Figure 7B) and has a 90% sensitivity for the diagnosis of parenchymal consolidation.<sup>(1)</sup> Furthermore, light (hyperechoic) punctiform images can be seen within the consolidation; these images vary according to the respiratory cycle (changing location, size, or shape) and correspond to the finding of air bronchograms.<sup>(3)</sup>

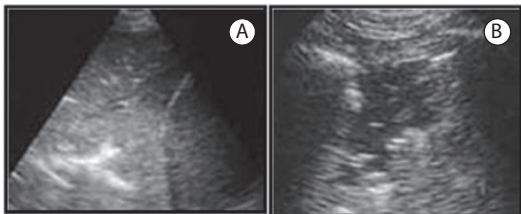
It should be highlighted that the finding of consolidation is purely descriptive, given that any process that leaves the alveolar compartment without air will be identified as consolidation by the diagnostic methods (X-rays, CT, and lung ultrasound).<sup>(4)</sup> The narrowing of the intercostal spaces and the elevation of the hemidiaphragm suggest the presence of atelectasis.<sup>(5)</sup> Therefore, clinicians must interpret the findings in order to determine the cause of the pathological state (atelectasis, infiltrative processes, and pulmonary edema) correctly.

## Respiratory failure

Lung ultrasound allows a standardized evaluation of patients with dyspnea, respiratory failure, or both,<sup>(4,5)</sup> based on the profile of lung ultrasound findings, together with screening for leg vein thrombosis. This approach, designated the BLUE protocol, can provide immediate answers to situations in which only slow, sophisticated techniques had previously been available.<sup>(1,23)</sup> The BLUE protocol divides lung ultrasound findings into distinct profiles (Figure 8).

In summary, a lung ultrasound examination demonstrating a normal lung pattern (lung sliding with A-lines) should be combined with screening for leg vein thrombosis. If signs of leg vein thrombosis are found, the finding is specific for pulmonary embolism; otherwise, the pattern is suggestive of respiratory dysfunction due to bronchospasm. The absence of lung sliding, together with the presence of A-lines, is suggestive of pneumothorax; however, for the diagnosis of pneumothorax, it is necessary to identify the lung point.<sup>(1)</sup> In addition, in patients with pulmonary infection, lung ultrasound findings might correspond to the presence of anterior consolidations; to areas with no lung sliding and with a predominance of B-lines; to asymmetric findings between the hemithoraces; or to the identification of a normal pattern associated with the presence of pleural effusion and posterior consolidation.<sup>(23)</sup>

One study combined the abovementioned lung ultrasound findings and proposed an algorithm for the evaluation of patients with acute respiratory failure (Figure 9).<sup>(23)</sup> In that study, lung ultrasound, performed shortly after the patients had been admitted to the ICU, was



**Figure 7** – Lung ultrasound images showing loss of lung aeration. In A, the tissue-like sign, i.e., intercostal space with the presence of lung parenchyma and diaphragm (curved light line) on a solid organ. In B, the shred sign, i.e., intercostal space with hypoechoic image with irregular borders on the lung parenchyma. Adapted from Lichtenstein.<sup>(1)</sup>

found to have an accuracy of 90.5% in relation to the final diagnosis made by the team of attending physicians.<sup>(23)</sup>

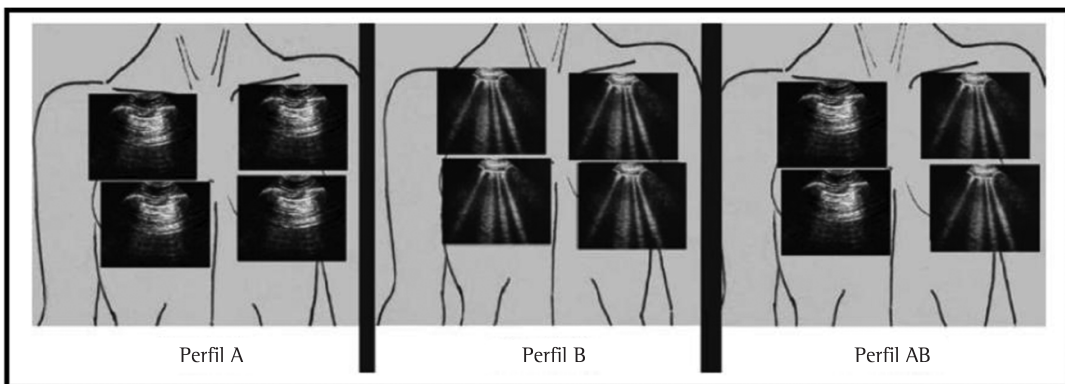
## Monitoring the response to interventions

The response to clinical interventions can be monitored by lung ultrasound. A study evaluating patients with renal failure and pulmonary congestion demonstrated that the reduction in the number of B-lines was proportional to the reduction in the volume of extravascular lung water, which was accompanied by clinical improvement of the patients.<sup>(22)</sup> In contrast, in patients with hemodynamic instability requiring fluid resuscitation, there are difficulties in obtaining a parameter to limit the administration of fluids. Lichtenstein et al. correlated lung ultrasound artifacts with the hemodynamic values measured in patients with pulmonary artery catheters.<sup>(24)</sup> The authors found a good correlation between the predominance of A-lines on lung ultrasound and a pulmonary artery occlusion pressure of less than 18 mmHg, concluding that A-predominance indicates lung tolerance to fluid therapy. However, if B-predominance replaces A-predominance following fluid therapy, this indicates interstitial syndrome, probably from a hydrostatic mechanism.<sup>(24)</sup>

In a study involving patients with ventilator-associated pneumonia, there was a high correlation between lung ultrasound findings and CT findings in terms of lung re-aeration, a factor that is directly associated with a positive response to antimicrobial agents. In fact, the opposite was also observed, given that patients who presented with decreased aeration of the lung parenchyma (as determined by lung ultrasound and CT) experienced treatment failure.<sup>(25)</sup> In addition, because lung ultrasound evaluates lung re-aeration, it can be useful as a complementary tool to evaluate positive end-expiratory pressure-induced alveolar recruitment.<sup>(26)</sup>

## Aiding in procedures

Lung ultrasound increases the success and safety of thoracentesis, increasing the yield of the procedure and reducing the incidence of iatrogenic pneumothorax, even in patients on positive pressure ventilation.<sup>(5,6,10,17,27,28)</sup> It is recommended that a pleural effusion of at least 15 mm in thickness be

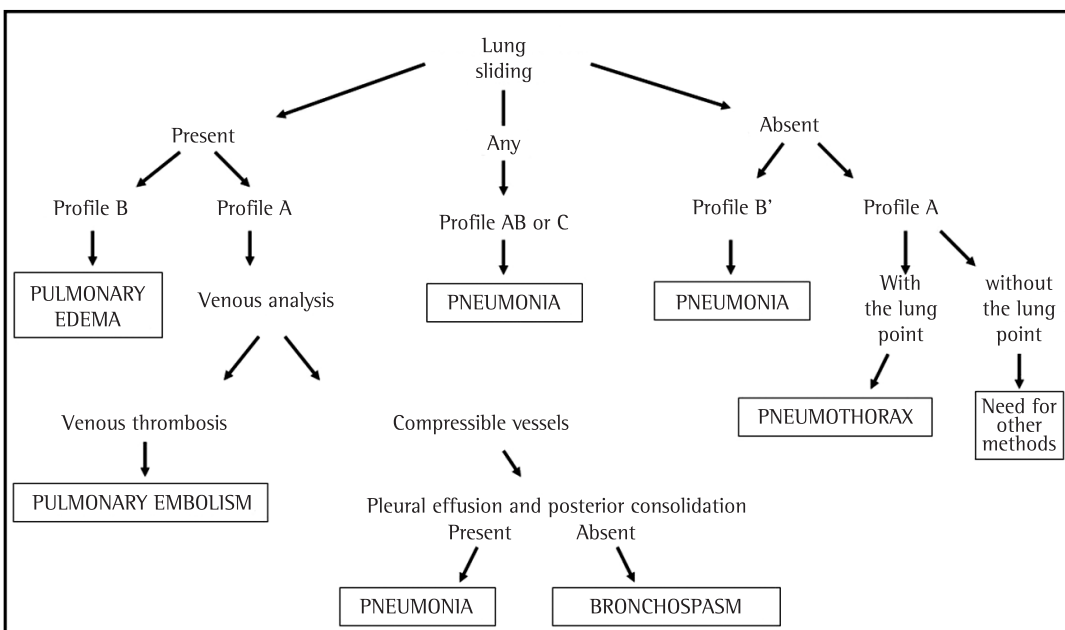


**Figure 8** – Profiles of lung ultrasound findings in patients with respiratory failure. The A profile is defined by the presence of lung sliding and A-lines, practically ruling out congestion. The B profile (lung sliding, together with a predominance of B-lines) practically rules out pneumothorax, bronchospasm, and pulmonary embolism, being suggestive of pulmonary edema. The AB profile (asymmetric findings) is suggestive of pneumonia. Adapted from Lichtenstein et al.<sup>(23)</sup>

identified before the procedure is performed. In addition, some authors have recommended the routine use of lung ultrasound before invasive procedures (catheterization, drainage, and biopsy) are performed, because when lung sliding is found to be present before the procedure, the absence of lung sliding after the intervention is strong evidence of iatrogenic pneumothorax.<sup>(6,19)</sup>

**Other applications**

Lung ultrasound can be useful in the evaluation of diaphragmatic function, through the evaluation of diaphragmatic movement during a deep inhalation, as well as through tidal volume and the sniff test.<sup>(6)</sup> In addition, diaphragmatic movement can be a good predictor of successful



**Figure 9** – Algorithm for the evaluation of acute respiratory failure based on lung ultrasound findings. Definitions of the profiles: profile A, presence of lung sliding and A-lines; profile AB, asymmetric findings; profile B, lung sliding, together with a predominance of B-lines; profile B', presence of B-lines and absence of lung sliding; and profile C, presence of consolidations or areas of atelectasis, together with pleural effusion or not. Adapted from Lichtenstein et al.<sup>(23)</sup>



extubation of critically ill patients,<sup>(29)</sup> whereas ultrasound-guided chest tube drainage can accelerate weaning from mechanical ventilation.<sup>(28)</sup>

Lung ultrasound can confirm correct endotracheal tube placement by showing the presence of bilateral lung sliding, a promising application of the method.<sup>(30)</sup>

Peris et al. evaluated the implementation of a protocol for routine lung ultrasound examination of patients admitted to the ICU and found a reduction in the total number of X-rays and CT scans taken. It is of note that the reduction in costs did not translate to worse outcomes in the study population.<sup>(16)</sup>

## Limitations

Because lung ultrasound is an operator-dependent method, there is a need for training bedside physicians so that they can perform the examination correctly and be responsible for the consequent interventions.<sup>(4,6,21,31)</sup> Because lung ultrasound is a newly developed tool, there is a lack of professionals trained in using the method.<sup>(31)</sup> In addition, there is a lack of specific criteria for the training and certification of professionals in the various fields of medicine.<sup>(5,6)</sup> It has been proposed that lung ultrasound examination be standardized in order to facilitate learning and clinical follow-up.<sup>(8)</sup>

Another limitation of the method is that, because lung ultrasound examination is essentially dynamic, it is difficult to document and store lung ultrasound findings appropriately for subsequent comparisons.<sup>(6)</sup> In addition, the presence of obesity, dressings, or subcutaneous emphysema can preclude the use of lung ultrasound. Furthermore, because the presence of air is the greatest enemy of ultrasound, abnormalities surrounded by air cannot be evaluated by the method.<sup>(6)</sup> Fortunately, most acute diseases extend to the periphery of the lung.<sup>(4)</sup>

Finally, if the choice is made to use lung ultrasound, it is essential to maintain a strict disinfection protocol to prevent the transmission of infections.<sup>(3,5)</sup>

## Final considerations

Lung ultrasound is a technique that has been increasingly used and can provide accurate and relevant information for the diagnosis and treatment of acutely ill patients. This new tool,

which has the potential to revolutionize the practice of pulmonology,<sup>(5)</sup> has been used by nonspecialists in combination with clinical evaluation and physical examination, providing data that complement those obtained by other currently available imaging methods.

A simple, focused, and virtually dichotomous examination allows us to infer the presence or absence of a variety of pathologies, guiding the investigation and monitoring the response to clinical interventions.

Although specific criteria regarding training and certification are still lacking, lung ultrasound is a fast, inexpensive, and widely available tool. This technique should progressively come to be more widely incorporated into the care of critically ill patients.

## References

1. Lichtenstein D. Should lung ultrasonography be more widely used in the assessment of acute respiratory disease? *Expert Rev Respir Med.* 2010;4(5):533-8. PMID:20923333. <http://dx.doi.org/10.1586/ers.10.51>
2. Gargani L. Lung ultrasound: a new tool for the cardiologist. *Cardiovasc Ultrasound.* 2011;9:6. PMID:21352576 PMID:3059291. <http://dx.doi.org/10.1186/1476-7120-9-6>
3. Bouhemad B, Zhang M, Lu Q, Rouby JJ. Clinical review: Bedside lung ultrasound in critical care practice. *Crit Care.* 2007;11(1):205. PMID:17316468 PMID:2151891. <http://dx.doi.org/10.1186/cc5668>
4. Mayo PH. Ultrasound evaluation of the lung. In: Levitov A, Mayo PH, Slonim AD, editors. *Critical care ultrasonography.* New York: McGraw-Hill; 2009. p. 251-8.
5. Anantham D, Ernst A. Ultrasonography. In: Mason RJ, Broaddus VC, Murray JF, Nadel JA, editors. *Murray and Nadel's textbook of respiratory medicine.* 5th ed. Philadelphia: Saunders-Elsevier; 2010. p. 445-60.
6. Koenig SJ, Narasimhan M, Mayo PH. Thoracic ultrasonography for the pulmonary specialist. *Chest.* 2011;140(5):1332-41. PMID:22045878. <http://dx.doi.org/10.1378/chest.11-0348>
7. Reissig A, Copetti R, Kroegel C. Current role of emergency ultrasound of the chest. *Crit Care Med.* 2011;39(4):839-45. PMID:21263325. <http://dx.doi.org/10.1097/CCM.0b013e318206d6b8>
8. Tutino L, Cianchi G, Barbani F, Batacchi S, Cammelli R, Peris A. Time needed to achieve completeness and accuracy in bedside lung ultrasound reporting in intensive care unit. *Scand J Trauma Resusc Emerg Med.* 2010;18:44. PMID:20701810 PMID:2928170. <http://dx.doi.org/10.1186/1757-7241-18-44>
9. Frassi F, Gargani L, Gligorova S, Ciampi Q, Mottola G, Picano E. Clinical and echocardiographic determinants of ultrasound lung comets. *Eur J Echocardiogr.* 2007;8(6):474-9. PMID:17116422. <http://dx.doi.org/10.1016/j.euje.2006.09.004>
10. Eisen L, Doelken P. Ultrasound evaluation of the pleura. In: Levitov A, Mayo PH, Slonim AD, editors. *Critical care ultrasonography.* New York: McGraw-Hill; 2009. p. 245-50.

11. Via G, Lichtenstein D, Mojoli F, Rodi G, Neri L, Storti E, et al. Whole lung lavage: a unique model for ultrasound assessment of lung aeration changes. *Intensive Care Med.* 2010;36(6):999-1007. PMID:20221746. <http://dx.doi.org/10.1007/s00134-010-1834-4>
12. Soldati G, Sher S. Bedside lung ultrasound in critical care practice. *Minerva Anesthesiol.* 2009;75(9):509-17. PMID:19644435.
13. Diacon AH, Brutsche MH, Solèr M. Accuracy of pleural puncture sites: a prospective comparison of clinical examination with ultrasound. *Chest.* 2003;123(2):436-41. PMID:12576363. <http://dx.doi.org/10.1378/chest.123.2.436>
14. Zanobetti M, Poggioni C, Pini R. Can chest ultrasonography replace standard chest radiography for evaluation of acute dyspnea in the ED? *Chest.* 2011;139(5):1140-7. PMID:20947649. <http://dx.doi.org/10.1378/chest.10-0435>
15. Balik M, Plasil P, Waldauf P, Pazout J, Fric M, Otahal M, et al. Ultrasound estimation of volume of pleural fluid in mechanically ventilated patients. *Intensive Care Med.* 2006;32(2):318-21. PMID:16432674. <http://dx.doi.org/10.1007/s00134-005-0024-2>
16. Peris A, Tutino L, Zagli G, Batacchi S, Cianchi G, Spina R, et al. The use of point-of-care bedside lung ultrasound significantly reduces the number of radiographs and computed tomography scans in critically ill patients. *Anesth Analg.* 2010;111(3):687-92. <http://dx.doi.org/10.1213/ANE.0b013e3181e7cc42>
17. Tu CY, Hsu WH, Hsia TC, Chen HJ, Tsai KD, Hung CW, et al. Pleural effusions in febrile medical ICU patients: chest ultrasound study. *Chest.* 2004;126(4):1274-80. PMID:15486393. <http://dx.doi.org/10.1378/chest.126.4.1274>
18. Saucier S, Motyka C, Killu K. Ultrasonography versus chest radiography after chest tube removal for the detection of pneumothorax. *AACN Adv Crit Care.* 2010;21(1):34-8. PMID:20118702. <http://dx.doi.org/10.1097/NCI.0b013e3181c8013a>
19. Vezzani A, Brusasco C, Palermo S, Launo C, Mergoni M, Corradi F. Ultrasound localization of central vein catheter and detection of postprocedural pneumothorax: an alternative to chest radiography. *Crit Care Med.* 2010;38(2):533-8. PMID:19829102. <http://dx.doi.org/10.1097/CCM.0b013e3181c0328f>
20. Wilkerson RG, Stone MB. Sensitivity of bedside ultrasound and supine anteroposterior chest radiographs for the identification of pneumothorax after blunt trauma. *Acad Emerg Med.* 2010;17(1):11-7. PMID:20078434. <http://dx.doi.org/10.1111/j.1553-2712.2009.00628.x>
21. Ding W, Shen Y, Yang J, He X, Zhang M. Diagnosis of pneumothorax by radiography and ultrasonography: a meta-analysis. *Chest.* 2011;140(4):859-66. PMID:21546439. <http://dx.doi.org/10.1378/chest.10-2946>
22. Noble VE, Murray AF, Capp R, Sylvia-Reardon MH, Steele DJ, Liteplo A. Ultrasound assessment for extravascular lung water in patients undergoing hemodialysis. Time course for resolution. *Chest.* 2009;135(6):1433-9. PMID:19188552. <http://dx.doi.org/10.1378/chest.08-1811>
23. Lichtenstein DA, Mezière GA. Relevance of lung ultrasound in the diagnosis of acute respiratory failure: the BLUE protocol. *Chest.* 2008;134(1):117-25. PMID:18403664. <http://dx.doi.org/10.1378/chest.07-2800>
24. Lichtenstein DA, Mezière GA, Lagoueyte JF, Biderman P, Goldstein I, Gepner A. A-lines and B-lines: lung ultrasound as a bedside tool for predicting pulmonary artery occlusion pressure in the critically ill. *Chest.* 2009;136(4):1014-20. PMID:19809049. <http://dx.doi.org/10.1378/chest.09-0001>
25. Bouhemad B, Liu ZH, Arbelot C, Zhang M, Ferarri F, Le-Guen M, et al. Ultrasound assessment of antibiotic-induced pulmonary re-aeration in ventilator-associated pneumonia. *Crit Care Med.* 2010;38(1):84-92. PMID:19633538. <http://dx.doi.org/10.1097/CCM.0b013e3181b08cbb>
26. Bouhemad B, Brisson H, Le-Guen M, Arbelot C, Lu Q, Rouby JJ. Bedside ultrasound assessment of positive end-expiratory pressure-induced lung recruitment. *Am J Respir Crit Care Med.* 2011;183(3):341-7. PMID:20851923. <http://dx.doi.org/10.1164/rccm.201003-0369OC>
27. Mayo PH, Goltz HR, Tafreshi M, Doelken P. Safety of ultrasound-guided thoracentesis in patients receiving mechanical ventilation. *Chest.* 2004;125(3):1059-62. PMID:15006969. <http://dx.doi.org/10.1378/chest.125.3.1059>
28. Kupfer Y, Seneviratne C, Chawla K, Ramachandran K, Tessler S. Chest tube drainage of transudative pleural effusions hastens liberation from mechanical ventilation. *Chest.* 2011;139(3):519-23. Retraction in: *Chest.* 2012;141(1):284. PMID:20688921. <http://dx.doi.org/10.1378/chest.10-1012>
29. Jiang JR, Tsai TH, Jerng JS, Yu CJ, Wu HD, Yang PC. Ultrasonographic evaluation of liver/spleen movements and extubation outcome. *Chest.* 2004;126(1):179-85. PMID:15249460. <http://dx.doi.org/10.1378/chest.126.1.179>
30. Weaver B, Lyon M, Blaivas M. Confirmation of endotracheal tube placement after intubation using the ultrasound sliding lung sign. *Acad Emerg Med.* 2006;13(3):239-44. PMID:16495415. <http://dx.doi.org/10.1111/j.1553-2712.2006.tb01685.x>
31. Eisen LA, Leung S, Gallagher AE, Kvetan V. Barriers to ultrasound training in critical care medicine fellowships: a survey of program directors. *Crit Care Med.* 2010;38(10):1978-83.

## ***About the authors***

---

### ***Felippe Leopoldo Dexheimer Neto***

Internist and Intensivist. Ernesto Dornelles Hospital and Moinhos de Vento Hospital, Porto Alegre, Brazil.

### ***Paulo de Tarso Roth Dalcin***

Associate Professor. Department of Internal Medicine, Federal University of Rio Grande do Sul, Porto Alegre, Brazil.

### ***Cassiano Teixeira***

Internist and Intensivist. Moinhos de Vento Hospital and Santa Casa Sisters of Mercy Hospital of Porto Alegre, Porto Alegre, Brazil.  
Professor of Clinical Medicine, Federal University of Health Sciences of Porto Alegre, Porto Alegre, Brazil.

### ***Flávia Gabe Beltrami***

Resident. Department of Pulmonology, Porto Alegre *Hospital de Clínicas*, Porto Alegre, Brazil.