

Mesiodistal width and proximal enamel thickness of maxillary first bicuspid

Aurélio de Carvalho Macha^(a)

Flávio Vellini-Ferreira^(b)

Helio Scavone-Junior^(c)

Rívea Inês Ferreira^(c)

^(a)Research Fellow; ^(b)Professor and Chairman;

^(c)Associate Professor – Department of Pediatric Dentistry and Orthodontics, University of São Paulo City (UNICID), São Paulo, SP, Brazil.

Abstract: This study aimed at evaluating measurements relative to the mesiodistal crown width and enamel thickness of maxillary first bicuspid. The sample consisted of 40 extracted sound bicuspid (20 right and 20 left), selected from white patients (mean age: 23.7 ± 4.2 years), who were treated orthodontically with tooth extraction at a private clinic in São Paulo, SP, Brazil. All teeth were embedded in acrylic resin and cut along their long axis through the proximal surfaces, parallel to the buccal side, to obtain 0.6-mm central sections. The mesiodistal crown width and proximal enamel thickness were measured using a stereoscopic microscope connected to a computer. Measurements for right and left teeth, as well as the mesial and distal enamel thicknesses in the total sample, were compared by the Wilcoxon test ($\alpha = 0.05$). The mesiodistal crown width mean values found were 7.51 mm (± 0.54) on the right side and 7.53 mm (± 0.35) on the left side. The mean enamel thickness on the distal surfaces for both sides was 1.29 mm (right: s.d. = 0.12 and left: s.d. = 0.18). The mean values for the mesial surfaces were 1.08 mm (± 0.14) and 1.19 mm (± 0.25), on the right and the left sides, respectively. No significant differences were found between the crown measurements and enamel thicknesses on the left and right sides. However, enamel thickness was significantly greater on the distal surfaces. Reliable measurements of enamel thickness are useful to guide stripping, which may be an attractive alternative to tooth extraction because it allows the transverse arch dimension to be maintained.

Descriptors: Bicuspid; Tooth crown; Dental enamel; Orthodontics.

Introduction

Enamel stripping on the proximal surfaces has routinely been used to correct tooth discrepancies and enhance arch stability.¹⁻³ This procedure may be an attractive alternative to tooth extraction because it allows the transverse arch dimension and anterior inclinations to be maintained.^{4,5} Nevertheless, a critical issue when performing stripping is to estimate the amount of proximal enamel to be removed, so that dentin exposure may be prevented.

Considering that previous studies^{6,7} have mentioned that about fifty percent of the whole proximal enamel thickness could be removed safely, reliable measurements of tooth crown dimensions and enamel thickness would constitute a useful guide to the orthodontist during the stripping procedure. Thus, the aim of the present study was to estimate the mesio-

Corresponding author:

Rívea Inês Ferreira

Universidade Cidade de São Paulo (UNICID)

Pós-Graduação (Mestrado em Ortodontia)

Rua Cesário Galeno, 448 - Bloco A

Tatuapé

CEP: 03071-000

São Paulo - SP - Brazil

E-mail: riveaines@yahoo.com

Received for publication on May 13, 2009

Accepted for publication on Nov 11, 2009

distal crown width and the proximal enamel thicknesses of maxillary first bicuspid.

Material and Methods

This study is in agreement with Resolution 196/96 from the National Health Council/Health Department (Brazil).

Sampling

An *in vitro* model consisting of 20 standardized repetitions would be statistically suitable for estimating the mesiodistal crown width and enamel thickness of eligible teeth from patients born in the same geographical area. Based on this methodological premise, 40 erupted sound human maxillary first bicuspid (20 right and 20 left) were collected from white adult patients aged 19-31 years (mean age: 23.7 ± 4.2 years), submitted to corrective orthodontic treatment with tooth extraction at a private clinic in the city of São Paulo, SP, Brazil. After extraction, the teeth were washed in saline solution to remove blood residues and then cleaned thoroughly with water.

Tooth preparation

All teeth were embedded in self-curing acrylic resin (Ucefex™ 2110, Elekeiroz S/A, São Paulo, SP, Brazil), using round plastic containers (Extex Corp., Enfield, CT, USA). The specimens ($n = 40$) were numbered and then separated into two groups according to the side: twenty from the left side and twenty from the right side.

The teeth were cut along their long axis through the proximal surfaces, parallel to the buccal surface, to obtain 0.6-mm central sections. Each cut section corresponded to the central area of the proximal surfaces, in that it encompassed the greater crown dimension and the thicker enamel portion. The cut sections were obtained using a 4-inch diameter, high concentration diamond wafering blade (Extex Corp., Enfield, CT, USA) mounted onto a high precision Isomet™ 1000 saw (Buehler, Lake Bluff, IL, USA), under water refrigeration to prevent organic component loss. To avoid damaging the specimens, the diamond disc speed was set at 200 rotations per minute.

The specimens were glued with cyanoacrylate adhesive (Super Bonder™, Loctite Corp., Itapevi, SP, Brazil) on glass slides (Star Frost™, Knittel Glaser, Braunschweig, Lower Saxony, Germany) and diaphanized in 100% xylol for ten minutes, three times consecutively. This procedure increased transparency, so that the cut sections could be better visualized under the microscope. Otherwise, the dentinoenamel junction (DEJ) could not be clearly depicted.

Taking measurements

The cut sections were placed under a stereoscopic microscope (Wild M3Z, Leica™, Wetzlar, Hessen, Germany) connected to a computer. Digital images were acquired by a coupled camera (Eclipse™ E-6000, Nikon Corp., Tokyo, Japan) and imported into the Image Pro-Plus™ software (Media Cybernetics, Silver Spring, MD, USA) for taking tooth measurements.

A calibrated operator used the software tools to trace the outer borders of the mesial and distal surfaces at the contact areas, designated L1 and L4, respectively. The line parallel to L1, corresponding to the DEJ on the mesial surface, was designated L2. On the distal surface, the above-mentioned inner border was designated L3. The sections were assessed at six and a half times magnification (Figure 1). Subsequently, the distances between L1-L4 (mesiodistal crown width), L1-L2 (mesial enamel thickness) and L3-L4 (distal enamel thickness) were measured using the software ruler.

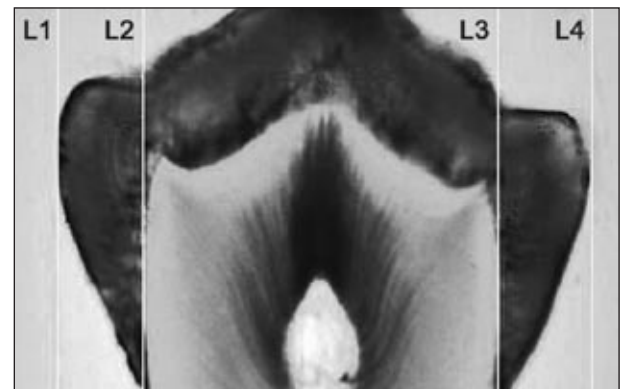


Figure 1 - Proximal enamel extension limited by lines parallel to the tooth's long axis (mesial: L1-L2 and distal: L3-L4).

Statistical analyses

Minimum and maximum values, medians, means and the respective standard deviations of the L1-L4, L1-L2 and L3-L4 distances were calculated and represented as box plots. The right and left mesiodistal crown widths and proximal enamel thicknesses, as well as the mesial and distal enamel thicknesses, were compared using the Wilcoxon test. The significance level was set at 5%.

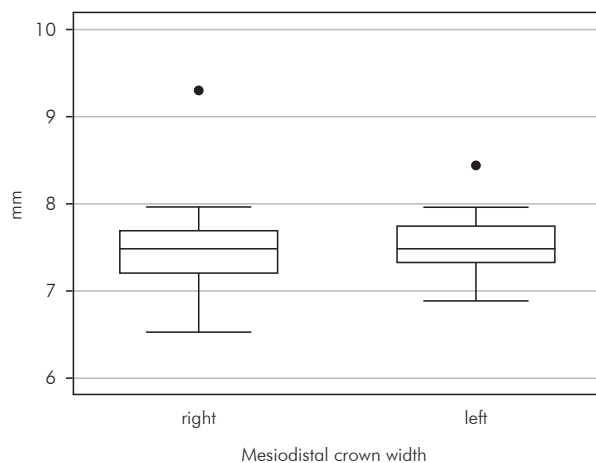
Results

Graph 1 summarizes the data distribution for the crown width dimensions. Although the right teeth presented a smaller minimum value (6.53 mm) and a greater maximum value (9.30 mm) in relation to the left teeth (6.88 mm and 8.44 mm, respectively), the medians were quite similar (approximately 7.5 mm). According to the box plots shown in Graph 2, the distal enamel thickness measurements were greater than those observed for the mesial surface. The mean values of the mesiodistal crown dimension as well as the enamel thickness observed for the maxillary first bicusps are shown in Table 1.

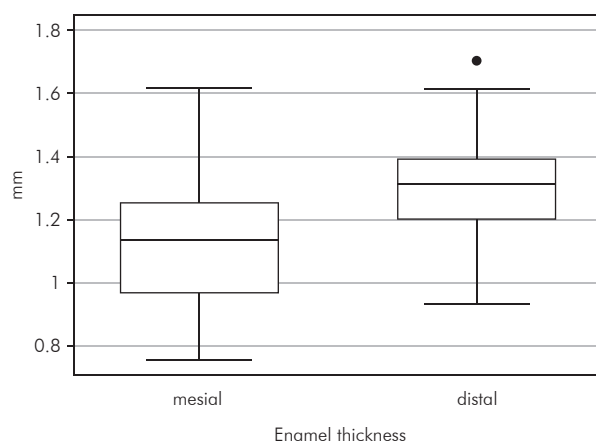
No significant differences were found between measurements taken on the right and the left teeth (Table 1). However, distal enamel thickness mean values (1.29 mm on both sides) were significantly greater than the values observed for the mesial surfaces (1.08 mm for the right teeth and 1.19 mm for the left teeth), $p = 0.0003$. The average mesiodistal crown width for the right and left teeth corresponded to 7.51 mm and 7.53 mm, respectively.

Discussion

The main indication of enamel reduction, also called enamel reproximation, during orthodontic treatment planning is particularly related to the challenging borderline malocclusions with a mild or moderate degree of crowding.^{5,7} Some authors⁴ have advocated stripping in cases of Class I arch-length discrepancies with orthognathic profiles, minor Class II dental malocclusions - especially those in which patients have stopped growing - and Bolton tooth-size discrepancies. Germeç and Taner⁵ (2008) reported that stripping combined with nonextraction therapy provided effective results for treating



Graph 1 - Box plots representing the distribution pattern for measurements (mm) of mesiodistal crown width of right and left maxillary first bicusps.



Graph 2 - Box plot diagrams illustrating the distribution pattern for the measurements (mm) of proximal enamel thickness of the mesial and distal surfaces of maxillary first bicusps.

Table 1 - Comparative assessment of the measurements taken for the right and left maxillary first bicusps.

Variable	Mean* (SD)	Wilcoxon test
Crown width (right side)	7.51 (0.54)	$p = 0.7228$
Crown width (left side)	7.53 (0.35)	
Mesial enamel thickness (right side)	1.08 (0.14)	$p = 0.0759$
Mesial enamel thickness (left side)	1.19 (0.25)	
Distal enamel thickness (right side)	1.29 (0.12)	$p = 0.9851$
Distal enamel thickness (left side)	1.29 (0.18)	

* Mean values are expressed in millimeters.

Class I borderline patients. This protocol decreased treatment time by 8 months and, at the end of treatment, patients had well-balanced and desirable facial esthetics. A certain degree of mandibular incisors crowding relapse may occur, but appears to be acceptable.³

A gain of at least 7 mm might be expected with 50% of proximal enamel reduction.^{1,4} In selected patients, stripping has the advantage – over extraction therapy – of a significant decrease in treatment time because the amount of tooth structure removed corresponds approximately to the amount of crowding.⁷ From a clinical point of view, orthodontists should also take the patient's opinion into account, since many people may be unwilling to undergo tooth extraction.⁴ By enamel reduction, space may be created and teeth can be reshaped to a more ideal form.⁸ Lower incisor reproximation can improve stability by slightly narrowing the teeth and broadening their proximal surfaces to resist contact slippage.⁹ Furthermore, with enamel reduction and cosmetic recontouring, the long-term maintenance of mandibular incisor alignment is possible², and the transverse arch dimension as well as anterior inclinations may be sustained.⁴ The preserved intercanine width and the broadened contact surfaces can help prevent posttreatment relapse.⁷

Therefore, clinicians should be aware of the applicable methods for estimating the amount of tooth structure that can be safely removed. To avoid any damage to the tissues under the enamel, it is highly recommended that orthodontists willing to perform enamel reduction use accurate radiographs for measuring the amount of enamel to be grinded, since proximal enamel thickness may vary among different people and in the same individual.^{10,11} The use of computed tomography has also been registered for measuring enamel thickness.¹² More recently, the use of cone beam computed tomography has been suggested for measuring tooth crown dimensions.¹³ Orthodontists need good quality radiographic images and may also use commercially available gauges accurate to within one-tenth of a millimeter to measure the interproximal site after stripping.¹⁴

Nevertheless, it is important to have some idea about the actual tooth crown dimensions. In the

present study, histological data are provided pertaining to the proximal enamel thickness, and to the mesiodistal crown width of maxillary first bicuspid. As shown in Table 1, proximal enamel thickness mean values ranged from 1.08 mm to 1.29 mm. Proximal enamel was significantly thicker on the distal surface, in comparison with the mesial surface. Actually, the reference mean values presented in this paper may offer a valid contribution to clinicians for stripping procedures. However, it must be noted that genetic background plays a prominent role in determining many phenotypic traits, such as tooth size. The marked influence of intrinsic factors on tooth formation justifies the conducting of future studies involving tooth crown measurements in different ethnic groups.

To date, there are few studies reporting mean values of proximal enamel thickness for maxillary first bicuspid. Radiographic assessment of mandibular first bicuspid estimated enamel thickness for mesial and distal surfaces at 0.99 mm and 1.07 mm, respectively.⁴ In another study¹⁵ using tooth sectioning, the proximal enamel thickness values calculated for maxillary first bicuspid were 1.48 mm on mesial surfaces and 1.54 mm on distal surfaces. In fact, these differences may be attributed to methodological and ethnic variations.

According to the findings of this study, during treatment planning, orthodontists should consider that the average mesiodistal crown width of maxillary first bicuspid is about 7.5 mm. Moreover, in agreement with previous investigations,^{1,4,5,14} the suggested thresholds for proximal enamel reduction may be in the interval of 0.4-0.5 mm, irrespective of the side. Based on Table 1, the enamel reduction could be slightly more pronounced on the distal surfaces.

In clinical practice, the most commonly used techniques for enamel reduction require hand-held abrasive strips, handpiece-mounted diamond-coated disks and tungsten-carbide or diamond burs.² It should be borne in mind that all stripping methods may roughen the enamel surfaces.² Hence, polishing the stripped enamel is highly advisable. On the other hand, air-rotor stripping has not been related to an increase in the incidence of proximal enamel caries lesions.⁷

Frictional heat is a registered side effect of stripping procedures, and appropriate measures should be taken particularly for high-speed handpiece stripping.⁸ Air cooling should be preferred to air-water sprays because it provides greater visibility.⁸ Thermal changes may lead to pulpal reactions. However, periodontal diseases do not seem to increase after enamel reduction.³

Some authors have focused their studies on tooth size discrepancies and/or enamel-dentin differences based on ethnicity,^{10,16-21} gender^{10,22,23} and dentition phase.²⁴ Since Brazilians may be considered one of the most ethnically varied populations in the world as regards their origin, mostly of European and African descent, it would seem rather difficult to classify them according to specific ethnic groups. Ad-

ditionally, it has been suggested that the amount of enamel reduction would not be influenced by gender, since tooth crown dimensions are mainly related to dentin thickness variability rather than to enamel thickness variability.²³

Conclusions

1. According to the results of the present study, the mean mesiodistal crown width observed for the maxillary first bicuspid examined was approximately 7.5 mm.
2. The mean values obtained for proximal enamel thickness were significantly greater on the distal surfaces (1.29 mm for both sides) than on the mesial surfaces (1.08 mm for the right side and 1.19 mm for the left side).

References

1. Rossouw PE, Tortorella A. Enamel reduction procedures in orthodontic treatment. *J Can Dent Assoc.* 2003 Jun;69(6):378-83.
2. Arman A, Cehreli SB, Ozel E, Arhun N, Cetinsahin A, Soyman M. Qualitative and quantitative evaluation of enamel after various stripping methods. *Am J Orthod Dentofacial Orthop.* 2006 Aug;130(2):131.e7-14.
3. Zachrisson BU, Nyøygård L, Mobarak K. Dental health assessed more than 10 years after interproximal enamel reduction of mandibular anterior teeth. *Am J Orthod Dentofacial Orthop.* 2007 Feb;131(2):162-9.
4. Stroud JL, English J, Buschang PH. Enamel thickness of the posterior dentition: its implications for nonextraction treatment. *Angle Orthod.* 1998 Apr;68(2):141-6.
5. Germeç D, Taner TU. Effects of extraction and nonextraction therapy with air-rotor stripping on facial esthetics in postadolescent borderline patients. *Am J Orthod Dentofacial Orthop.* 2008 Apr;133(4):539-49.
6. Demange C, François B. Measuring and charting interproximal enamel removal. *J Clin Orthod.* 1990 Jul;24(7):408-12.
7. Jarjoura K, Gagnon G, Nieberg L. Caries risk after interproximal enamel reduction. *Am J Orthod Dentofacial Orthop.* 2006 Jul;130(1):26-30.
8. Baysal A, Uysal T, Usumez S. Temperature rise in the pulp chamber during different stripping procedures. *Angle Orthod.* 2007 May;77(3):478-82.
9. Rinchuse DJ, Miles PG, Sheridan JJ. Orthodontic retention and stability: a clinical perspective. *J Clin Orthod.* 2007 Mar;41(3):125-32.
10. Hall NE, Lindauer SJ, Tüfekçi E, Shroff B. Predictors of variation in mandibular incisor enamel thickness. *J Am Dent Assoc.* 2007 Jun;138(6):809-15.
11. Scotti R, Villa L, Carossa S. A radiologic method for determining the thickness of the hard crown tissues. *J Prosthet Dent.* 1989 Dec;62(6):633-7.
12. Spoor CF, Zonneveld FW, Macho GA. Linear measurements of cortical bone and dental enamel by computed tomography: applications and problems. *Am J Phys Anthropol.* 1993 Aug;91(4):469-84.
13. Sakabe J, Kuroki Y, Fujimaki S, Nakajima I, Honda K. Reproducibility and accuracy of measuring unerupted teeth using limited cone beam X-ray CT. *Dentomaxillofac Radiol.* 2007 Jan;36(1):2-6.
14. Chudasama D, Sheridan JJ. Guidelines for contemporary air-rotor stripping. *J Clin Orthod.* 2007 Jun;41(6):315-20.
15. Shillingburg HT Jr, Grace CS. Thickness of enamel and dentin. *J South Calif Dent Assoc.* 1973 Jan;41(1):33-52.
16. Merz ML, Isaacson RJ, Germane N, Rubenstein LK. Tooth diameters and arch perimeters in a black and white population. *Am J Orthod Dentofacial Orthop.* 1991 Jul;100(1):53-8.
17. Buschang PH, Demirjian A, Cadotte L. Permanent mesiodistal tooth size of French-Canadians. *J Can Dent Assoc.* 1988 Jun;54(6):441-4.
18. Ghose LJ, Baghdady VS. Analysis of the Iraqi dentition: mesiodistal crown diameters of permanent teeth. *J Dent Res.* 1979 Mar;58(3):1047-54.
19. Macko DJ, Ferguson FS, Sonnenberg EM. Mesiodistal crown dimensions of permanent teeth of Black Americans. *ASDC J Dent Child.* 1979 Jul-Aug;46(4):314-8.

20. Richardson ER, Malhotra SK. Mesiodistal crown dimension of the permanent dentition of American Negroes. *Am J Orthod.* 1975 Aug;68(2):157-64.
21. Bishara SE, Jakobsen JR, Abdallah EM, Fernandez Garcia A. Comparisons of mesiodistal and buccolingual crown dimensions of the permanent teeth in three populations from Egypt, Mexico and the United States. *Am J Orthod Dentofacial Orthop.* 1989 Nov;96(5):416-22.
22. Alvesalo L, Tammisalo E. Enamel thickness of 45, X females' permanent teeth. *Am J Hum Genet.* 1981 May;33(3):464-9.
23. Stroud JL, Buschang PH, Goaz PW. Sexual dimorphism in mesiodistal dentin and enamel thickness. *Dentomaxillofac Radiol.* 1994 Aug;23(3):169-71.
24. Jensen E, Kai-Jen Yen P, Moorrees CF, Thomsen SO. Mesiodistal crown diameters of the deciduous and permanent teeth in individuals. *J Dent Res.* 1957;36(1):39-47.