

COMPARISON OF ENDOSCOPIC AND MICROSURGICAL METHODS IN THE TREATMENT OF LUMBAR DISC HERNIATIONS

COMPARAÇÃO DE MÉTODOS ENDOSCÓPICOS E MICROQUIRÚRGICOS NO TRATAMENTO DE HÉRNIAS DE DISCO LOMBAR

COMPARACIÓN DE MÉTODOS ENDOSCÓPICOS Y MICROQUIRÚRGICOS EN EL TRATAMIENTO DE HERNIAS DE DISCO LUMBAR

SERGEY ARESTOV¹, ALEXEY KASHCHEEV¹, ARTEM GUSHCHA¹

1. Neurology Research Center of the Russian Academy of Sciences, Department of Neurosurgery, Volokolamskoe Avenue, Moscow.

ABSTRACT

Objective: The development of minimally invasive spine surgery leads us to reflect on the efficiency of new methods compared with older ones. In the case of endoscopic spine surgery, we always seek to compare our results using new techniques with the results of older and trusted microsurgical techniques. Unfortunately, there are few reliable studies measuring endoscopic and microsurgical approaches. We therefore decided to compare our treatment results with those of what are, in our opinion, the best and most thorough studies found. Furthermore, we found no illustrated experience in the usability of endoscopic methods. We therefore analyzed each step of the technique used, according to the practical experience with microsurgical discectomy. **Methods:** We compared our two-year experience of treatment of 183 patients with lumbar disc herniations using the endoscopic technique, with data reported in the literature on microsurgical minimally invasive methods. **Results:** Our group achieved good to excellent results in 92.9% of cases (170 patients) compared to 90% reported in the literature. We compared the capabilities of endoscopic discectomy with microsurgical methods, and concluded that the endoscopic method is sufficient to perform any movement inside the surgical field that is microscopically possible. It is also possible to perform any type of spinal cord decompression, with better visualization provided by the endoscope. **Conclusions:** We conclude that endoscopic microdiscectomy is a good and reliable alternative, with better outcomes and more efficient usage of the approach space.

Keywords: Herniated disc; Endoscopy; Spine; Surgery.

RESUMO

Objetivo: O desenvolvimento da cirurgia minimamente invasiva da coluna vertebral leva-nos a refletir sobre a eficiência de novos métodos e os mais antigos. No caso da cirurgia endoscópica da coluna, sempre buscamos comparar nossos resultados com técnicas novas com os de técnicas microcirúrgicas antigas e confiáveis. Infelizmente, há poucos estudos confiáveis que medem os acessos endoscópicos e microcirúrgicos. Decidimos, portanto, comparar nossos resultados de tratamento com aqueles que consideramos os melhores e mais completos estudos encontrados. Além disso, não encontramos experiência ilustrada na usabilidade dos métodos endoscópicos. Assim sendo, analisamos cada etapa da técnica utilizada, de acordo com a experiência em discectomia microcirúrgica. **Métodos:** Comparamos nossos dois anos de experiência no tratamento de 183 pacientes com hérnias de disco lombar utilizando técnica endoscópica com os dados da literatura sobre métodos microcirúrgicos minimamente invasivos. **Resultados:** Nosso grupo atingiu resultados bons e excelentes em 92,9% dos casos (170 pacientes) em comparação com 90% relatados na literatura. Comparamos os recursos do acesso por discectomia endoscópica e dos métodos microcirúrgicos e concluímos que o método endoscópico é suficiente para realizar qualquer movimento dentro do campo cirúrgico que seria microscopicamente possível. É possível fazer qualquer tipo de decompressão da medula espinal com melhor visualização fornecida pelo endoscópio. **Conclusões:** Concluímos que a microdiscectomia por acesso endoscópico é uma alternativa boa e confiável, com resultados melhores e uso mais eficiente do espaço de abordagem.

Descritores: Hérnia de disco; Endoscopia; Coluna espinhal; Cirurgia.

RESUMEN

Objetivo: El desarrollo de la cirugía minimamente invasiva de la columna nos lleva a reflexionar sobre la eficiencia de los nuevos métodos y los más antiguos. En el caso de la cirugía endoscópica de la columna, siempre buscamos comparar nuestros resultados con técnicas nuevas con los de técnicas microquirúrgicas antiguas y confiables. Desafortunadamente, hay pocos estudios confiables que miden los accesos endoscópicos y microquirúrgicos. Decidimos, por lo tanto, comparar nuestros resultados de tratamiento con aquellos que consideramos los mejores y más completos estudios encontrados. Además, no encontramos experiencia ilustrada sobre la usabilidad de los métodos endoscópicos. Por lo tanto, analizamos cada etapa de la técnica utilizada, de acuerdo a la experiencia en discectomia microquirúrgica. **Métodos:** Comparamos nuestros años de experiencia en el tratamiento de 183 pacientes con hernias de disco lumbar utilizando la técnica endoscópica con los datos de la literatura sobre los métodos microquirúrgicos mínimamente invasivos. **Resultados:** Nuestro grupo

Study conducted at the neurosurgical department of the Neurology Research Center in Moscow.

Correspondence: Neurology Research Center of the Russian Academy of Sciences, Department of Neurosurgery, 80 Volokolamskoe Avenue, Moscow 125367 - Artem Gushcha – agou@endospine.ru

alcanzó resultados buenos y excelentes en el 92,9% de los casos (170 pacientes) en comparación con los 90% reportados en la literatura. Comparamos los recursos del acceso por discectomía endoscópica y de los métodos microquirúrgicos y concluimos que el método endoscópico es suficiente para realizar cualquier movimiento dentro del campo quirúrgico que sería microscópicamente posible. Es posible realizar cualquier tipo de descompresión de la médula espinal con la mejor visualización proporcionada por el endoscopio. Conclusiones: Concluimos que la microdiscectomía por acceso endoscópico es una alternativa buena y confiable, con resultados mejores y un uso más eficiente del espacio de abordaje.

Descriptores: Hernia de disco; Endoscopia; Columna espinal; Cirugía.

INTRODUCTION

According to current data from the WHO, 80-83% of adults worldwide have lumbar disc herniations. Given that most of these are working, middle aged-people, and that this disease prevents them from working, finding the most effective method of treatment is very important to mitigate this social problem.

There is no objective data as to which surgical method should be used, and why. Most neurosurgeons worldwide currently use the more common approaches, despite their high level of invasiveness.

According to the North American Spine Society (NASS), an operation is considered minimally invasive if it involves a smaller skin incision. Implementing a smaller incision in most cases doesn't reflect soft and bony structures' damage. This latter fact is of primary importance when it comes to maintaining the structural mechanical stability of the spine after surgery.

Actually, all existing surgical procedures cause some damage to the mechanical structures of the spine, and there should be a good balance between performing an efficient operation (relieving the patient's pain) and minimizing operative trauma. Thus, making the most of an existing surgical approach to the spine is essential. Historically the best "gold standard" method is microsurgical discectomy. Indeed, this method enables any pathology within the vertebral canal to be removed, while affording the best visualization and comfort for the operating surgeon. On the other hand, it makes poor usage of the approach space. It can be compared with flashlight cone of light with an incision that limits the movements inside the cone. This effect comprises of necessity to avoid instruments countering and shading point of view. Positioning the endoscope inside the wound gives the effect of "eye inside", sacrificing the 3D binocular view.

Some studies have confirmed that microsurgical approaches cause more damage to the soft tissues.¹ According to the same study, it was noted that this technique causes a significant increase in the number of undesirable dural tears. This occurs due to limitations in the use of the minimally invasive retractor, significantly reducing the convenience for the surgeon and thereby reducing the quality of the surgical operation. Therefore, for the comparison group, the "open" method of herniated intervertebral disc removal was chosen as the most effective and reliable method to achieve the surgical objective.

For the endoscopic method of herniated intervertebral disc removal, the use of a tubular distractor with endoscopic assistance was chosen. This method was first used in 2003, by the company Medtronic (MetrX system), but it was perfected thanks to Ryang et al.² in 2007. This is not a purely endoscopic method. Actually there is no suitable classification of endoscopic methods, besides that of the American Medical Organization, which divides all existing approaches into four fundamentally different techniques:

- A. Percutaneous - the operation is performed by instruments that directly pass through the skin under X-ray control or by any other kind of indirect visualization.
- B. Endoscopic - the operation is performed through the working channel in the endoscope.
- C. Minimally invasive - the surgeon operates under the control of vision, and for the approach, any distractors can be used (tubular or other) to reduce the surgical effect on the surrounding soft tissue. Visualization is performed using a microscope or endoscope.
- D. Open - the surgeon operates under direct vision of the surgical wound. It is performed through an open incision. This access includes removal of bone and ligaments in the area of surgical interest.

According to this classification, this method is minimally invasive with video-assistance.

The main technical disadvantage compared with the operating microscope was, and still is, the lack of a three-dimensional vision of structures in the access area. In 2008, we performed a detailed comparison of endoscopic and microsurgical removal of disc herniations,³ which showed no difference in the clinical outcome of the operation, but with earlier recovery of patients and a significant improvement in their quality of life after endoscopic discectomy. Over the next ten years, the development of endoscopic technology has led to the emergence of more advanced methods, but still there is no detailed analysis of their effectiveness in the literature.

METHODS

Our study included 956 patients operated during past 10 years in our clinic (from 2007 to 2016). For the comparison, we used data from an article by Koebbe et al.,⁴ which was published in the journal *Neurosurgical Focus*, in 2002. This study was selected as it included the largest known group of patients - 3000 patients with herniated intervertebral discs of the lumbosacral spine. The comparison was made based on the clinical effect of the operation, using the MacNab scale (Table 1). The table shows the compliance of the symptoms with the MacNab criteria. The literature indicates that the method is effective if a good to excellent result is achieved using the MacNab scale. In this case, the effectiveness of the method can be measured as a sum of good and excellent results, expressed as a percentage.⁴

The study included patients aged from 20 to 69 years with radicular pain syndrome that lasted more than 4 weeks after ineffective conservative treatment. The diagnosis was confirmed by MRI study. We excluded patients with repeated operations on the spine at the same level, and patients with confirmed spinal instability or hypermobility of this spinal segment. Patients with spinal canal stenosis and/or spondylolisthesis were also excluded. All patients in the group underwent a full neurological examination before the operation, after the operation, and 6 months after the operation. The effectiveness according to the MacNab scale was measured accordingly.

There were 956 patients, 507 men and 449 women, with a median age of 38 years.

Surgical Technique

In past years, this method with tubular distractor and endoscopic assistance has become the routine method, and this operation is performed in all cases with lumbar disc herniation.

Anesthesia and patient positioning

All operations were performed using general anesthesia. A chest-knee position was preferred, to reduce intraoperative hemorrhage from the epidural veins,⁵ to reduce the necessary resection of bone

Table 1. MacNab scale.

Results	Symptoms
Excellent	Complete disappearance of symptoms
Good	Some pain persisted by patient discharge
Average	Some pain persisted by discharge but disappeared within one to four months of the operation
Poor	Disc herniation reappeared, requiring revision surgery

structures during the approach due to flexing of the spine, and to maximize intralaminar space.

The first stage of the operation was fluoroscopic control at the intervention site. A sterile needle was used for intramuscular injection. A lot of information can be obtained by the position of the needle, which can be decisive for the success of the operation (Figure 1).

First we need to position the needle strictly perpendicular to the patient's skin as we obtain an approach vector to plan the skin incision. Using fluoroscopic vision, the needle is positioned in the direction of the desired intervertebral disc. After clarifying the spinal level using x-ray, the position of the intervertebral disc relative to the skin incision is noted. If, at the same time, the lamina is visualized on the approach plane, it is advisable to displace the center of the incision somewhat caudally, to better visualize the yellow ligament and to be able to work more comfortably in the intralaminar space.

We also consider it necessary, at this stage, to position the port properly in relation to bone structures, as any excessive damage to these structures can lead to postoperative mechanical instability. Thus we attempt to minimize damage to intervertebral joint by sacrificing the edge of the underlying lamina.

A skin incision is performed 0.5 cm lateral to the middle line (Figure 2a), and a linear incision is performed in the muscle aponeurosis. A tubular distractor is then positioned in the desired intervertebral space using the muscle-puncturing technique, and is fixed to the operating table, using the holder (Figure 2b).

The intralaminar space is freed from the soft tissues, and the yellow ligament is opened. We recommend opening the yellow ligament using a blunt instrument due to the lack of 3D and lack of wound-depth perception, creating a high probability of undesired durotomy when the yellow ligament is opened with a sharp instrument. After partial resection of the yellow ligament, we consider it most appropriate to visualize the site of the spinal nerve root. In this case, the mechanism of turning the endoscope over the port helps to visualize the areas behind the intervertebral joint and prevent excessive damage to the bony structures (Figure 3).

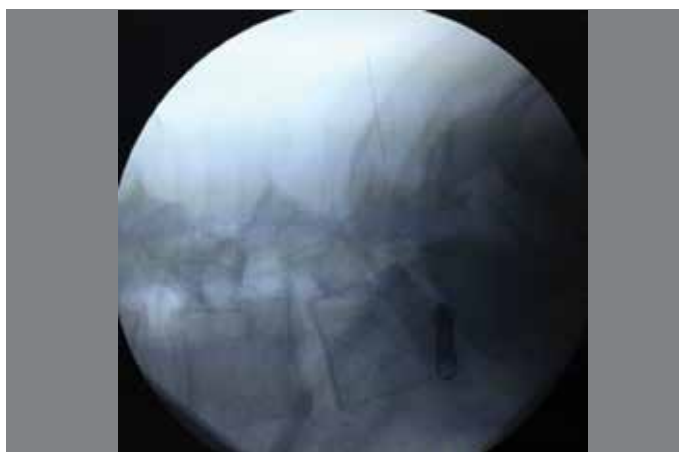


Figure 1. Skin incision positioning under fluoroscopic control.

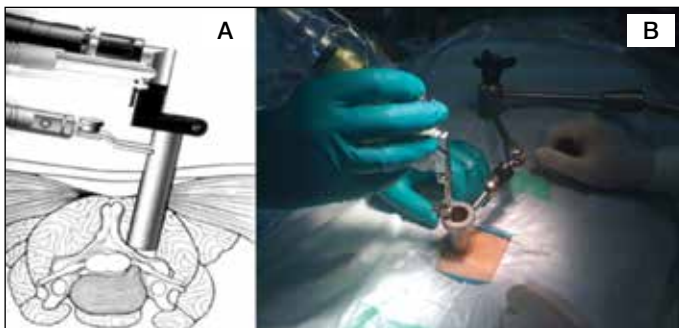


Figure 2. Positioning and fixing of endoscopic port.

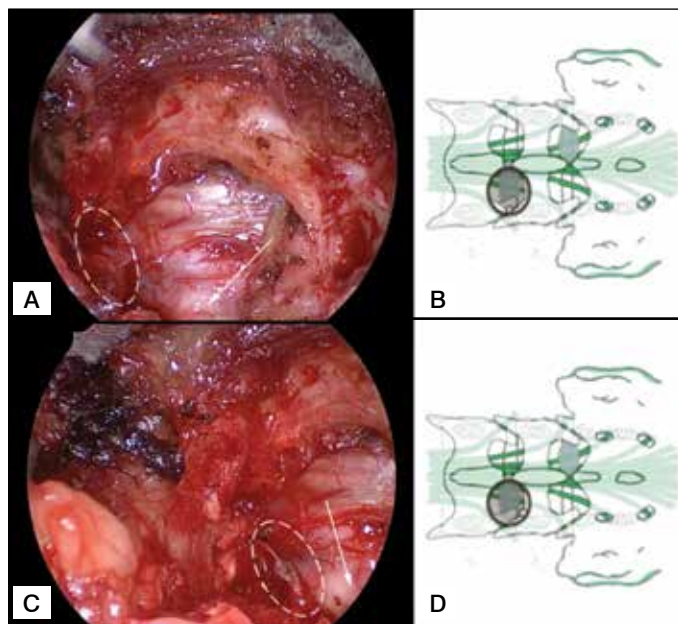


Figure 3. Point of view change during endoscope turning. A – white line is the zone of interest with an arrow showing the nerve root. B – schematic of an endoscope position. C – operating field view after endoscope turned counter-clockwise with a schematic view in D.

After nerve displacement, the herniation of the intervertebral disc is dissected and removed. Precise attention should be paid to hemostasis throughout the operation, as excessive bleeding is undesirable and limits visualization. In our experience, aggressive removal of the disc herniation without proper dissection usually causes damage to the ventral veins, which may result in significant bleeding and even lead the surgeon to switch back to microsurgery. Every and each neurosurgical procedure have in it's goal decompression of neural structures or restoration of continuity of neural structures. So there is no point in removing anything that doesn't compress neural structures. But we always perform opening and removal of the posterior longitudinal ligament and foraminotomy. The first is performed due to the possibility of the existence of a disc herniation fragment just below the ligament, with possible extrusion of the nerve root shortly after the operation. The second, foraminotomy, is performed to allow for the nerve tissue swelling that occurs after any operation. In our opinion, having additional space around the nerve root results in a better early post-op period. Lastly, we apply excessive hydraulic pressure inside the disc by inserting saline inside the disc. This excessive pressure mimics pressure on the intervertebral disc after verticalization and prevents the recurrence of early disc herniation. Lastly, we did not perform disc curettage in any case, because according to the literature, this procedure carries a high risk of spondylodiscitis.

The opinion number of the ethics committee Intervertebral Disc Displacement (Tree Number(s): C05.116.900.307, C23.300.707.952 MeSH Unique ID: D007405), Discectomy (Tree Number(s): E04.555.200 MeSH Unique ID: D017586), Neuroendoscopy (Tree Number(s): E01.370.376.525, E01.370.388.250.700, E04.502.250.700, E04.525.562 MeSH Unique ID: D044583)

RESULTS

In ten-year period from 2007 to 2016, 956 patients with lumbar herniated discs were operated on (Table 2).

The neurological status of patients before the operation varied according to the intensity of the radicular pain syndrome and the duration of the disease. Immediately after the operation, the majority of patients had complete regression of radicular pain syndrome. All patients were subjected to the same restrictions on activity - restriction

Table 2. Patients and disc relapses by year.

Year	2007	2008	2009	2010	2011	2012	2013	2014	2015	2016
Patients	9	34	52	49	55	95	94	175	190	203
Relapses	0	0	1	0	1	0	1	1	2	3

of axial loads and compulsory wearing of an orthopedic lumbar brace for one month after the operation.

Of the 956 patients in our group there were 9 disc herniation relapses (0.94%) and these patients were reoperated. Twenty-four patients experienced prolonged pain for a month or more after discharge, and were classified as average results by the MacNab scale (2.5%). In 38 cases (3.97%), radicular pain was observed during the hospital stay and fully disappeared within a month after the operation, requiring prolonged conservative treatment. These patients were considered as having an average result too. In 58 (6.07%) patients, we observed radicular pain in the same dermatome as before the operation, which fully regressed in postoperative day 1. The remaining 827 patients (86.5%) had complete disappearance of all symptoms and returned to normal life soon after discharge from hospital. Thus, the efficiency of the endoscopic method was achieved in 885 cases 92.57%. In the comparison group, based on the study of Koebbe et al.,⁴ excellent and good results were 90%, the incidence of complications was 2% (damage to the dural sac and damage to the nerve roots). The rate of reoperations was 5%, due to recurrence of the herniation.

During this work, we compared the technical characteristics of endoscopic discectomy and the usability of this method compared to the microsurgical technique. It was noted that with the endoscopic method, it is possible to use standard microsurgical instruments, and due to the technical possibility of rotation of the endoscope around the port, we assume that endoscopic discectomy is more efficient in using the approach space during the procedure.

DISCUSSION

The analysis of the results of herniated disc removal using the portal endoscopic method at 6 postoperative months showed that this technique is highly effective and less traumatic. According to our data, the effectiveness of portal endoscopic microdiscectomy

for the removal of herniated intervertebral discs is 92.57%, while in microsurgical discectomy it was 90%, according to the literature.⁴

The most significant complication of both types of surgery was relapse of herniated intervertebral discs. In the first group of patients, relapse occurred in 1.1% of cases, and in the second group, in 5% of cases. Similar results may be associated with more significant aggression during surgical intervention and destabilization of the segment in the postoperative period, followed by the development of a disc herniation recurrence in the operated segment.

In 1.1% of cases with endoscopic microdiscectomy, there was damage to the dura mater, which did not lead to any symptoms. According to Koebbe et al.,⁴ dural tears occurred in 2% of cases.

Analysis of the technical capabilities of endoscopic microdiscectomy showed the possibility of using all standard microsurgical instruments during the operation without shading the visibility of the surgical intervention zone. Furthermore, the endoscopic approach significantly increases the efficiency of approach space usage.

Considering the low traumatism of access, less intensity bleeding was noted throughout the operation. However, the rate of use of standard bipolar coagulation was lower than for microsurgical coagulation due to the limited possibility of changing the instrument angle. We noted that the use of other methods of hemostasis, such as hemostatic sponge Spongostan and SurgiFlo, was more effective than bipolar coagulation in most cases.

CONCLUSION

Based on this study, it was concluded that endoscopic discectomy is more effective when compared with microsurgical techniques. Considering that this method is not inferior to the microsurgical method in its technical characteristics and capabilities, this technology can be used instead of the standard procedure, for the removal of herniated intervertebral discs. The technical capabilities of the method also allow for wide decompression of the nerve structures during surgery, which can be used to treat degenerative stenosis of the spinal canal in future.

All authors declare no potential conflict of interest related to this article.

CONTRIBUTION OF THE AUTHORS: Each author made significant individual contributions to this manuscript. SA, AK, AG performed the surgery and patient follow-up. They were also responsible for the concept of this article, and performed the evaluation and statistical analysis.

REFERENCES

1. Dasenbrock HH, Juraschek SP, Schultz LR, Witham TF, Sciubba DM, Wolinsky JP et al. The efficacy of minimally invasive discectomy compared with open discectomy: a meta-analysis of prospective randomized controlled trials. *J Neurosurg Spine*. 2012;16(5):452-62.
2. Ryang YM, Oertel MF, Mayfrank L, Gilsbach JM, Rohde V. Transmuscular trocar technique - minimal access spine surgery for far lateral lumbar disc herniations. *Minim Invasive Neurosurg*. 2007;50(5):304-7.
3. Shevelev IN, Goushcha AO, Konovalov NA, Arestov SO. Destandau Endoscopic Discectomy in Patients with Lumbar Intervertebral Disc Hernia. *Hirurgia Pozvonocnika*. 2008;(1):51-7.
4. Koebbe CJ, Maroon JC, Abla A, El-Kadi H, Bost J. Lumbar microdiscectomy: a historical perspective and current technical considerations. *Neurosurg Focus*. 2002;13(2):E3.
5. Rigamonti A, Gemma M, Rocca A, Messina M, Bignami E, Beretta L. Prone versus knee-chest position for microdiscectomy: a prospective randomized study of intra-abdominal pressure and intraoperative bleeding. *Spine (Phila Pa 1976)*. 2005;30(17):1918-23.