

DOES DECUBITUS AFFECT NEURAL ELEMENTS POSITIONING? A MRI STUDY COMPARING DORSAL AND LATERAL POSITION

O DECÚBITO AFETA A POSIÇÃO DOS ELEMENTOS NEURAI? ESTUDO DE RESSONÂNCIA MAGNÉTICA COMPARANDO A POSIÇÃO DORSAL E LATERAL

¿LA POSICIÓN AFECTA EL POSICIONAMIENTO DE LOS ELEMENTOS NEURALES? UN ESTUDIO DE RM QUE COMPARA LA POSICIÓN DORSAL Y LATERAL

LUCAS NUNES SALES DE MELO,¹ RAFAEL BARRETO SILVA,² JOSÉ CARLOS BARBE GONÇALVES,³ GABRIELA AIELLO FERNANDES PANTAROTO⁴

1. Fundação Centro Médico de Campinas, Campinas, SP, Brazil.
2. Instituto Wilson Mello, Campinas, SP, Brazil.
3. Instituto da Coluna de Campinas, Campinas, SP, Brazil.
4. Próton Diagnósticos, Campinas, SP, Brazil.

ABSTRACT

Objective: To evaluate the displacement of nerve structures according to the decubitus position of the patient in a magnetic resonance imaging (MRI) study. **Methods:** MRI was performed at a radiology clinic in 20 patients in dorsal and right lateral decubitus. The measurement considered was the shortest distance between the dura mater and the medial wall of the pedicle. **Results:** The largest measurement was 11.6 mm in left lateral decubitus, 12.2 mm in right lateral decubitus, 10.5 mm in right dorsal decubitus, and 9.2 mm in left dorsal decubitus. In some patients the space between the medial wall of the pedicle and the dura mater was larger when in lateral decubitus, while in others when in dorsal decubitus. The mean displacement of the measurements on the left was 1.14 mm and on the right 1.355 mm. **Conclusions:** The structures moved on average little more than 1 mm in the positions studied. The positioning of the patient for surgery does not change the space to be approached, being the surgeon's choice according to his learning curve. **Level of evidence II; Prospective study of lower quality.**

Keywords: Supine Position; Low Back Pain; Magnetic Resonance Imaging; Patient Positioning.

RESUMO

Objetivo: Avaliar o deslocamento das estruturas nervosas conforme o decúbito do paciente em um estudo de Ressonância Nuclear Magnética (RNM). **Métodos:** Foram realizadas RNM em 20 pacientes em uma clínica de radiologia em decúbito dorsal e lateral direito. A medida considerada será a menor distância entre a dura-máter e a parede medial do pedículo. **Resultados:** A maior medida em decúbito lateral esquerdo foi 11,6 mm, em decúbito lateral direito foi 12,2 mm, em decúbito dorsal direito foi 10,5 mm e no esquerdo, 9,2 mm. O espaço entre a parede medial do pedículo é maior em decúbito lateral em alguns pacientes e, em outros, em decúbito dorsal. O deslocamento médio das medidas à esquerda foi 1,14 mm e à direita 1,355 mm. **Conclusões:** As estruturas se deslocaram, em média, pouco mais de 1 mm nas posições estudadas. O posicionamento do paciente na cirurgia não muda o espaço a ser abordado, sendo de escolha do cirurgião, conforme a sua curva de aprendizado. **Nível de evidência II; Estudo prospectivo de menor qualidade.**

Descritores: Decúbito Dorsal; Dor Lombar; Imagem por Ressonância Magnética; Posicionamento do Paciente.

RESUMEN

Objetivo: Evaluar el desplazamiento de las estructuras nerviosas conforme al decúbito del paciente en un estudio de Resonancia Nuclear Magnética (RNM). **Métodos:** Fueron realizadas RNM en 20 pacientes en una clínica de radiología en decúbito dorsal y lateral derecho. La medida considerada será la menor distancia entre la duramadre y la pared medial del pedículo. **Resultados:** La mayor medida en decúbito lateral izquierdo fue 11,6 mm, en decúbito lateral derecho fue 12,2 mm, en decúbito dorsal derecho fue 10,5 mm y en el izquierdo, 9,2 mm. El espacio entre la pared medial del pedículo es mayor en decúbito lateral en algunos pacientes y, en otros, en decúbito dorsal. El desplazamiento promedio de las medidas a la izquierda fue 1,14 mm y a la derecha de 1,355 mm. **Conclusiones:** Las estructuras se desplazaron, en promedio, poco más de 1 mm en las posiciones estudiadas. El posicionamiento del paciente en la cirugía no cambia el espacio a ser abordado, siendo la elección del cirujano conforme a su curva de aprendizaje. **Nivel de evidencia II; Estudio prospectivo de menor calidad.**

Descriptor: Posición Supina; Dolor de la Región Lumbar; Imagen por Resonancia Magnética; Posicionamiento del Paciente.

INTRODUCTION

Low back pain is a serious public health problem worldwide. It is the second most common reason for attention in urgent care units, affecting around 85% of people around the world, moving more than \$200 billion USD annually, as well as being the main reason

for absence from work in individuals under the age of 45.^{1,2} In view of the relevance of this issue, new concepts in the treatment and management of this pathology are emerging rapidly, be they focused on drug therapy, conservative methods, the cost-effectiveness of treatment, or new surgical techniques.

Study conducted at the Instituto Wilson Mello, Campinas, SP, Brazil.

Correspondence: Lucas Nunes Sales de Melo. Rua Santo Antônio, 233, ap. 102, Cambuí, Campinas, SP, Brasil. 13024-440. lucasnmelo@gmail.com

<http://dx.doi.org/10.1590/S1808-185120201904233015>

Coluna/Columna. 2020;19(4):255-7



Received on 01/14/2020 accepted on 05/05/2020

Low back pain is multifactorial in origin, mainly associated with lumbar disc herniation (LDH), degenerative disc disease (DDD), mechanical axial pain, and lumbar canal stenosis, among many other pathologies. A small proportion of patients with low back pain have a formal indication of surgery.³ Over the years increasingly less invasive methods have been developed to treat this pathology, with the goals of shorter hospitalization, more rapid return to work, cost reduction, preservation of the biology of the organism, and the well-being of the patient. In addition to an anamnesis and careful clinical examination, some cases require complementary examinations, magnetic resonance imaging (MRI) being the gold standard for diagnosing the etiology of low back pain.

Endoscopic spinal surgery is gaining more and more ground in the surgical treatment of low back pain because it essentially proposes what was previously mentioned, being performed via transforaminal or interlaminar approach. The site of surgical intervention is small and performing this procedure requires a large learning curve.

Positioning the patient is a critical step for any surgical procedure and is elementary to the success of the intervention. The objective of this study is to analyze the positioning of the neural structures in relation to the medial wall of the pedicle according to the positioning of the patient during an MRI scan. The positioning of these structures may generate new directions in the positioning of patients and in endoscopic spinal surgery.

METHODS

This prospective study was approved by the Institutional Review Board as CAEE number 97173018.5.0000.5599. MRI scans in dorsal and right lateral decubitus were performed in 20 patients (n=20) at a clinic specialized in radiology. The isotropic volumetric T2 sequence on the same MRI device (RM Philips Achieva 1.5T) with cuts at a thickness of 1.0 mm was used for all the patients.

Twenty patients participated in this study (age: 36 ± 8 years), 15 of whom were women (75%) and 5 of whom were men (25%).

The measurement considered in the study was the smallest distance between the dura mater and the medial wall of the pedicle of L5 (Figure 1). All the measurements of the acquired images were taken by a single radiologist using multiplanar reconstruction imaging software on a dedicated workstation (Extended MR WorkSpace 2.6.3.5). The measurements were taken from T2-weighted saturated images. Patients with an MRI indication for the lumbar spine, previously requested by their attending physician, were included. All the study patients already had been diagnosed with some spinal pathology with an indication for the proposed examination. Patients under the age of 20 or over the age of 50, as well as those with a diagnosis of spinal deformity, intra- and extradural tumors, or spondylolisthesis, were excluded from the study.

The distribution of the data was verified by the Shapiro Wilk test and by inspection of asymmetry and kurtosis. The Student's t-test for paired samples was applied for the comparison between the measurements in the lateral decubitus and dorsal decubitus positions.

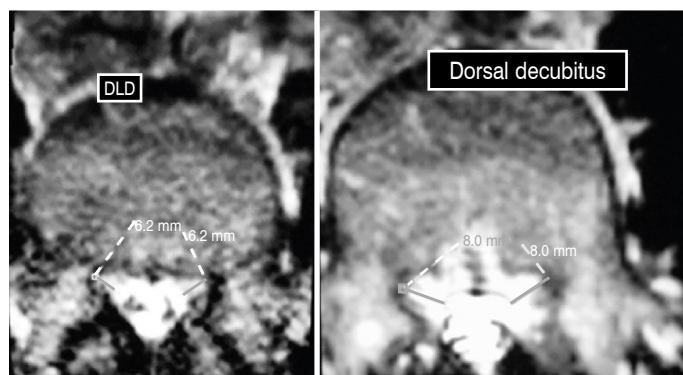


Figure 1. MR image in right lateral decubitus on the left and in right dorsal decubitus on the right, with their respective measurements.

In addition, the mean differences between the measurements of the decubitus positions and the respective intervals were presented with 95% confidence (CI 95%). Pearson's correlation coefficients were used to analyze the association between age and the differences observed between the lateral and dorsal decubitus positions on the right and left sides. All the analyses were conducted using PASW Statistics 18.0 software (SPSS Inc., Chicago, USA). The level of significance (α) adopted was 5% ($P < 0.05$).

RESULTS

There was no significant difference in the measurements of the differences between the lateral and dorsal decubitus positions on either the left side (mean difference = -0.36 mm; CI95% = -0.94 to 0.21; $P = 0.203$) or the right side (mean difference = -0.58 mm; CI95% = -1.29 to 0.14 mm; $P = 0.111$). The differences between the lateral and dorsal decubitus positions ranged from -1.8 to 2.4 mm on the left side and from -3.3 to 3.1 mm on the right side (Figure 2A and Figure 2B).

No significant association was observed between patient age and the differences between the measurements in the lateral and dorsal decubitus positions of the left ($r = -0.191$, $P = 0.435$) (Figure 3A) and right ($r = -0.240$, $P = 0.322$) (Figure 3B) sides.

DISCUSSION

Few studies in the medical literature have investigated the influence of the positioning of the nerve structures with a change in the position of the patient to perform imaging examinations. Magnetic resonance is the gold standard examination for the diagnosis of several degenerative spinal diseases, such as canal stenosis, disc

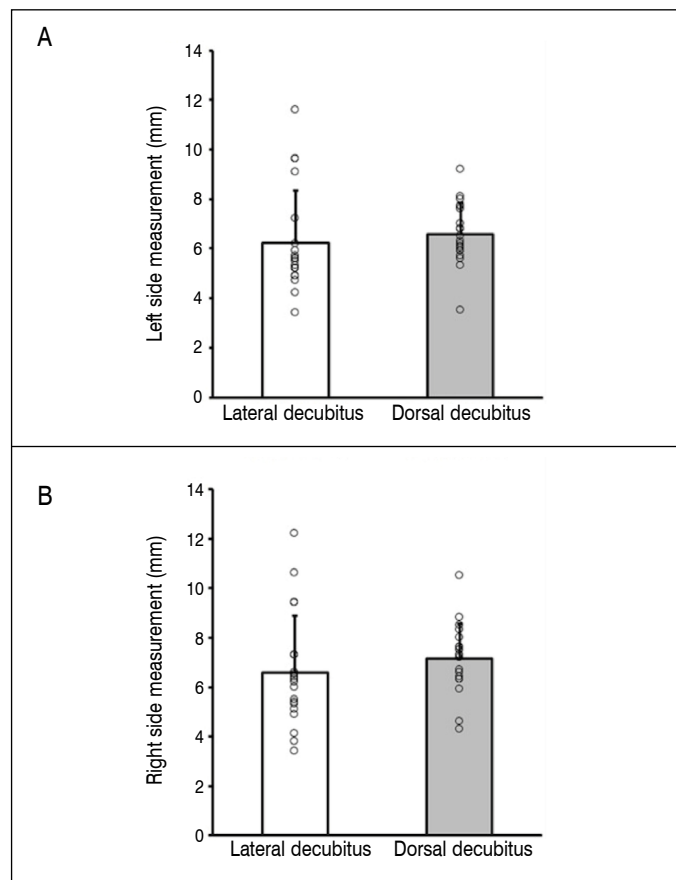


Figure 2. (A). displacement of the neural elements on the left side. (B). displacement of the neural elements on the right side. Data presented as mean (bars), standard deviation (line above the bar), and individual values (open circles).

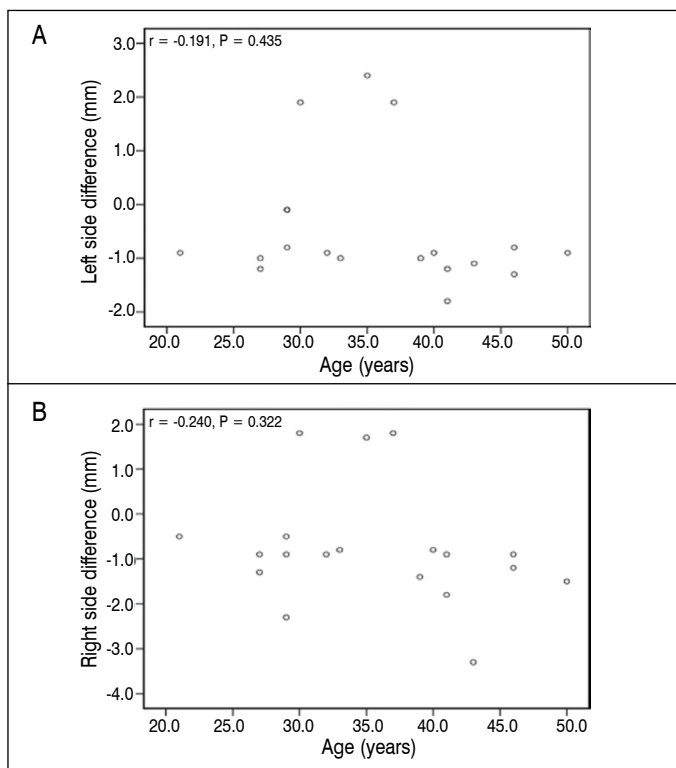


Figure 3. Association between age and difference in the nerve displacement on the left side (A) and the right side (B).

herniations, among other pathologies, as it shows greater detail in images both of soft tissue and bones.

In 2010, a study proposing to see spinal cord displacement in an MRI examination of the thoracic spine observed the patients in lateral inclination, sitting, and conventional examination positions and concluded that the distances between the posterior dura mater and the spinal cord were wider in the region of the apex of thoracic kyphosis and with the volunteer in the seated position (head down).⁴

In 2014, a case series studying the movement of the neurological structures in dynamic MRI scans reported the mean displacement of the structures to be three millimeters.⁵

Following the same reasoning, another study⁶ in 2016 showed that dynamic myelography was a crucial examination for the diagnosis of lumbar canal stenosis, since 23% of patients with this pathology have inconclusive MRI scans.

Another study compared the size of the dural sac during MRI

examinations in dorsal decubitus, in a standing position, and in myelographs, concluding that the scan in the standing position reproduced more clinical characteristics of the patients diagnosed with lumbar canal stenosis.⁷

The evolution of both complementary examinations and surgical techniques stimulates research, optimization, and innovation in the treatment of spinal diseases. Performing dynamic examinations and reproducing the surgical positioning of the patient when performing complementary examinations may prove to be crucial for surgical treatment of spinal pathologies.

In 2015, the size of the foramen was studied in 50 patients submitted to MRI scans in three different positions, dorsal decubitus, lateral inclination, and orthostasis with hyperlordosis and a change in diameter was observed, corroborating the idea that canal stenosis is a dynamic disease and conducting complementary examinations in different positions is a valid tool for the diagnosis and treatment of the disease.⁸

More recently, in 2018, a review of dynamic MRI scan performance showed that they can be useful in diagnosing diseases that go unnoticed in examinations conducted in the conventional position.⁹ Endoscopic spine surgery uses transforaminal and interlaminar approaches. Some schools of thought recommend transforaminal access from the lateral decubitus position, advocating the greater space between the nerve structures in comparison to ventral decubitus, while others prefer traditional positioning of the patient in ventral decubitus.

This study shows the real displacement of these structures by means of preoperative magnetic resonance examinations and was designed to compare the positioning of the patient in lateral decubitus with the traditional position (patient in dorsal decubitus).

This is a study bias, however, future studies could compare the displacement of the nerve structures in the resonance examination simulating the real surgical positions.

The study shows us that the choice of decubitus in relation to the increase of the space of the neurological structures is negligible, leading us to conclude that the surgeon can choose the positioning of the patient according to their preference, experience, and learning curve in spine surgery.

CONCLUSIONS

In this study, we observed that the structures shift on average a little more than 1 mm in the positions studied. The positioning of the patient for surgery does not change the space to be approached and is up to the surgeon in accordance with their learning curve.

The author declare no potential conflict of interest related to this article.

CONTRIBUTION OF THE AUTHORS: Each author made significant individual contributions to this manuscript. LNSM: intellectual concept and elaboration of the project, writing, discussion of the results, statistical analysis, and final review of the manuscript. RBS: intellectual concept and elaboration of the project, indication of the patients, review, and approval of the final version of the article. JCBG: intellectual concept, indication of the patients, review, and final approval of the final version of the article. GAFF: taking the measurements in the magnetic resonance examinations, patient selection.

REFERENCES

- Katz JN. Lumbar disc disorders and low-back pain: socioeconomic factors and consequences. *J Bone Joint Surg Am.* 2006;88(Suppl 2):21-4.
- Rubin DI. Epidemiology and risk factors for spine pain. *Neurol Clin.* 2007;25(2):353-71.
- Phillips FM, Slosar PJ, Youssef JA, Andersson G, Papatheofanis F. Lumbar Spine Fusion for Chronic Low Back Pain due to Degenerative Disc Disease: A Systematic Review. *Spine (Phila Pa 1976).* 2013;38(7):E409-22.
- Lee RA, van Zundert AA, Botha CP, Lataster LM, van Zundert TC, van der Ham WG, et al. The anatomy of the thoracic spinal canal in different postures: a magnetic resonance imaging investigation. *Reg Anesth Pain Med.* 2010;35(4):364-9.
- Koh J, Chaudhary V, Jeon EK, Dhillon G. Automatic spinal canal detection in lumbar MR images in the sagittal view using dynamic programming. *Comput Med Imaging Graph.* 2014;38(7):569-79.
- Michellini G, Corridore A, Torlone S, Bruno F, Marsecano C, Capasso R, et al. Dynamic MRI in the evaluation of the spine: state of the art. *Acta Biomed.* 2018;89(1-S):89-101.
- Kanno H, Endo T, Ozawa H, Koizumi Y, Morozumi N, Itoi E, et al. Axial loading during magnetic resonance imaging in patients with lumbar spinal canal stenosis: does it reproduce the positional change of the dural sac detected by upright myelography? *Spine (Phila Pa 1976).* 2012;37(16):E985-92.
- Kubosch D, Vicari M, Siller A, Strohm PC, Kubosch EJ, Knöller S, et al. The Lumbar Spine as a Dynamic Structure Depicted in Upright MRI. *Medicine (Baltimore).* 2015;94(32):e1299.
- Merkle M, Maier G, Danz S, Kaminsky J, Tatagiba MS, Hebela NM, et al. The value of dynamic radiographic myelography in addition to magnetic resonance imaging in detection lumbar spinal canal stenosis: A prospective study. *Clin Neurol Neurosurg.* 2016;143:4-8.