



CASE REPORT

Nasal reconstruction in Binder syndrome[☆]



Reconstrução nasal em paciente com síndrome de Binder

Helena Hotz Arroyo^{*}, Isabela Peixoto Olivetti, Vânia Garcia Wolf Santos, Raimar Weber, José Roberto Parisi Jurado

Universidade de São Paulo (FM-USP), Faculdade de Medicina, São Paulo, SP, Brazil

Received 23 April 2015; accepted 20 August 2015

Available online 17 October 2015

Introduction

Binder syndrome is a rare congenital malformation (maxillonasal dysplasia), which was first described in 1939 by Noyes, whereas it was Binder who defined it as a syndrome in 1962.^{1,2} Clinically, there is enlarged nasal angle (arhinoid face), abnormal position of the nasal bones, hypoplastic maxillary, hypoplasia/reduction of the nasal spine, absence/hypoplasia of the frontal nasal sinus (not obligatory), and atrophy of the nasal mucosa.^{2,3} In addition, some cases (40–50%) may present malformation in cervical vertebrae – most frequently, the C1 and C2 vertebrae are affected.³

Case report

A 16 year-old female patient came to our department with a complaint of “midfacial retrusion and flat nose” since childhood. She denied nasal obstruction, trauma, previous surgery and comorbidities. Physical examinations revealed the presence of convex lip, nasomaxillary hypopla-

sia, plan nasofrontal angle, acute nasolabial angle, nasal mucosa atrophy, triangular nostrils and flat nose (Fig. 1A and D). A computer tomography of the paranasal sinuses was performed and revealed absence of nasal spine, reduced horizontal dimensions of the jaw, nasal septal cartilage aplasia, obtuse nasofrontal angle, and retracted position of the jaw relative to the cranial base (Fig. 1A). No cervical disease was found.

The diagnosis of Binder syndrome was made according to clinical and radiological findings. Augmentation rhinoplasty was performed with autologous costal cartilage and remaining septal cartilage. The goal was to increase the nasal dorsum, to allow tip projection and support, projection of the premaxillary region and increase nasal lengthening. The following grafts were carved: dorsal onlay graft with costal cartilage, extended columellar strut, lateral crural strut graft, Sheen Shield graft and premaxillary graft (Fig. 1C and F). The two-month postoperative result can be seen in Fig. 1B and E, with adequate gain in dorsum projection, tip and premaxilla. The esthetic and functional results were quite satisfactory.

Discussion

Binder syndrome is a rare congenital deformity, and the most common characteristics presented are flattened nose and midfacial retrusion, as we saw on the patient described.

The diagnosis of Binder syndrome is made on the basis of standard clinical and radiologic findings. Genetic review can also be helpful.⁴ The real cause of this disease is still

[☆] Please cite this article as: Arroyo HH, Olivetti IP, Santos VG, Weber R, Jurado JR. Nasal reconstruction in Binder syndrome. Braz J Otorhinolaryngol. 2017;83:488–9.

^{*} Corresponding author.

E-mail: helenaharroyo@hotmail.com (H.H. Arroyo).

Peer Review under the responsibility of Associação Brasileira de Otorrinolaringologia e Cirurgia Cérvico-Facial.

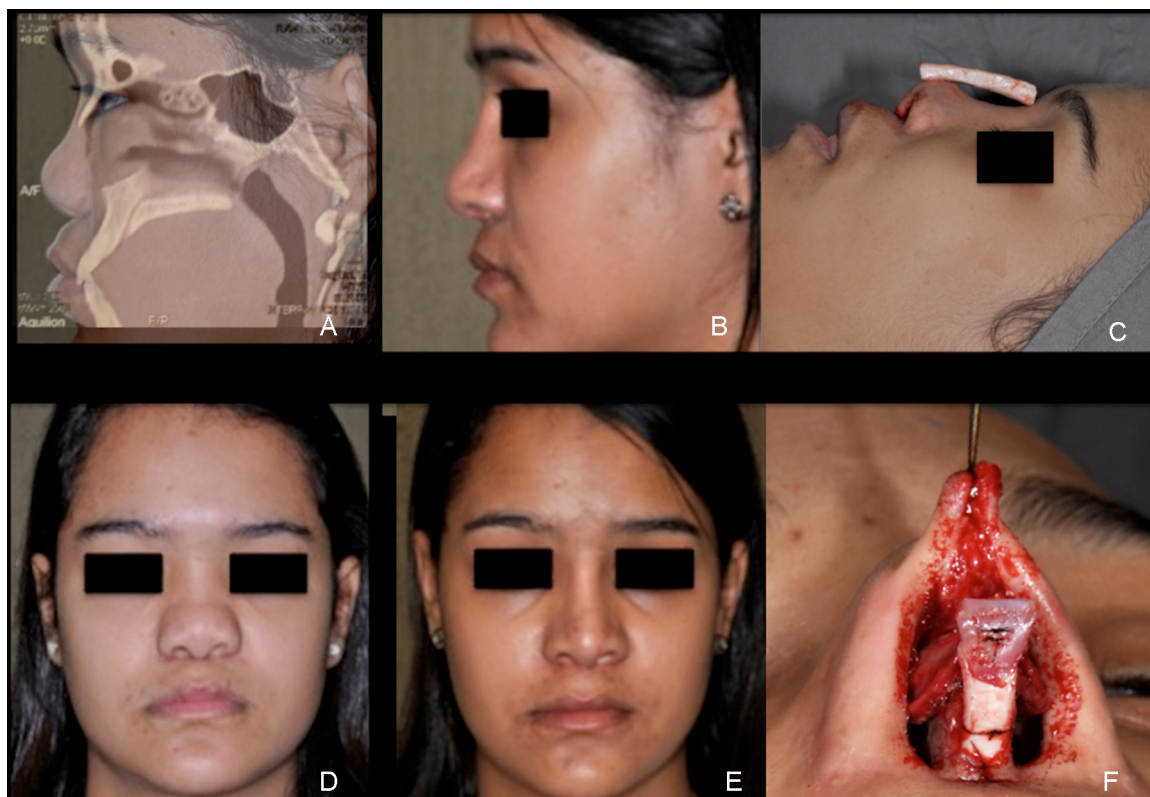


Figure 1 (A) Preoperative profile and sagittal CT. (B) Postoperative profile view. (C) Intraoperative: costal cartilage for onlay dorsum graft. (D) Preoperative frontal view. (E) Postoperative frontal view. (F) Intraoperative: tip and columellar grafts.

obscure, though the inhibition of the ossification center that would normally form the lateral and inferior borders of the piriform aperture during the fifth and sixth week of pregnancy, leading to a localized hypoplasia of the upper jaw and thus resulting in a retracted columellar/lip junction and lack of the normal triangular flare in the lower part of the columella, has been suggested as cause.⁴ However, the etiology of the syndrome is not yet clear; it is believed that it is an association of both the genetic and environmental factors (vitamin K deficiency during pregnancy). Birth trauma has also been proposed.

The treatment is controversial and should be performed according to the age and disease severity. Patients with milder forms of the disease may benefit from rhinoplasty only, as the case presented here. Moreover, the Class 3 malocclusion patients require orthognathic correction before nasal reconstruction.⁵

Conclusion

The case report presents the craniofacial characteristics compatible with Binder syndrome, as supported by the

literature. The knowledge of ideal proportions of the face helped us to achieve the correct diagnosis of the syndrome and its proper treatment.

Conflicts of interest

The authors declare no conflicts of interest.

References

1. Noyes FB. Case report. *Angle Orthod.* 1939;9:160–5.
2. Binder KH. Dysostosis maxillo-nasalis, ein archinencephaler Missbildungskomplex. *Dtsch Zahnarztl Z.* 1962;6:438–44.
3. Chiang C, Xue K, Gu B, Li Q, Liu K. A novel single-rib recombination method in binder syndrome treatment. *Ann Plast Surg.* 2013;70:659–62.
4. Chummun S, McLean NR, Nugent M, Anderson PJ, David DJ. Binder syndrome. *J Craniofac Surg.* 2012;23:986–90.
5. Holmes AD, Lee SJ, Greensmith A, Heggie A, Meara JG. Nasal reconstruction for maxillonasal dysplasia. *J Craniofac Surg.* 2010;21:543–51.