

# Determination of phytoconstituents of *n*-hexane extract of leaves of *Morus nigra* and evaluation of their effects on biochemical and histopathological parameters in paracetamol intoxicated mice liver

Tauqeer Hussain Mallhi<sup>1\*</sup>, Muhammad Imran Qadir<sup>2\*</sup>, Yusra Habib Khan<sup>3</sup>

<sup>1</sup> Department of Pharmacy Practice, Faculty of Pharmaceutical Sciences, Government College University Faisalabad, Faisalabad, Pakistan, <sup>2</sup>Institute of Molecular Biology & Biotechnology, Bahauddin Zakariya University, Multan, Pakistan, <sup>3</sup>Institute of Pharmacy, Lahore College for Women University, Lahore, Pakistan

*In-vitro* investigation of *Morus nigra* L. (Moraceae) has demonstrated the evidence of several antioxidant compounds. Current study was aimed to determine the phytoconstituents and hepatoprotective potential of *n*-hexane extract of *Morus nigra*. Swiss albino mice were divided into five groups: normal control, paracetamol control, silymarin control, 250 mg/kg p.o. extract for 7 days plus paracetamol 3 h later, 500 mg/kg p.o. extract for 7 days plus paracetamol 3 h later. Serum levels of liver enzymes and total bilirubin were assessed and compared between the groups by using one-way ANOVA to confirm hepatoprotective activity. HPLC analysis revealed the presence quercetin, oleanolic acid, luteolin, apigenin, vitamin C and kuwanon C. *n*-hexane extract of *Morus nigra* at dose of 250 mg/kg reduced elevated ALT by 54.3% ( $p < 0.001$ ), AST by 55.1% ( $p < 0.01$ ), ALP by 28.5% ( $p < 0.01$ ) and TBR by 56.4% ( $p < 0.01$ ) as compared to paracetamol control. The dose of 500 mg/kg of the extract reduced the ALT levels by 62.9% ( $p < 0.001$ ), AST by 56.7% ( $p < 0.01$ ), ALP by 33.6% ( $p < 0.01$ ) and TBR by 54.5% ( $p < 0.01$ ), as compared to paracetamol group. However, the reduction of liver enzymes and total bilirubin after administration of extract was comparable to the silymarin. Current study demonstrated potential hepatoprotective activity of *n*-hexane extract of *Morus nigra*.

**Keywords:** Moraceae. HPLC. Quercetin. *Morus nigra*/antioxidant. *Morus nigra*/extract/hepatoprotective.

## INTRODUCTION

Conventional drug therapy for liver ailments poses less efficacy and life-threatening adverse events. On the other hand, the use of traditional or herbal remedies portends less adverse outcomes with significant benefits (Bachar, Mahmud, Qais, 2012). Therefore, it is imperative to screen complementary and alternative medicine (CAM), particularly herbal drugs, for the treatment of liver diseases in order to get more efficacious and safer agents (Mallhi *et al.*, 2014a; 2014c). The beneficial effects of plants in several diseases could be attributed to the presence of phytochemicals (biologically active and non-essential chemical compounds). The phytochemicals modulate physiological functions and biotransformation reactions

involved in the detoxification process, thus providing protection against cytotoxic, genotoxic, and metabolic actions of environmental toxicants (Saha, Das, 2003).

*Morus nigra* L. (Moraceae), commonly known as black Mulberry (English) and Shah-toot (Hindi/Urdu), is widely distributed around the globe (Mallhi *et al.*, 2014b). Previous investigations have documented several activities of *M. nigra* including antioxidant, anti-nociceptive, anti-inflammatory, anti-diabetic, antibacterial, cardiac depressant, vermifuge, anticancer, and maternal health (Hasani-Ranjbar, Larijani, Abdollahi, 2009). Moreover, the traditional use of *Morus nigra* in jaundice has been well documented in the literature (Abbasi *et al.*, 2009). This hepatoprotective potential of *Morus nigra* can be explained by the presence of potential phytoconstituents including flavonoids, alkaloids, phenols (Malik *et al.*, 2012; Özgen, Serçe, Kaya, 2009) quercetin, luteolin, and isorhamnetin (Mallhi *et al.*, 2014b). Recent investigations have demonstrated promising hepatoprotective activity

\*Correspondence: T. H. Mallhi. Department of Pharmacy Practice, Faculty of Pharmaceutical Sciences, Government College University Faisalabad, Faisalabad, Pakistan. E-mail: tauqeer.hussain.mallhi@hotmail.com

of aqueous methanolic and ethanolic extracts of *Morus nigra* (Tag, 2015; Mallhi *et al.*, 2014b). However, a role of *n*-hexane extract in liver protection has not been evaluated yet. In this continuity, current study was aimed to determine the hepatoprotective activity of *n*-hexane extract of leaves of *Morus nigra* (NHMN) in paracetamol (PCM) intoxicated mice liver.

## MATERIALS AND METHODS

### Collection of plant

The leaves of *Morus nigra* were collected in April-May 2012 from Allied Hospital Faisalabad, University of Agriculture University Faisalabad, local Nursery farms in Faisalabad, Pakistan. The plant was identified by Dr. Mansoor Hameed, Associate Professor at Department of Botany, University of Agriculture Faisalabad, Pakistan and kept in department herbarium for reference (AUF-PI/2012/MN3).

### Preparation of plant extract

Leaves of the plant were washed and dried, and were finally grounded to the powder form (3.2 kg) by using

commercial grinder. The powder was soaked in *n*-hexane (8 L) for 7-10 days with occasional shaking. Muslin cloth was served to filter the solution and marc was pressed to get all filtrate. Rotary evaporator (70 °C) was used to evaporate filtrate that resulted in a jelly like paste (dark brown color). The paste was stored in amber colored glass bottle at room temperature.

### Phytochemical screening

The preliminary phytochemical screening was performed by using methods as described by Farhan *et al.* (2012) (Table I).

### Determination of phytoconstituents by HPLC analysis

Active constituents of the *n*-hexan extract of *Morus nigra* leaves were qualitatively determined by using isocratic HPLC. A small amount of extract was added in distilled water (5 mL). After adding methanol (12 mL), the mixture was kept for 5 minutes. Subsequently, 6 mL distilled water was added to the mixture and kept for more 5 minutes. After adding 10 mL of 15 M HCl, the mixture was placed in an oven for 2 hours. Syringe filter

**TABLE I** - Protocols for phytochemical screening of *n*-hexan extract of the leaves of *Morus nigra*

Detection	Procedure	Observation
<b>Tannins</b>	Ferric chloride reagent (FeCl <sub>3</sub> ) 1% drops were added to 10 mL of the extract	Appearance Blue color
<b>Resins</b>	20 mL HCl 4% were added in 10 mL of extract	Turbidity
<b>Coumarins</b>	5 mL of extract in a test tube was covered by a filter paper saturated in NaOH and was putted in water bath, boiled for 10 min. The filter paper was taken and exposed to UV light	Appearance green bright yellow color
<b>Saponins</b>	Extract in test tube was shaken for 5 min using a vortex	Appearance of big foamy
<b>Alkaloids</b>	0.2 g powder of the plant was dissolved in 10 mL of HCl 1% and they were transferred to a water bath for few minutes. 1 mL of the filtrated extract was treated with 2-4 drops of Dragendorff's reagent	Orange reddish precipitation
<b>Phenols</b>	In beakers, 5 mL of each extract was taken and 1 mL of FeCl <sub>3</sub> 1% and 1 mL of K <sub>3</sub> (Fe(CN) <sub>6</sub> ) 1% were added	Fresh radish blue color
<b>Terpenoids</b>	1 mL of acetic anhydride and 2 mL of concentrated sulphuric acid were added to beakers containing 1 mL of extract	Reddish brown on the interface
<b>Volatile Oils</b>	10 mL of extract was filtered by filter paper till saturation and then exposed for UV light	Appearance of a bright pinkish color
<b>Flavonoids</b>	Two solutions A and B from plant extract were prepared. The solution A contains 5 mL of ethanolic extract. The solution B consists of 5 mL of ethanolic solvent added to 5 mL of KOH 50%. Then the two solutions A and B were mixed together.	Appearance of yellow color

was used for filtration of final solution. Phenolics were separated using a shim-pack CLC-ODS (C-18) column, 25 cm × 4.6 mm, 5 µm. The mobile phase used was an isocratic (ACN:Dichloromethane:Methanol - 60:20:20) that was run at a flow rate of 1 mL/min. Samples were analyzed using UV-Visible detector at 280 nm at room temperature while kaempferol was detected at 248 nm wavelength. Methanol solution was used to wash the HPLC system for about one hour before use. Retention times (RT) were compared with standards in order to identify flavonoid contents in the extract (Sultana *et al.*, 2008).

## Animals

Twenty-five Swiss albino mice of the both sex, weighing about 22-35 g were kept in the departmental animal house. The mice were housed in standard laboratory conditions at a temperature of 25 ± 2 °C, relative humidity (50-55%) and a 12 h light/dark cycle (five mice per cage). The acclimatization period was of ten days (Iwalokun *et al.*, 2006). All the animals fed standardized nutritionally balanced diet and drinking water *ad libitum*. All the experiments were carried out in accordance with the European Community guidelines (EEC Directive of 1986; 86/609/EEC). The plan of the study was specifically approved by the institutional animal research committee (Reference: ARC/GCUF/2013/11M).

## Experimental protocol

All the animals were divided into five groups with five mice per group.

1. Group I served as normal control receiving distilled water only, for seven days
2. Group II (paracetamol control) received paracetamol p.o. 250 mg/kg/day for 7 days
3. Group III (silymarin control) had daily administration of silymarin 50 mg/kg (reference drug) for 7 days with subsequent administration of paracetamol 3 h after silymarin
4. Group IV received *n*-hexane extract of *Morus nigra* (NHMN) at doses 250 mg/kg p.o. for 7 days and received paracetamol 250 mg/kg 3 h after the extract dose.
5. Group V was injected with NHMN at doses 500 mg/kg p.o. for 7 days and received paracetamol (250 mg/kg) 3 h after extract dose (Mallhi *et al.*, 2014b).

At the end of experiment, mice were fasted for 12 h

and anesthetized with light chloroform. Animals were sacrificed through cervical decapitation on the 8th day (at the same time of last dose). Eppendorf tubes were used to collect blood samples. Serum was separated by centrifugation (7000 rpm for 15 min at 4 °C). A substantial elevation of liver transaminases and total bilirubin (TBR) was considered as hepatotoxicity throughout the experiment (Mallhi *et al.*, 2014b).

## Biochemical Investigation

Serum level of total bilirubin was determined by using the technique as described by Ehrlich (1883). Reitman and Frankel's methods were used to determine the concentration of ALT and AST in serum (Reitman, Frankel, 1957) while values of ALP were determined by using Kind and King's method (1954).

## Histopathological studies

All mice were dissected and livers were kept in saline. A piece of liver was washed in sterile saline and fixed in 10% buffered formalin (4% formaldehyde in phosphate buffer solution) for histopathological investigations. The dyes used for histopathological examinations were hematoxylin (acidic dye) and eosin (basic dye) for nuclei and cytoplasm staining into blue/purple and pink respectively. The histopathological scoring system used in current study was recommended by the Pathology Committee of NASH Clinical Research Network (Kleiner *et al.*, 2005). Steatosis, normal (<5%) = 0, 5-33% = 1, 33-66% = 2, >66% = 3, Microvesicular steatosis, none = 0, present = 1, Inflammation, none = 0, <2 foci per 200× field = 1, 2-4 foci per 200× field = 2, >4 foci per 200× field = 3, Ballooning, none = 0, few balloon cells = 1, many cells = 2, prominent balloon cells = 3, the overall results represented as follows 0 = normal, 1 = mild, 2 = moderate and 3 = severe.

## Statistical Analysis

Results were presented as Mean ± standard error (SE). All the continuous data were subjected to Student *t*-test by using SPSS version 17.0 (SPSS Inc., Chicago, IL, USA). *P* values were calculated by comparing group III (silymarin), group IV (NHMN 250 mg/kg) and group V (NHMN 500 mg/kg) with group III (PCM) (Table III). Treatment groups (NHMN) were also compared with silymarin group and respective *p* values are mentioned in text where comparison was stated. *P* values at ≤0.05 were considered as statistically significant.

## RESULTS

Phytochemical screening of *n*-hexane extract of *Morus nigra* leaves revealed the presence of phenols, flavonoids, alkaloids and terpenoids. Flavonoids were moderately present, while small fractions of phenols, alkaloids and terpenoids were also found as shown in Table II.

The HPLC chromatogram was compared with the standard retention times (RT) that showed the presence of quercetin (2.577 min), oleanolic acid (5.213 min), luteolin (8.431 min), apigenin (13.843 min), vitamin C (24.131 min) and kuwanon C (29.453 min) in the

**TABLE II** - Phytochemical screening of *n*-hexan extract of the leaves of *Morus nigra*

Active Compounds	<i>n</i> -Hexan extract of the leaves of <i>Morus nigra</i>
Phenols	+
Flavonoids	++
Saponins	-
Alkaloids	+
Resins	-
Tannins	-
Coumarines	-
Volatile Oils	-
Terpinoids	+

(+++) high amount after added of reagent immediately; (++) moderate amount after 5 min of reagent added; (+) low amount after 10 min of reagent added and (-) absent of active compound after 20 min

extract (Figure 1). HPLC analysis at the wavelength of 248 nm for the detection of kaempferol showed no peak, demonstrating the absence of kaempferol in the extract. Chemical structures of identified compounds are shown in Figure 2.

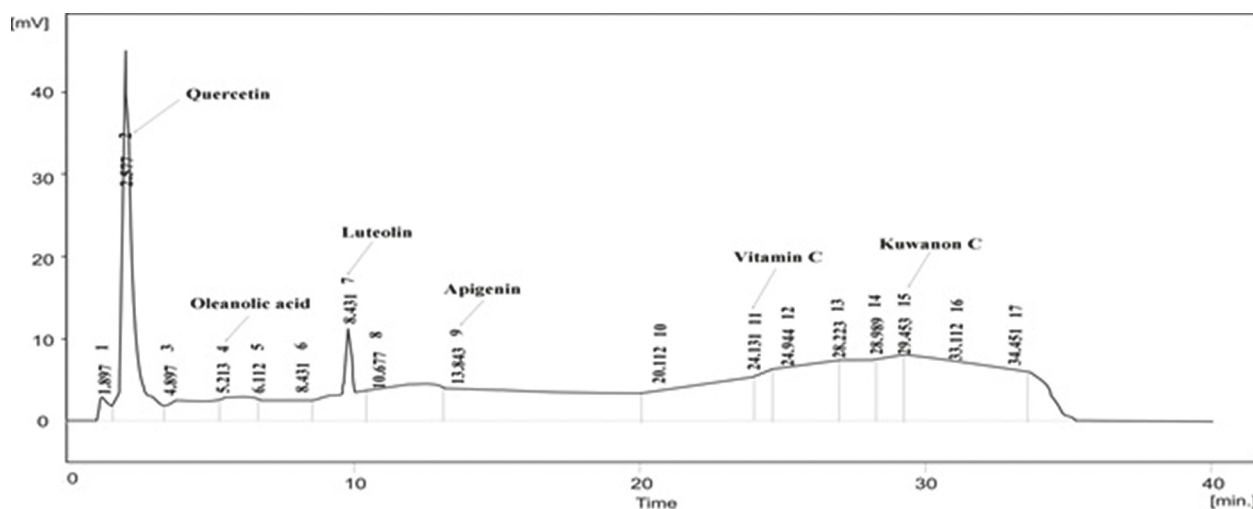
## Biochemical parameters

### Serum ALT activity

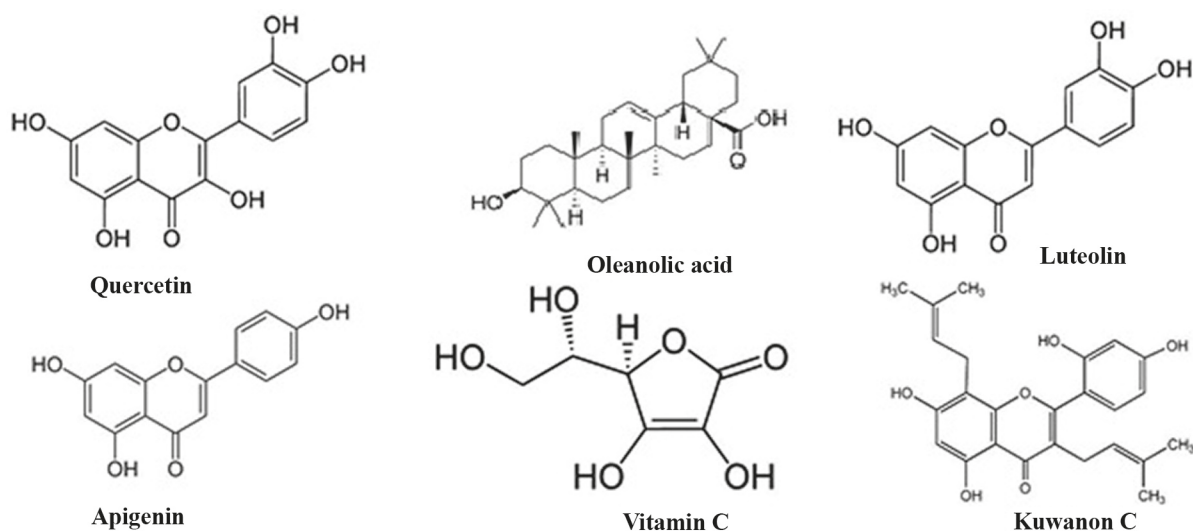
The mean value of ALT in paracetamol intoxicated mice was significantly ( $p < 0.001$ ) higher when compared to normal control receiving distilled water ( $112.1 \pm 4.18$  IU/L vs  $32.80 \pm 2.08$  IU/L respectively). Pretreatment with 250 and 500 mg/kg *n*-hexane extract of *Morus nigra* decreased the serum ALT concentration significantly and percentages of reduction were 54.3% and 62.9%, respectively. The reduction in serum ALT with NHMN was comparable to reduction caused by silymarin ( $p = 0.432$ ). Mean values of ALT in NHMN (250 mg/kg) and NHMN (500 mg/kg) were significantly differ ( $p < 0.001$ ) from normal and paracetamol controls (Table III).

### Serum AST activity

The mean value of AST was  $36.5 \pm 3.61$  IU/L in normal control that was significantly ( $p < 0.001$ ) lower than in the paracetamol control group ( $101.2 \pm 9.17$  IU/L). Treatment with NHMN prior to the paracetamol administration reduced mean levels of AST to  $45.40 \pm 7.13$  IU/L and  $43.8 \pm 6.61$  IU/L with doses of 250 and 500 mg/kg of NHMN respectively. These reduced values are comparable to that of silymarin control ( $39.80 \pm 7.80$  IU/L,  $P = 0.189$ ). Percentage reduction in mean levels of AST was 55.1% and 56.7% with 250 and 500 mg/kg of extract dose,



**FIGURE 1** - HPLC chromatogram of *n*-hexane extract of *Morus nigra* showing presence of quercetin, oleanolic acid, luteolin, apigenin, vitamin C and kuwanon C at 280 nm wavelength.



**FIGURE 2** - Chemical structure of identified compounds in *n*-hexane extract of leaves of *Morus nigra*.

respectively. A significant difference ( $p < 0.01$ ) was observed in mean values of serum AST in NHMN groups when compared with paracetamol control (Table III).

#### Serum ALP activity

Similarly mean values of ALP were significantly higher ( $413.40 \pm 21.76$  IU/L) in the paracetamol intoxicated group as compared to normal control ( $p < 0.01$ ). The groups treated with NHMN 250 mg/kg and 500 mg/kg significantly ( $p < 0.01$ ) reduced mean serum ALP levels by 28.5% and 33.6% as compared to PCM group and this reduction was comparable with silymarin ( $p = 0.221$ ) control as shown in Table III.

#### Total bilirubin

Paracetamol intoxication caused significant ( $p < 0.05$ ) elevation in total bilirubin concentration ( $2.01 \pm 0.22$  g/dL) as compared to normal control ( $0.89 \pm 0.03$  g/dL). While the administration of 250 mg/kg and 500 mg/kg NHMN subjected to significant reduction ( $p < 0.01$ ) in TBR count by 56.4% and 54.5% respectively when compared to

paracetamol control. The reduction caused by NHMN was comparable ( $p = 0.512$ ) to reduction caused by silymarin (55.1%) (Table III).

#### Histopathology

The biochemical investigations were confirmed by histopathological examinations as shown in Figure 3. The group I receiving distilled water showed normal liver architecture and healthy hepatocytes (histology score = 0 for all domains). Paracetamol administration caused inflammation (score = 3), microvesicular steatosis (score = 1), necrosis, ballooning (score = 3) and sinusoidal constriction of hepatocytes while treatment with silymarin and NHMN provided improvement in inflammation and necrosis accompanied by sinusoidal dilatation. Examination of mice liver treated with silymarin showed to great extent improved sections represented by healthy hepatocytes and nucleated cells. Histology scoring system showed mild steatosis (score = 1), negative to microvesicular steatosis, mild inflammation (score = 1)

**TABLE III** - Effect of *n*-hexane extract of *Morus nigra* (NHMN) on liver enzymes and total bilirubin

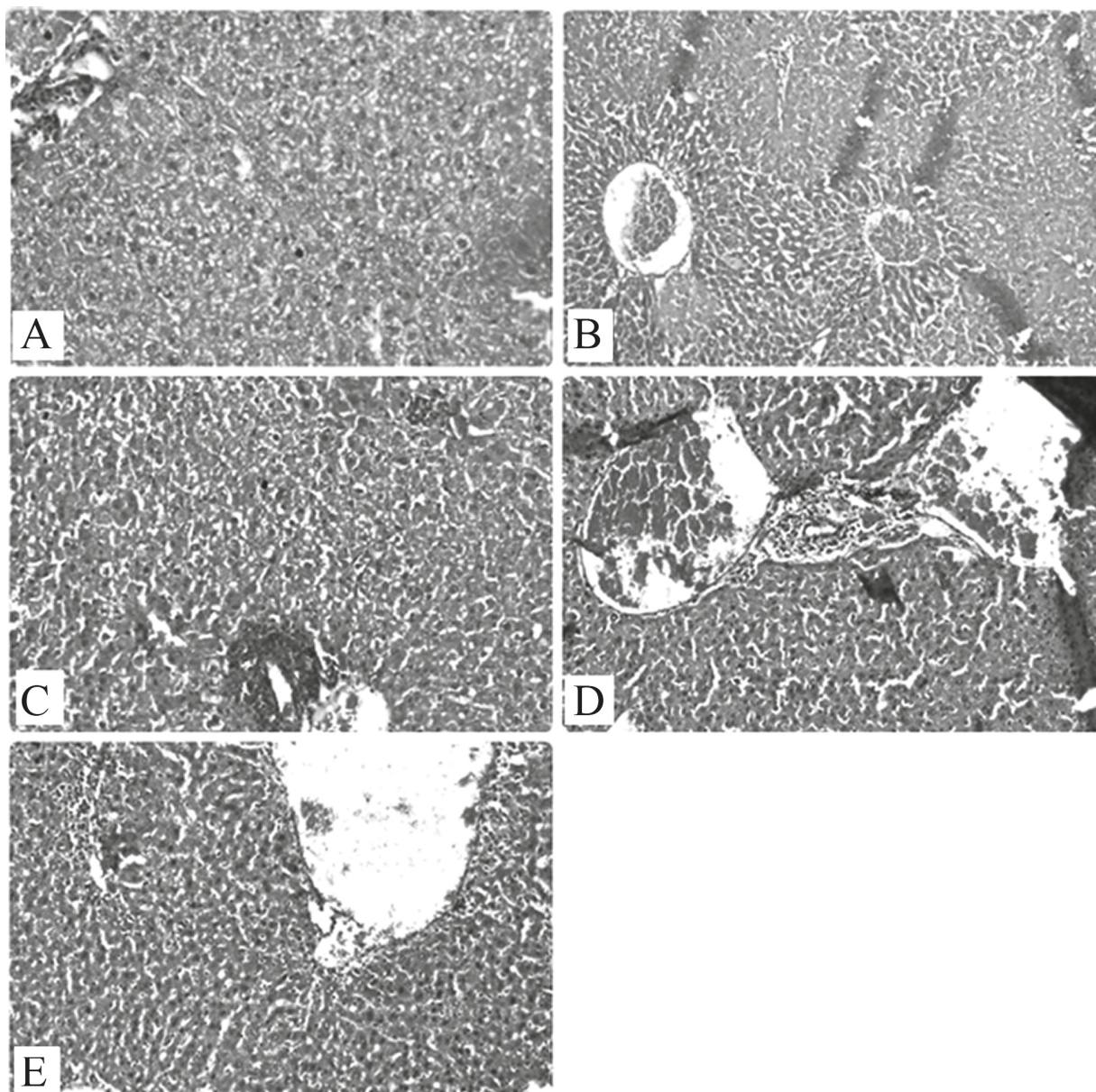
Parameters	ALT (IU/L)	AST (IU/L)	ALP (IU/L)	TBR (g/dL)
Normal Control (D/W)	$32.80 \pm 2.08$	$36.50 \pm 3.61$	$216.20 \pm 9.95$	$0.89 \pm 0.04$
PCM Control (250 mg/kg)	$112.10 \pm 4.17$	$101.20 \pm 9.17$	$413.40 \pm 21.70$	$2.01 \pm 0.22$
Silymarin (50 mg/kg) + PCM	$41.60 \pm 3.09^{**}$	$39.80 \pm 7.80^{**}$	$266.40 \pm 32.69^*$	$0.91 \pm 0.11^*$
NHMN (250 mg/kg) + PCM	$51.2 \pm 8.29^{**}$	$45.40 \pm 7.13^*$	$295.60 \pm 25.61^*$	$0.88 \pm 0.05^*$
NHMN (500 mg/kg) + PCM	$46.60 \pm 6.20^{**}$	$43.8 \pm 6.33^*$	$274.60 \pm 22.32^*$	$0.92 \pm 0.03^*$

Results are presented as Mean  $\pm$  SE and compared with Student t test. p values are served as statistically significant difference when compared to PCM control. \* $p < 0.01$ , \*\* $p < 0.001$

and no balloon cells (score = 0). Histopathological improvements of hepatocytes with NHMN were comparable with silymarin as represented by histology score: inflammation (score = 2), microvesicular steatosis (score = 1) and few balloon cells (score = 1) with 250 mg/kg extract dose; inflammation (score = 1), microvesicular steatosis (score = 0) and few balloons cells (score = 1) with 500 mg/kg extract dose.

## DISCUSSION

Paracetamol (PCM) overdose can result in hepatic damage due to accumulation *N*-acetyl-*p*-benzoquinoneimine (NAPQI), which is one of the metabolites of PCM. NAPQI is normally conjugated with glutathione (GSH) and leads to the oxidation and conversion of GSH to glutathione disulfide (GSSG)



**FIGURE 3** - Histopathological examination of study groups treated with [A] distilled water – normal liver architecture and healthy hepatocytes [B] paracetamol – inflammation (score = 3), microvesicular steatosis (score = 1), necrosis, ballooning (score = 3) and sinusoidal constriction of hepatocytes [C] silymarin – improved inflammation, ballooning and necrosis of hepatocytes as mild steatosis (score = 1), negative to microvesicular steatosis, mild inflammation (score = 1) and no balloon cells (score = 0) [D] NHMN 250 mg/kg – inflammation (score = 2), microvesicular steatosis (score = 1) and few balloon cells (score = 1) [E] NHMN 500 mg/kg – inflammation (score = 1), microvesicular steatosis (score = 0) and few balloons cells (score = 1). Scores are referred to histology scores recommended by Pathology Committee of NASH Clinical Research Network.

resulting in the reduced levels of GSH in blood and liver. Depletion of GSH can result in mitochondrial dysfunction, an increase of lipid peroxidation, and development of acute hepatic necrosis. Hepatocellular necrosis releases enzymes such as AST and ALT into the circulation that can be measured in the serum as a sign of liver injury (Yahya *et al.*, 2013).

*Morus nigra* is a popular and widely distributed species of the Moraceae family that has been included in Modern Chinese Materia Medica due to its long history of medicinal use (Xiao *et al.*, 2002). Traditionally, *Morus nigra* has been used as a medicinal agent to nourish the yin and blood, benefit the kidneys, and treat weakness, fatigue, anemia, and premature graying of hairs. It is also utilized to treat urinary incontinence, tinnitus, dizziness, and constipation in the elderly and the anemic (Xiao *et al.*, 2002). In current study, hepatoprotective activity of leaves of *Morus nigra* was evaluated by using mice as experimental model. *Morus nigra* n-Hexane extract with 250 mg/kg reduced elevated ALT by 54.3% ( $p < 0.001$ ), AST by 55.1% ( $p < 0.01$ ), ALP by 28.5% ( $p < 0.01$ ) and TBR by 56.4% ( $p < 0.01$ ) as compared to paracetamol control. The dose of 500 mg/kg reduced mean values of ALT by 62.9% ( $p < 0.001$ ), AST by 56.7% ( $p < 0.01$ ), ALP by 33.6% ( $p < 0.01$ ) and TBR by 54.5% ( $p < 0.01$ ) as compared to paracetamol control in present study. The reduction of mean values of liver enzymes and total bilirubin was comparable ( $p > 0.05$ ) with silymarin in the current study. A high dose (500 mg/kg) of NHMN demonstrated a better reduction of liver enzymes and total bilirubin as compared to low dose (250 mg/kg) but the difference was statistically insignificant ( $p > 0.05$ ). Similarly, histopathological improvements were more profound with 500 mg/kg and these improvements were also comparable to silymarin. Improvement in histology score was also observed with extract doses and was comparable to silymarin.

The hepatoprotective activity of *Morus nigra* could be attributed to the presence of chemical compounds that are biologically active. Phytochemical screening demonstrated that plant contains hepatoprotective phenols, flavonoids, alkaloids and terpenoids (Fernando, Soysa, 2014). Qualitative analysis by isocratic flow HPLC showed the presence of six phytoconstituents in n-hexane extract of leaves of *Morus nigra* and these findings are consistent with previous investigations (Wang, Wang, Chen, 2007). Quercetin (Janbaz, Saeed, Gilani, 2004), oleanolic acid (Chen *et al.*, 2005), luteolin (Domitrović *et al.*, 2009), apigenin (Zheng *et al.*, 2005; Mallhi *et al.*, 2014c) and vitamin C (Uboh *et al.*, 2012); all are well known to possess liver protective potential and desired pharmacological activity in our study might be attributed

to the presence of these compounds in *Morus nigra* n-hexane extract. Kuwanon C in our extract is also present in closely related species, *Morus alba* (Family: Moraceae) and has been found to possess antimicrobial activity against several bacteria and molds (Butt *et al.*, 2008).

The possible mechanism of action by which n-hexane extract of *Morus nigra* provided hepato-protection might be related to the free radical scavenger and antioxidant activities of the identified compounds (Saeed, Khan, Shabbir, 2012). A number of reactive oxygen species (ROS) like singlet oxygen ( $^1O_2$ ), superoxide anion radical ( $O_2^-$ ), hydroxyl radical ( $OH^\cdot$ ), nitric oxide radical ( $NO^\cdot$ ), and alkyl peroxy ( $ROO^\cdot$ ) are produced regularly in the human body as a result of oxidation processes. Protective mechanisms exist to mediate their harmful effects but sometimes ROS overrides the defense capabilities of the body resulting in oxidative damage to molecules and membranes, as happened in PCM group. In such cases, there is a need to strengthen this mechanism by antioxidant supplementation (Butt *et al.*, 2012). *Morus nigra* is important in respect to antioxidant compounds and quercetin is most important for antioxidant potential of mulberry plant. It has been previously reported that leaves of mulberry contain higher amount of quercetin and support for possible application of mulberry leaves extract or functional components to reduce *in vivo* and *in vitro* oxidation process (Chen, Li, 2007; Enkhmaa *et al.*, 2005; Katsube *et al.*, 2006). In addition, fruits of *Morus alba* have also been reported to possess antioxidant activity (Ercisli, Orhan, 2007) that appeals the need to investigate various parts of *Morus nigra* for its antioxidant and hepatoprotective potential. In present study, qualitative determination of active compounds of extract was carried out by using HPLC analysis. Comparison of chromatogram with retention times showed presence of some potential antioxidant compounds including quercetin, oleanolic acid, luteolin and apigenin. Quercetin by multiple mechanisms interplay, demonstrates hepatoprotective effect on liver injury, by increasing antioxidant system activities against oxidative stress and lowering the expressions of proinflammatory cytokines (Chen, 2010). Oleanolic acid (OLA) causes enhancement of glutathione regeneration capacity and reduction of lipid peroxidation. OLA has also been documented to possess dose dependent hepatoprotection (Bai *et al.*, 2007) and it might contribute to liver protective activity in present study. Extract of *Morus nigra* also showed presence of luteolin, a flavone type flavonoid. In presented study, PCM administration causes GSH depletion with an association of increased lipid peroxidation, which led to tissue injury and liver damage. Presence of luteolin in plant

extract results in reversal of these changes and elevation of GSH levels. Furthermore, luteolin also inhibits lipid peroxidation, emphasizing its antioxidant effect (Bigoniya, 2013). Hepatoprotection of NHMN might be attributed to these mechanisms of luteolin. Furthermore, due to apigenin-related anti-inflammatory and antioxidant properties, NHMN could counteract the pro-oxidant effect of PCM or NAQPI through scavenging superoxide radicals, consequently declining hepatic glutathione-S-transferase (GST) and decreasing release of  $\gamma$ -glutamyl transpeptidase in serum (Asadi-Samani *et al.*, 2015); as a result, NHMN could be assumed as a potent plant against experimentally induced hepatocarcinogenesis in mice. All these mechanisms might contribute to the hepatoprotective activity of *n*-hexane extract of *Morus nigra* in present study and phytoconstituents with antioxidant activities enhance the chances of *Morus nigra* extract supplementation, especially in liver ailments. However, future studies are required to investigate the pharmacological activities of these compounds

## CONCLUSIONS

The results obtained from current study indicate the presence of antioxidant compounds, i.e. quercetin, oleanolic acid, luteolin, apigenin and ascorbic acid and their potential hepatoprotective activity against paracetamol induced liver injury in mice.

## REFERENCES

- Abbasi AM, Khan MA, Ahmad M, Zafar M, Khan H, Muhammad N, Sultana S. Medicinal plants used for the treatment of jaundice and hepatitis based on socio-economic documentation. *Afr J Biotechnol.* 2009;8(8):1643-50.
- Asadi-Samani M, Kafash-Farkhad N, Azimi N, Fasihi A, Alinia-Ahandani E, Rafieian-Kopaei M. Medicinal plants with hepatoprotective activity in Iranian folk medicine. *Asian Pac J Trop Biomed.* 2015;5(2):146-57.
- Bachar SC, Mahmud ZA, Qais N. Antioxidant and hepatoprotective activities of ethanolic extracts of leaves of *Premna esculenta* Roxb. against carbon tetrachloride-induced liver damage in rats. *J Young Pharma.* 2012;4(4):228-234.
- Bai XP, Qiu AY, Guan JJ, Shi ZP. Antioxidant and protective effect of an oleanolic acid-enriched extract of *A. deliciosa* root on carbon tetrachloride induced rat liver injury. *Asia Pac J Clin Nutr.* 2007;16(Suppl 1):169-73.
- Bigoniya P, Singh CS. Hepatoprotective activity of luteolin from *A. millefolium* in CCl<sub>4</sub> intoxicated rat model. *Intern J Indig Med Plants.* 2013;46(4):2051-4263.
- Butt MS, Nazir A, Sultan MT, Schroën K. *Morus alba* L. nature's functional tonic. *Trends Food Sci Technol.* 2008;19(10):505-512.
- Chen J, Li X. Hypolipidemic effect of flavonoids from mulberry leaves in triton WR-1339 induced hyperlipidemic mice. *Asia Pac J Clin Nutr.* 2007;16(Suppl 1):290-294.
- Chen X. Protective effects of quercetin on liver injury induced by ethanol. *Pharmacogn Mag.* 2010;6(22):135-141.
- Chen Y, Liu J, Yang X, Zhao X, Xu H. Oleanolic acid nanosuspensions: preparation, in-vitro characterization and enhanced hepatoprotective effect. *J Pharm Pharmacol.* 2005;57(2):259-264.
- Domitrović R, Jakovac H, Milin Č, Radošević-Stašić B. Dose- and time-dependent effects of luteolin on carbon tetrachloride-induced hepatotoxicity in mice. *Exp Toxicol Pathol.* 2009;61(6):581-89.
- Ehrlich P. Sulfodiazobenzol, ein Reagens auf Bilirubin. *Centralbl F Win Med.* 1883;4:721.
- Enkhmaa B, Shiwaku K, Katsube T, Kitajima K, Anuurad E, Yamasaki M, Yamane Y. Mulberry (*Morus alba* L.) leaves and their major flavonol quercetin 3-(6-malonylglucoside) attenuate atherosclerotic lesion development in LDL receptor-deficient mice. *J Nutri.* 2005;135(4):729-734.
- Ercisli S, Orhan E. Chemical composition of white (*Morus alba*), red (*Morus rubra*) and black (*Morus nigra*) mulberry fruits. *Food Chem.* 2007;103(4):1380-1384.
- Farhan H, Rammal H, Hijazi A, Badran B. Preliminary phytochemical screening and extraction of polyphenol from stems and leaves of a Lebanese plant *Malva parviflora* L. *Int J Curr Pharm Res.* 2012;4:55-59.
- Fernando CD, Soysa P. Total phenolic, flavonoid contents, in-vitro antioxidant activities and hepatoprotective effect of aqueous leaf extract of *Atalantia ceylanica*. *BMC Compl Altern Med.* 2014;14:395.
- Hasani-Ranjbar S, Larijani B, Abdollahi M. A systematic review of the potential herbal sources of future drugs effective in oxidant-related diseases. *Inflam Allergy-Drug Targets.* 2009;8(1):2-10.



- Iwalokun BA, Efedede BU, Alabi-Sofunde JA, Oduala T, Magbagbeola OA, Akinwande AI. Hepatoprotective and antioxidant activities of *Vernonia amygdalina* on acetaminophen-induced hepatic damage in mice. *J Med Food*. 2006;9(4):524-30.
- Janbaz KH, Saeed SA, Gilani AH. Studies on the protective effects of caffeic acid and quercetin on chemical-induced hepatotoxicity in rodents. *Phytomed*. 2004;11(5):424-30.
- Katsube T, Imawaka N, Kawano Y, Yamazaki Y, Shiwaku K, Yamane Y. Antioxidant flavonol glycosides in mulberry (*Morus alba* L.) leaves isolated based on LDL antioxidant activity. *Food Chem*. 2006;97(1):25-31.
- Kind PRN, King EJ. Elimination of plasma phosphate by determination of hydrolysed phenol with aminoantipyrine *J Clin Pathol*. 1954;7(4):322-326.
- Kleiner DE, Brunt EM, Van Natta M, Behling C, Contos MJ, Cummings OW, et al. Design and validation of a histological scoring system for nonalcoholic fatty liver disease. *Hepatology*. 2005;41(6):1313-21.
- Malik MNH, Alamgeer US, Qayyum A, Samreen S. Phytochemical analysis and cardiac depressant activity of aqueous methanolic extract of *Morus nigra* L. fruit. *J Appl Pharm Sci*. 2012;2(12):39-41.
- Mallhi TH, Abbas K, Ali M, Qadir M I, Saleem M, Khan YH. Hepatoprotective activity of methanolic extract of *Malva parviflora* against paracetamol-induced hepatotoxicity in mice. *Bangl J Pharmacol*. 2014c;9(3):342-346.
- Mallhi TH, Qadir MI, Ali M, Ahmad B, Khan YH, Rehman A. Ajwa Date (*Phoenix dactylifera*) - An emerging plant in pharmacological research. *Pak J Pharm Sci*. 2014a;27(3):607-616.
- Mallhi TH, Qadir MI, Khan YH, Ali M. Hepatoprotective activity of aqueous methanolic extract of *Morus nigra* against paracetamol-induced hepatotoxicity in mice. *Bangl J Pharmacol*. 2014b;9(1):60-66.
- Özgen M, Serçe S, Kaya C. Phytochemical and antioxidant properties of anthocyanin-rich *Morus nigra* and *Morus rubra* fruits. *Sci Hort*. 2009;119(3):275-279.
- Reitman S, Frankel S. A colorimetric method for the determination of Serum glutamate pyruvate transaminase and serum glutamate oxaloacetate transaminase. *Am J Clin Pathol*. 1957;28(1):56-62.
- Saeed N, Khan MR, Shabbir M. Antioxidant activity, total phenolic and total flavonoid contents of whole plant extracts *Torilis leptophylla* L. *BMC Compl Altern Med*. 2012;12:221.
- Saha P, Das S. Regulation of hazardous exposure by protective exposure: modulation of phase II detoxification and lipid peroxidation by *Camellia sinensis* and *Swertia chirata*. *Teratog Carcinog Mutagen*. 2003;23(S1):313-322.
- Sultana B, Anwar F, Rafique AM, Chatha SAH. Antioxidant potential of extracts from different agro wastes: Stabilization of corn oil. *Grasas Aceites*. 2008;59(3):205-217.
- Tag HM. Hepatoprotective effect of mulberry (*Morus nigra*) leaves extract against methotrexate induced hepatotoxicity in male albino rat. *BMC complementary and alternative medicine*. 2015;15(1):252.
- Uboh FE, Ebong PE, Akpan HD, Usuh IF. Hepatoprotective effect of vitamins C and E against gasoline vapor-induced liver injury in male rats. *Turk J Biol*. 2012;36:217-223.
- Wang L, Wang HQ, Chen RY. Studies on chemical constituents from bark of *Morus nigra*. *China J Chin Materia Med*. 2007;32(23):2497-2499.
- Xiao PG, Li DP, Yang SL. *Modern Chinese materia medica*. Chem Industry Press; 2002, p. 253-272.
- Yahya F, Mamat SS, Kamarolzaman MFF, Seyedan AA, Jakius KF, Mahmood ND, Zakaria, ZA. Hepatoprotective activity of methanolic extract of *Bauhinia purpurea* leaves against paracetamol-induced hepatic damage in rats. *Evid Based Complement. Altern Med*. 2013;2013:636580.
- Zheng QS, Sun XL, Xu B, Li G, Song M. Mechanisms of apigenin-7-glucoside as a hepatoprotective agent. *Biomed Environ Sci*. 2005;18(1):65-70.

Received for publication on 06<sup>th</sup> February 2018

Accepted for publication on 19<sup>th</sup> April 2018